

The immunohistochemical localization of alpha₁-antichymotrypsin and fibronectin and its meaning for the determination of the vitality of human skin wounds

P. Betz¹, A. Nerlich², J. Wilske¹, J. Tübel¹, R. Penning¹, and W. Eisenmenger¹

Departments of ¹Legal Medicine and ²Pathology, University of Munich, Frauenlobststrasse 7a, W-8000 München 2, Germany

Received May 13, 1992 / Received in revised form August 20, 1992

Summary. A total of 39 vital human skin wounds (20 cases with short survival times ranging from a few seconds to approximately 30 min and 19 cases with wound ages between 50 min and 13 days) were investigated. Alpha₁-antichymotrypsin (A₁-ACT) was visualized by immunohistochemistry. Additionally, fibronectin was localized in 13 of these wounds (8 cases with short and 5 cases with longer survival times). Furthermore, 13 postmortem lesions (stab wounds) were removed from corpses approximately 4 h after infliction and analyzed for A₁-ACT and fibronectin. The "vital" reaction previously described for A₁-ACT in form of a band-shaped staining pattern at the wound edges was observed in both vital wounds and in most postmortem lesions. A similar reaction was also obtained for fibronectin in wounds inflicted after death, but could be unambiguously distinguished from vital fibronectin staining by morphological criteria. Therefore, it seems questionable that the vitality of skin wounds can be determined by the immunohistochemical detection of A₁-ACT and probably other proteinase inhibitors. The meaning of the localization of fibronectin for the determination of the vitality of human skin wounds with a survival time of at least a few minutes could be confirmed.

Key words: Alpha₁ – Antichymotrypsin – Fibronectin – Vital Reaction – Wound Age – Immunohistochemistry

Zusammenfassung. An 39 vitalen menschlichen Hautwunden (20 Fälle mit kurzer Überlebenszeit von wenigen Sekunden bis ca. 30 Minuten und 19 Fälle mit einem Wundalter zwischen 50 Minuten und 13 Tagen) wurde der Proteinase-Inhibitor Alpha₁-Antichymotrypsin (A₁-ACT) sowie an einem Teil dieser Hautwunden (8 Fälle

mit kurzer und 5 Fälle mit längerer Überlebenszeit) zusätzlich Fibronectin immunhistochemisch dargestellt. Desweiteren wurden an 13 Leichen postmortal Stichwunden gesetzt, diese nach ca. 4 Stunden entnommen und ebenfalls entsprechend gefärbt. Es zeigte sich, daß der in der Literatur als „vitale“ Reaktion bezeichnete saumartige Farbniederschlag bei Darstellung von A₁-ACT am Wundrand zwar stellenweise auch in vitalen Wunden, jedoch ebenso in den postmortal gesetzten Läsionen zu beobachten war. Eine entsprechende Anfärbung des Wundrandes wie auch anderer Randbereiche der Gewebeproben war ebenfalls für Fibronectin zu erhalten, aufgrund morphologischer Kriterien war diese, u.E. unspezifische Reaktion jedoch eindeutig von vitalen Fibronectin-Reaktionen zu unterscheiden. Eine Erfassung vitaler Reaktionen durch die Darstellung von A₁-ACT und wahrscheinlich auch anderer Proteinase-Inhibitoren erscheint nach unseren Untersuchungen sehr zweifelhaft. Die hohe Aussagekraft der immunhistochemischen Lokalisation von Fibronectin im Wundgebiet zur Erfassung vitaler Phänomene in Hautwunden mit einer Überlebenszeit von mindestens einigen Minuten konnte hingegen bestätigt werden.

Schlüsselwörter: Alpha₁ – Antichymotrypsin – Fibronectin – Vitale Reaktion – Wundalter – Immunhistochemie

Introduction

The question whether an injury is inflicted before or after death is one of the central problems in forensic medicine. There are a large number of studies dealing with the determination of vital signs in human skin wounds. These include reports on biochemical changes [1, 6, 7, 9, 11, 13, 15, 16, 25] and in particular on morphological phenomena as vital signs. Histochemical methods mainly applied by Raekallio [21, 22, 23] have been used, although

This study was supported by a grant from the "Deutsche Forschungsgemeinschaft" (grant No. Ei 209/3-1) and by a grant from the "Friedrich-Baur-Stiftung", University of Munich, Germany

Correspondence to: P. Betz

the results have been discussed controversially [for review see 24], as well as routine histological techniques. In short-term wounds the latter methods seem to be restricted to the detection of infiltrating granulocytes. But these cells first appear after survival times of at least 20–30 min and considerable variations have been reported by different authors [for review see 20]. The previously suggested “signs of vitality” such as bleeding and the development of fibrin clots in the wound area [4, 5, 27] have also been questioned [14, 26, 28] and the detection of hemostatic plugs in skin wounds after short survival times is also of very limited use [12]. Furthermore, it has been reported that information on wound vitality can be obtained by changes in the staining pattern of the basic connective tissue substances [17], but on the basis of routine histology this approach provided no valuable parameters for estimation of wound vitality.

The introduction of immunohistochemical techniques, however, seemed promising to enable the detection of vital signs also in wounds after short survival times. Oehmichen et al. [18, 19] described the early release of several proteinase inhibitors and interpreted their findings as an indicator of vitality during the early post-traumatic interval in human skin wounds. Fechner et al. [8] showed that the immunohistochemical localization of fibronectin was suitable for indicating vitality of skeletal muscle damage. The advantage of the detection of this glycoprotein as a vital sign in human skin wounds with a survival time of at least a few minutes was demonstrated by our own previous results [3].

The present study was performed to elucidate the role of the immunohistochemical localization of the proteinase inhibitor A_1 -ACT as compared with fibronectin, which has previously been shown to be a useful parameter for the determination of the vitality of human skin wounds.

Material and methods

A total of 39 vital and 13 postmortem skin wounds was investigated. In 20 out of the 39 vital wounds (lacerations, stab wounds) the survival time ranged between a few seconds and approximately 30 min. The remaining cases were characterized by wound ages of 50 min up to 13 days (surgical wounds). The postmortem interval did not exceed 3 days and the cadavers were refrigerated (4°C) within a few hours after death. The postmortem wounds (stab wounds on the thigh) were removed during autopsy 4 h after infliction. The specimens were prepared as previously described [3].

Sections were enzymatically pretreated and A_1 -ACT was visualized using a polyclonal antibody (Fa. Dako, Hamburg, Germany) according to the ABC-method [10]. Fibronectin was localized in serial sections from 13 of the vital skin wounds and in all postmortem lesions as previously described [3].

Results

A_1 -ACT

In all specimens investigated a positive reaction (“internal control”) was seen in mast cells, macrophages and in endothelial cells.

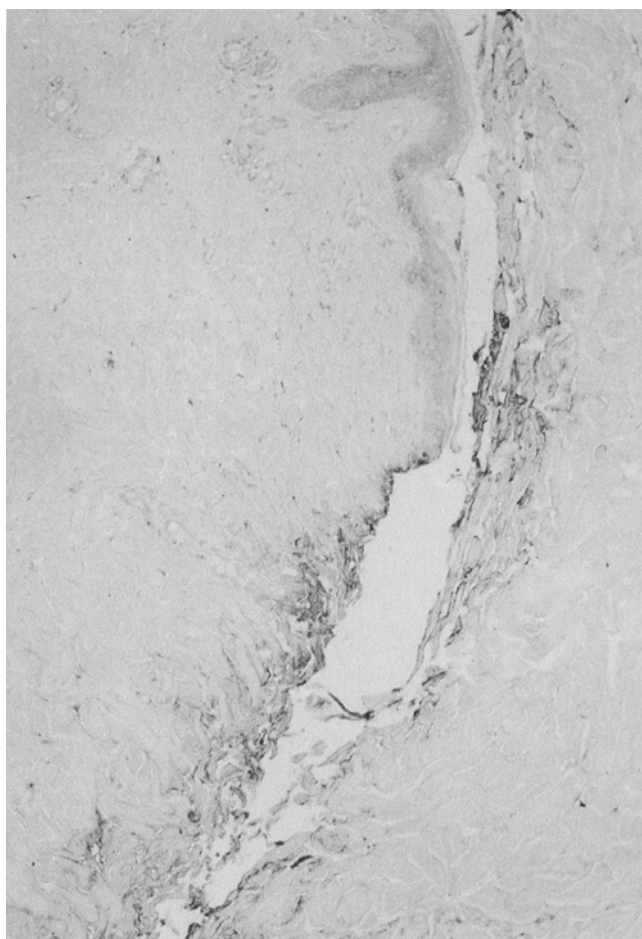


Fig. 1. 3-hour-old skin wound: “positive” reaction for α_1 -antichymotrypsin around the disconnected fiber bundles of the corium probably due to serum extravasation (paraffin, ABC-method, 240 \times)

In only 1 of the 20 cases (5%) with short survival times up to approximately 30 min could a band-shaped positive reaction at the wound edge be observed which was clearly distinguishable from the weak band-shaped staining patterns found at other margins of the specimens. In 3 cases (15%) a questionable “positive” reaction was found and the remaining 16 cases (80%) showed no distinct positive staining at the wound edges when compared to the other margins of the specimens.

In 5 out of 19 skin wounds (26%) with a wound age between 50 min and 13 days, a positive staining was seen at the wound margin and in 3 of these 5 “positive” cases the reaction was restricted only to the coagulated exudate which had developed on the epithelial layer. In only 1 of these 19 cases (survival time 3 h; Fig. 1) a distinct positive reaction was seen at the wound edges but not in other marginal regions of this specimen. In this case the positive staining was detectable around disconnected fiber bundles of the dermis, extending into inner areas of the specimen and was therefore not only restricted to a band localized at the wound edge. In 3 out of the 19 cases (16%) a questionable and in the remaining 11 skin wounds (58%) no staining pattern distinguishable from that of the other margins was demonstrable.

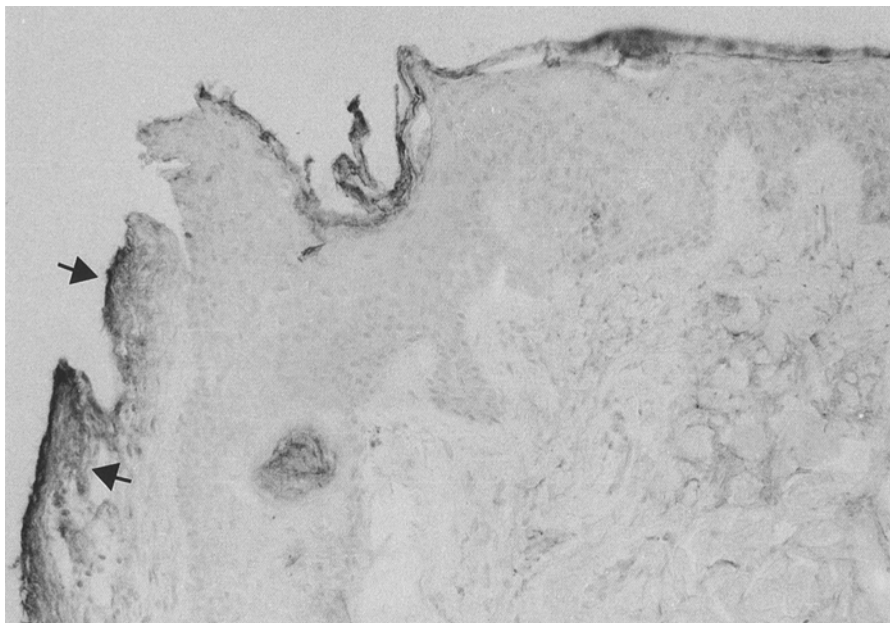


Fig. 2. Postmortem skin wound: band-shaped “positive” reaction for α_1 -antichymotrypsin (see arrows) (paraffin, ABC-method, 350 \times)

Furthermore, in some skin wounds a weak string- or spot-like staining for A_1 -ACT was detectable in areas of bleeding.

In 10 out of the 13 postmortem lesions (77%) a similar distinct band-shaped reaction was found at the “wound edge” (Fig. 2) and at some other marginal structures of the specimens (fat and muscle tissue, collagen fiber bundles of the dermis).

Fibronectin

A positive (“control”) staining for fibronectin was demonstrable in the basement membranes of the epithelial layer, skin appendages and especially of major blood vessels. The dermis showed a diffuse and rather homogenous weak staining pattern.

In 1 out of 8 skin wounds stained for both A_1 -ACT and fibronectin, a “positive” reaction for A_1 -ACT localized around the disconnected fiber bundles of the corium was found at the wound edge which was distinguishable from the band-shaped staining pattern of the other margins of the specimens (wound age 3 h; Fig. 1). However, in 6 of these cases, a distinct reaction for fibronectin in the form of strongly reacting strings with a beginning formation of network-like structures was demonstrable which indicates a vital reaction as previously described [3]. In some cases a band-shaped weak staining for fibronectin also occurred in marginal regions but this reaction was clearly distinguishable from vital fibronectin staining and only restricted to the outer areas of the margins.

A typical fibronectin reaction which could be regarded as vital was not found in the postmortem lesions. In most postmortem “wound edges”, however, a similar band-shaped staining pattern was seen for fibronectin to that found for A_1 -ACT (Fig. 3 and 4). On the basis of morphological evaluation, this staining pattern could be regarded as non-specific as previously shown [3].

Discussion

The immunohistochemical detection of proteinase inhibitors [18, 19] has been regarded as valuable for the determination of the vitality of human skin wounds with short survival times (up to a few minutes).

Oehmichen et al. [18, 19] described a band-shaped staining for proteinase inhibitors (α_1 -antichymotrypsin, α_1 -antitrypsin, α_2 -macroglobulin) parallel to the surface of disconnected collagen bundles of the wound margin which was interpreted as a “vital” sign. This was not observed in the epidermal layer, in fat or muscle tissue or in postmortem lesions. In that study “numerous cases with postmortem lesions, partly inflicted by the first-aid doctor (injection marks)” had been evaluated. The detection of the antigens in mast cells of the skin and the lack of the staining pattern at the margins of the specimens apart from the wound edge were regarded as an “internal control”. For evaluation of the “specificity” of the staining the purified proteinase inhibitor was added in different concentrations and led to the disappearance of the reaction at the wound edge and to a reduced reactivity of the mast cell granules. In this study, the proteinase inhibitors α_2 -macroglobulin and A_1 -ACT were detected in nearly all vital wounds, partly also in cases characterized by extremely short survival times (e.g. train accidents). No relevant differences in the extent of the reaction or in the staining intensity were found with regard to the survival time (maximal wound age investigated: 165 min), except for the wounds aged between 90 and 100 min which showed a reduced staining intensity when compared to the other groups. The positive staining at the wound edge was assumed to be the result of an immediate release of these proteins by skin mast cells.

However, the results of Oehmichen et al. could not be confirmed in our series. A “positive” reaction for A_1 -

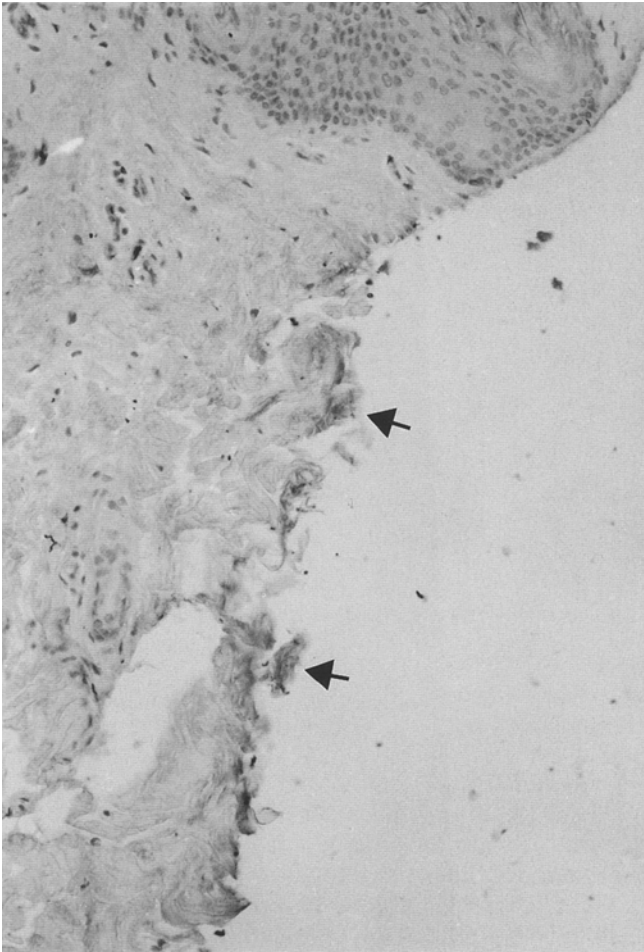


Fig. 3. Postmortem skin wound: band-shaped “positive” staining (see arrows) at the “wound margin” for A₁-ACT (paraffin, ABC-method, 480 ×)

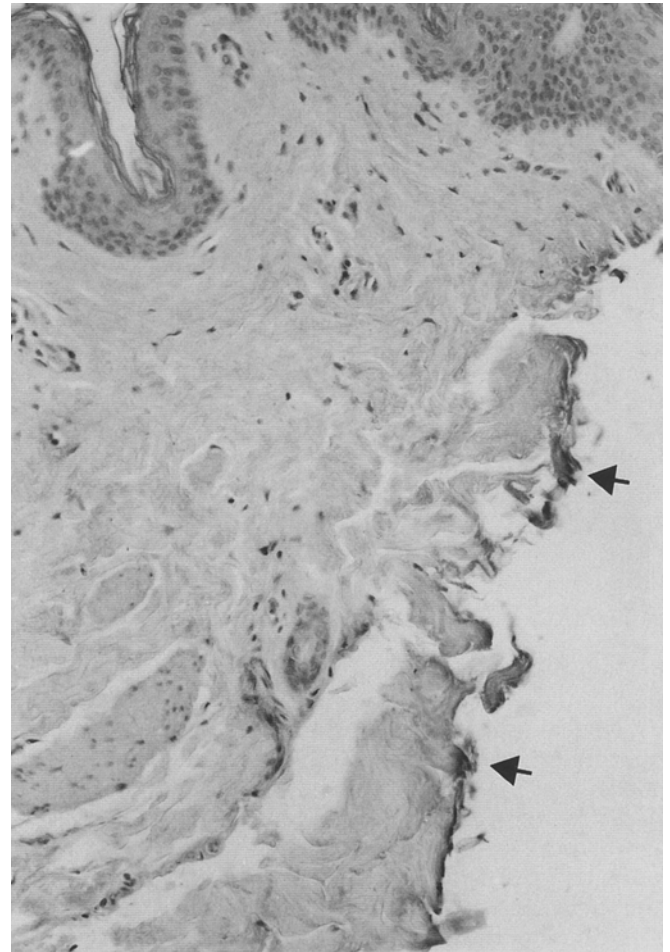


Fig. 4. Same postmortem wound as in Fig. 3: band-shaped staining pattern for fibronectin (see arrows) at the “wound edge” (paraffin, ABC-method, 480 ×)

ACT as described [18, 19] occurred in only a few of the vital cases investigated. Furthermore, an identical staining pattern was found in almost all postmortem lesions which imitated a postmortem interval similar to “vital” conditions. As a control in our series, a positive reactivity for A₁-ACT in mast cells, macrophages and endothelial cells was demonstrable in all specimens as expected [2]. In addition, the staining procedures were similar [Oehmichen et al.: peroxidase-antiperoxidase-method (PAP) – our series: avidin-biotin-complex method (ABC)] providing no evidence of technical reasons for the striking differences between both studies.

In our opinion the differences can only be explained by a misinterpretation of the staining pattern by Oehmichen et al. [18, 19] due to drying artefacts at the margins of the specimens, especially at the wound edges. Such an artefact has been discussed by these authors, since they noted unspecific staining reactions at the margins of paraffin sections. They excluded such an artefact since no similar staining pattern could be observed at the margins of the specimens due to tissue removal. However, they did not take into consideration that the wound area is exposed to air for a variable period of time during the postmortem interval possibly causing drying of the wound

margin. The margins due to tissue removal have insufficient contact to air since the specimens were fixed immediately in formaldehyde. Such an effect has also been observed in previous studies [3] and may also probably explain the findings of Oehmichen et al. [18, 19] that a “positive” reaction was not found in their postmortem lesions. It is possible that no relevant drying processes appear at the wound surface of injection marks due to wound structure and the lack of significant contact with air.

The assumption that the band-shaped staining pattern is nonspecific and a result of drying processes at the margins, especially at the wound edges, is supported by our observation that identical staining was also demonstrable for fibronectin, in particular at the wound edges of the postmortem lesions, as previously described [3].

Another aspect is that it is not easily conceivable that there is not time-dependent increase in the staining reaction for A₁-ACT or for the other proteinase inhibitors investigated by Oehmichen et al. [18], since they claimed a release of these proteins from mast-cells at the wound margins. In contrast, it would be much more conceivable that a time-dependent increase in the extent of the immunohistochemical reaction can be expected with the in-

ital phase of reactivity in cases of shorter survival times and an increasing positive staining in cases of advanced wound age as reported for fibronectin [3, 8] or peroxidase activity [13] for example.

In our series, only 5 out of 19 cases with wound ages between 50 min and 13 days showed a "positive" staining at the wound edge which was clearly distinguishable from the staining pattern due to drying artefacts. In 3 out of these 5 "positive" cases the distinct staining was restricted to the coagulated exudate which had developed at the epithelial layer. Such a non-specific reactivity has also been noticed for other proteins (own unpublished observations). A further aspect is that A₁-ACT is – like fibronectin – also present in serum [2]. Therefore, a "positive" reaction could be associated with serum extravasation, both in vital and postmortem lesions. This assumption can be supported by our observation that in some bleeding regions of the skin wounds investigated in our series, a weak positive staining for A₁-ACT in the form of string- or spot-like structures was found. This serum extravasation and therefore the release of proteinase inhibitors could also explain the 2 positively staining cases (wound age 3 h) found in our series showing a distinct band-shaped or spot-like staining at the wound edges which could be distinguished from the staining pattern in postmortem lesions by morphological criteria. A similar staining has already been shown for fibronectin, but such "fibronectin-reactivity" can be unambiguously distinguished [3] from the network-like structures in vital wounds positively staining for fibronectin.

Furthermore, our results confirm that the immunohistochemical localization of fibronectin provides reliable information on the vitality of human skin wounds even with short survival times (at least a few min) as previously described [3]. Skin wounds inflicted immediately before death, however, cannot be judged by this parameter since a certain survival time is necessary to establish the "vital" fibronectin staining.

In summary, fibronectin seems to be the only known reliable histological parameter indicating the vitality of skin wounds after short survival times. The immunohistochemical detection of A₁-ACT and probably of the other proteins investigated by Oehmichen et al. [18, 19] cannot, in our opinion, provide unambiguous results due to similar staining patterns obtained in postmortem lesions.

References

- Berg S, Ditt J, Friedrich D, Bonte W (1968) Möglichkeiten der biochemischen Wundaltersbestimmung. *Dtsch Z Gerichtl Med* 63:183–198
- Berninger RW (1986) Alpha₁-Antichymotrypsin. *J Med Exp Clin* 16:101–128
- Betz P, Nerlich A, Wilske J, Tübel J, Wiest I, Penning R, Eisenmenger W (1992) Immunohistochemical localization of fibronectin as a tool for the age determination of human skin wounds. *Int J Leg Med* 105:21–26
- Böhm E (1978) Der Nachweis der frühen lokalen Vitalreaktion durch Kombination morphologischer Untersuchungsmethoden. *Z Rechtsmed* 81:191–206
- Böhm E, Tschomakov M (1973) Ein Sekundenphänomen der vitalen Reaktion. *Beitr Gerichtl Med* 31:221–229
- Bonte W, Herrmann V (1978) Aktivitätsänderungen der unspezifischen Esterasen im Wundheilungsprozeß. Untersuchungen mit Hilfe der Elektrofokussierung. *Z Rechtsmed* 82:179–187
- Fazekas IG, Viragos Kis E (1971) Der Gehalt verschiedener Verletzungen an freiem Histamin als Vitalreaktion. *Z Rechtsmed* 68:86–94
- Fechner G, Hernandez M, Bajanowski T, Sepulchre MA, Brinkmann B (1992) Immunohistochemical alterations after muscle trauma. *Int J Leg Med* (in press)
- Hernandez-Cueto C, Luna A, Lorente JA, Villanueva E (1987) Study of cathepsin A, B and D activities in the skin wound edges. Its application to the differential diagnosis between vital and postmortem wounds. *Forensic Sci Int* 35:51–60
- Hsu SM, Raine L, Fanger HC (1981) A comparative study of the peroxidase-antiperoxidase method and an avidin-biotin complex method for studying polypeptide hormones with radioimmunoassay antibodies. *Am J Clin Pathol* 75:734–739
- Jarecki R, Arndt U, Schultz C, Klein H (1969) Zur Unterscheidung vitaler und postmortaler Wunden durch Bestimmung des Esterasemusters der Haut. *Dtsch Z Ges Gerichtl Med* 66:161–169
- Laiho K (1975) Haemostatic plugs as a histological vital reaction in the skin wounds of guinea pigs. *Z Rechtsmed* 76:41–48
- Laiho K (1988) Peroxidase activity in traumatic skin lesions. *Z Rechtsmed* 100:65–72
- Lindner J (1967) Vitale Reaktionen. *Dtsch Z Ges Gerichtl Med* 59:312–344
- Lorente JA, Hernandez-Cueto C, Villanueva E (1987) Cathepsin D: a new marker of the vitality of the wound. *Z Rechtsmed* 98:95–101
- Maeno Y, Takabe F, Mori Y, Iwasa M, Inoue H (1991) Simultaneous observation of catecholamine, serotonin and their metabolites in incised wounds of guinea pig. *Forensic Sci Int* 51:51–63
- Nevelös AB, Gee DJ (1970) Vital reaction in the epithelial connective tissue ground substance. *Med Sci Law* 10:175–177
- Oehmichen M, Schmidt V, Stuka K (1989) Freisetzung von Proteinaseinhibitoren als vitale Reaktion im frühen posttraumatischen Intervall. *Z Rechtsmed* 102:461–472
- Oehmichen M, Schmidt V, Stuka K (1989) Immunhistochemischer Vitalitätsnachweis von offenen Hautwunden am Paraffinschnitt. *Wiener Beitr Gerichtl Med* 47:7–11
- Oehmichen M (1990) *Die Wundheilung*. Springer, Berlin Heidelberg New York London Paris Tokyo Hong Kong
- Raekallio J (1965) Die Altersbestimmung mechanisch bedingter Hautwunden mit enzymhistochemischen Methoden. Schmidt-Römhild, Lübeck
- Raekallio J (1970) *Enzyme histochemistry of wound healing*. Fischer, Stuttgart
- Raekallio J (1972) Determination of the age of wounds by histochemical and biochemical methods. *Forensic Sci* 1:3–16
- Raekallio J (1973) Estimation of the age of injuries by histochemical and biochemical methods. *Z Rechtsmed* 73:83–102
- Raekallio J (1979) *Praktische Erfahrungen mit den biochemischen vitalen Reaktionen*. *Beitr Gerichtl Med* 37:147–151
- Schneider V (1974) Über rasterelektronenmikroskopische Untersuchungen an vital und postmortal entstandenen „Thromben“. *Z Rechtsmed* 74:47–54
- Walcher K (1930) Über vitale Reaktionen. *Dtsch Z Ges Gerichtl Med* 15:16–57
- Walcher K (1936) Die vitale Reaktion bei der Beurteilung des gewaltsamen Todes. *Dtsch Z Ges Gerichtl Med* 26:193–211