



Case report

Fatalities due to intestinal obstruction following the ingestion of foreign bodies

P. Betz*, L. van Meyer, W. Eisenmenger

Department of Legal Medicine, University of Munich, Frauenlobstrasse 7a, 80337 Munich, Germany

Received 6 April 1994; revision received 30 May 1994; accepted 8 June 1994

Abstract

Two fatalities due to an occlusive ileus following the ingestion of foreign bodies in patients with psychiatric disorders are described. A severely mentally handicapped young man developed a temperature and died 1 h after admission to a surgical ward. At autopsy, ~2000 cm³ of foreign material, including broken glass and porcelain, branches, buttons, parts of clothing and other material were found in the gastrointestinal tract, leading to a complete obstruction of the distal intestine and colon with resulting faecal vomiting. The other case was even more unusual as a hair fetishist had swallowed a thick strand of his own hair, 50 cm long, also resulting in mechanical obstruction of the distal intestine.

Keywords: Intestinal obstruction; Psychiatric disorders; Mental retardation; Hair fetishism

1. Introduction

Fatalities due to the ingestion of foreign bodies are not frequent, but neither are they particularly rare in forensic medicine. There are different reasons for an intentional swallowing, for example, drug smuggling [1,2] or simulation of gastrointestinal disorders, mainly among inmates in custody, and swallowing almost every available object like knives, forks, nails, wires and so on [3,4]. Accidental intestinal

* Corresponding author.

obstruction is described as a result of the ingestion of foodstuffs [5–7] or other causes [8]. In addition, the ingestion of foreign material in patients with psychiatric disorders is well-known and such cases are sometimes characterized by very unusual features. The present paper reports on two such fatalities.

2. Circumstances

2.1. Case report A

A 22-year-old mentally handicapped young man had resided in a psychiatric hospital since 1988. He was unable to speak and in the past it was repeatedly observed that he ingested various foreign bodies, in particular broken glass. In June 1993 the patient had a temperature and his physical condition deteriorated rapidly. On the next day he was admitted to a surgical ward where he died shortly afterwards.

At autopsy, a button and a small amount of a yellow-brown fluid was found in the stomach. In the whole intestine foul-smelling yellow-brown content was observed, containing small branches and stones, several buttons, paper and parts of clothes. Twelve cm proximal from the ileo-caecal valve the consistency of the material increased and the colon, which was the diameter of an upper arm, was completely filled with broken glass, fragments of porcelain, buttons, balloons, cords and clips of metal. The total volume of the ingested foreign bodies was $\sim 2000 \text{ cm}^3$ (Fig. 1). In addition to the signs of occlusive ileus, fluid similar to that found in the stomach

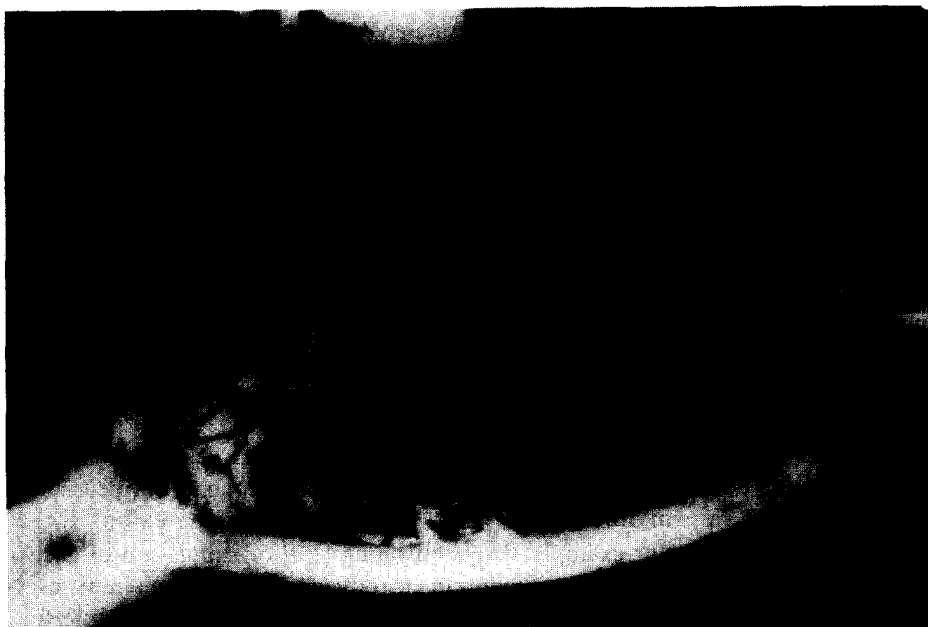

Fig. 1. Volume of foreign material ($\sim 2000 \text{ cm}^3$) found in the bowels of a mentally handicapped 22-year-old man (case report A).

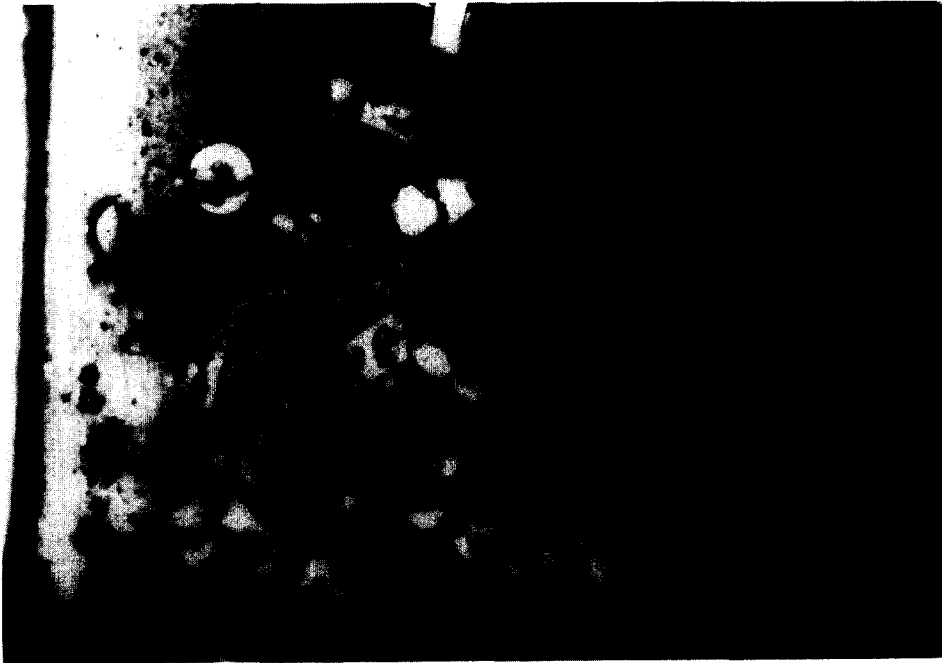


Fig. 2. Foreign bodies found in the bowels of a mentally handicapped 22-year-old man (case report A).

and the bowels was present in the oral cavity, indicating faecal vomiting. Reactive changes of the bowel wall, however, were not detectable, apart from slight reddening. Since the other organs showed no pathological changes, a mechanical ileus could unambiguously be assumed to be the cause of death.

2.2. Case report B

A 45-year-old unemployed man was found dead in his apartment on 16 February 1994. Considerable amounts of vomit were present on the floor near the corpse, which already showed signs of advanced putrefaction. On the walls of the apartment numerous pictures of female nude models with extremely long hair were attached. Furthermore, 20 hair strands of different colours but exactly the same length were placed accurately next to each other on a wall and, in addition, a long hair wig was found. On a page of a calendar, the man had documented exactly the dates of hair-washing and on 25 January 1994 he had made a note saying that he had cut off a strand of his own hair.

The investigations of the criminal police revealed that a year before death a large hairball had been removed from the stomach by gastrostomy since signs of an early occlusive ileus had occurred. It was known that the patient had repeatedly swallowed

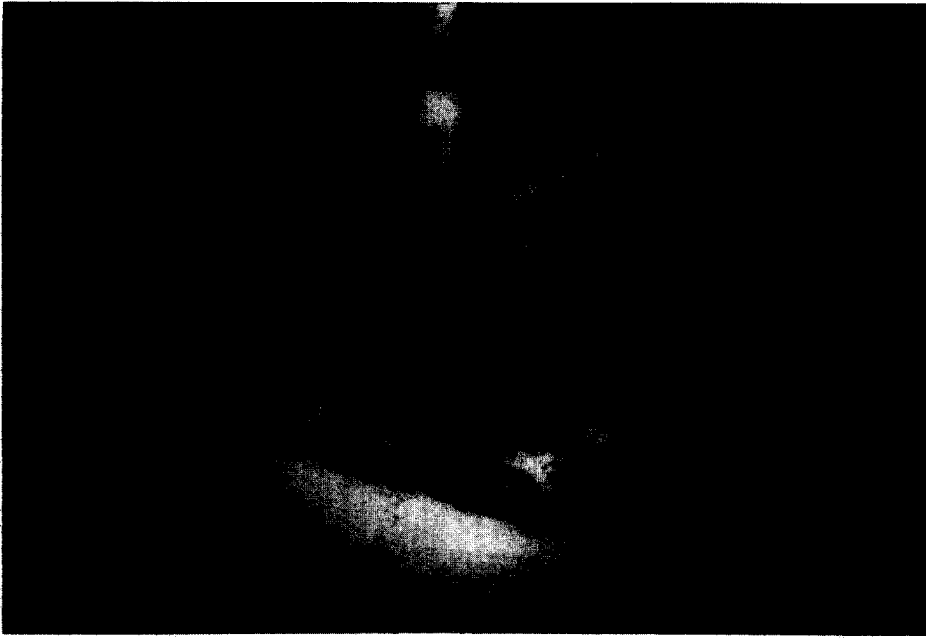


Fig. 3. 'In-situ' localization of the obstructing hair strand in the intestine of a hair fetishist (see the different diameters of the intestine proximal and distal from the obstruction, case report B).

his hair and the psychiatric diagnosis of hair fetishism was made, but the man refused therapy.

At autopsy, the hair was ~50 cm long and a thick strand of hair showing a similar length and identical colour was found in the distal part of the intestine, which was completely obstructed. The intestine proximal to the obstruction was considerably enlarged while the distal parts showed no apparent changes (Fig. 2). No relevant pathological alterations of other organs could be established, and toxicological investigations and blood alcohol determination revealed negative results. Therefore, an acute occlusive ileus due to an intestinal trichobezoar was considered to be the cause of death.

3. Discussion

The forensic pathologist has to attend from time to time to fatalities due to an occlusive ileus, or perforation of the bowels due to sharp edges of objects, or pressure necrosis of the bowel wall following intentional or accidental ingestion of foodstuffs [5–7] or foreign bodies [1,8–12]. In cases of mechanical obstruction by sufficiently bulky objects, the usual site of the localization of the foreign body is generally considered to be the terminal ileum (see our case B), while smaller particles can be observed also in the large bowel (see our case A) [5,12].

Apart from the problem of body packing [1,2], which additionally bears the risk of a resorption of the drug in the gastrointestinal tract, such cases are mainly of secondary forensic interest. On the other hand, however, very unusual fatalities can occur among individuals with psychiatric disorders. These patients can use the ingestion of foreign bodies to simulate various internal disorders in order to gain medical support [13] but a lethal course may occur unintentionally. Furthermore, it is possible that they are not aware of their actions due to gross mental retardation, as seen in our first case. In the latter context the question arises whether the supervisory staff have fulfilled their legal responsibility to care for the patients, but this problem is not addressed by this article. Our case, however, can verify the volume (in our example a total of $\sim 2000 \text{ cm}^3$) and heterogeneity of sometimes sharp foreign objects which can be ingested without perforation of the bowels [9].

Besides an intentional uptake to simulate disorders or an 'accidental' swallowing due to severe mental handicap, other motivations can be the reason for an ingestion of foreign bodies by psychiatric patients, as our second case verifies. The deceased was obviously suffering from hair fetishism and the diagnosis was made a year before death on the occasion of a similar event leading to gastrostomy. The exceptional quality, however, is not the diagnosis of hair fetishism which was obvious from the appearance of the man's apartment, but rather the characteristic of repeated swallowing of his own hair. The ingestion of hair in order to simulate an internal disorder is not unusual and has been described in the old forensic literature [14], but, to our knowledge, no fatality of a hair fetishist due to an occlusive ileus produced by ingested hair strands has been reported up to now. Therefore, these case reports are further examples of unusual deaths following the ingestion of foreign bodies and complement the cases already described in the forensic literature.

References

- [1] P.M. Dassel and E. Punjabi, Ingested marijuana filled balloons. *Gastroenterology*, 76 (1979) 166–169.
- [2] F.U. Lutz and J. Reuhl, Body packing als tödliches Risiko — Ergebnisse einer Fragebogenaktion in Westeuropa. *Wiener Beitr. Gerichtl. Med.*, 50 (1992) 211–214.
- [3] G.A. Wray and H.W. Eldridge, A knife swallowed in prison retrieved at oesophagoscopy. *Med. Sci. Law*, 10 (1970) 85.
- [4] R. Goedel, Zur Mentalität der Fremdkörperschlucker, speziell der Gefängnisinsassen. *Dtsch Z. ges gerichtl. Med.*, 19 (1932) 63–75.
- [5] M.J. Heath, Intestinal obstruction due to ingestion of food bolus. *Med. Sci. Law*, 20 (1980) 108–109.
- [6] P. Durdey, Intestinal obstruction and perforation due to an ingested Brazil nut. *J. R. Coll. Surg. Edinb.*, 30 (1985) 395.
- [7] T. Osler, C.L. Stackhouse, P.A. Dietz and W.B. Guincy, Perforation of the colon by ingested chicken bone, leading to diagnosis of carcinoma of the sigmoid. *Dis. Colon Rectum*, 28 (1985) 177–179.
- [8] W.G.A. Woods, Condom ileus: result of a practical joke. *Postgrad. Med. J.*, 63 (1987) 501–502.
- [9] V.O. Lundmark, D. Metheny and E. Sanderson, Intestinal perforation due to ingested foreign bodies. *Northwest Med.*, 52 (1953) 380–382.
- [10] J.E. MacManus, Perforation of the intestine by ingested foreign bodies: report of two cases and review of the literature. *Am. J. Surg.*, 53 (1941) 393–400.

- [11] P.A. Nash and P.C. Cregan, Perforation of the gastrointestinal tract by a toothpick. *Med. J. Aust.*, 147 (1987) 415–416.
- [12] G.C.A. Fernando, Colonic perforation following the ingestion of plastic sheeting. *Med. Sci. Law*, 29 (1989) 263–264.
- [13] K.D. Bock and F. Overkamp, Factitious disorders. Report on forty-four cases in a medical department and a proposal for subclassification. *Klin. Wochenschr.*, 64 (1986) 149–164.
- [14] E.W. Baader and H. Symanski, Die Simulation innerer Krankheiten. In: J. Mayr (ed.), *Handbuch der Artefakte*, Jena, 1937, pp. 193–235.