

Volume 148

July 1992


Number 1

---

# The Journal of UROLOGY®

---

Official Journal of the American Urological Association, Inc.  
Founded In 1917 By Hugh Hampton Young



---

Annual Meeting, American Urological Association, Inc., San Antonio, Texas, May 15-20, 1993

148, 1-3  
1992

380

G

# The Journal of UROLOGY

Volume 148

July 1992

Number 1

## CLINICAL UROLOGY

### Review Article

- Quantitative Light Microscopy in Urological Oncology. *H. G. van der Poel, H. E. Schaafsma, G. P. Vooijs, F. M. J. Debruyne and J. A. Schalken* ..... 1

### Original Articles

- Fast Magnetic Resonance Imaging in Evaluation of Tumoral Obstructions of Inferior Vena Cava. *A. Rahmouni, D. Mathieu, J.-F. Berger, J.-L. Montazel, D. K. Chopin and N. Vasile* ..... 14
- Extracorporeal Shock Wave Lithotripsy for Patients With Calcified Ipsilateral Renal Arterial or Abdominal Aortic Aneurysms. *S. W. Carey and S. B. Stroom* ..... 18
- False Positive Prostate Specific Antigen Values in Sera of Women With Renal Cell Carcinoma. *K. Pummer, G. Wirnsberger, P. Pürstner, H. Stettner and G. Wandschneider* (Editorial Comments by T. A. Stamey, and P. H. Lange and R. E. Vessella) ..... 21
- Conservative Surgery of Renal Cell Tumors in 140 Patients: 21 Years of Experience. *F. Steinbach, M. Stöckle, S. C. Müller, J. W. Thüroff, S. W. Melchior, R. Stein and R. Hohenfellner* (Editorial Comments by A. C. Novick and F. F. Marshall) ..... 24
- Transitional Cell Carcinoma of Renal Pelvis and Ureter: Prognostic Relevance of Nuclear Deoxyribonucleic Acid Ploidy Studied by Slide Cytometry: 8-Year Survival Time Study. *H. Al-Abadi and R. Nagel* ..... 31
- Complications Following Unstented Parallel Incision Extravesical Ureteroneocystostomy in 1,000 Kidney Transplants. *W. S. Gibbons, J. M. Barry and T. R. Hefty* ..... 38
- Frequency of Histopathological Abnormalities in Incidental Appendectomy in Urological Patients: Implications for Incorporation of Appendix in Urinary Tract Reconstruction. *I. Leibovitch, I. Avigad, O. Nativ and B. Goldwasser* ..... 41
- Cytogenetic Studies of Carcinoma In Situ of Bladder: Prognostic Implications. *M. Tyrkus, I. Powell and W. Fakr* ..... 44
- Deoxyribonucleic Acid Flow Cytometry in Invasive Bladder Carcinoma: Possible Predictor for Successful Bladder Preservation Following Transurethral Surgery and Chemotherapy-Radiotherapy. *E. B. Hug, S. M. Donnelly, W. U. Shipley, N. M. Heney, D. S. Kaufman, F. I. Preffer, S. M. Schwartz, R. B. Colvin and A. F. Althausen* ..... 47
- Combination Cisplatin and Dichloromethotrexate in Patients With Advanced Bladder Cancer. Phase 2. Southwest Oncology Group Study. *F. J. Meyers, B. Blumenstein, E. D. Crauford, H. E. Hynes, J. E. Montie, S. A. Taylor, H. B. Grossman and R. B. Natale* ..... 52
- Modified Vascularized Pedicled Scrotal Flap for Complex Hypospadias. *I. Mokhless* (Editorial Comment by J. W. Duckett, Jr.) ..... 55
- Congenital Defect in Sinusoidal Smooth Muscles: Cause of Organic Impotence. *S. R. Aboseif, L. S. Baskin, T. S. B. Yen and T. F. Lue* ..... 58
- Combined Intracavernous Injection and Stimulation Test: Diagnostic Accuracy. *C. F. Donatucci and T. F. Lue* ..... 61
- Penile Pharmacological Duplex Ultrasonography: Dose-Effect Study Comparing Papaverine, Papaverine/Phentolamine and Prostaglandin E1. *E. J. H. Meuleman, B. L. H. Bemelmans, W. H. Doesburg, W. N. J. C. van Asten, S. H. Skotnicki and F. M. J. Debruyne* ..... 63
- Cancer Metastatic to Penis: Treatment With Hyperthermia and Radiation Therapy and Review of Literature. *R. Ben-Yosef and D. S. Kapp* ..... 67
- Globotriaosyl Ceramide Glycolipid in Seminoma: Its Clinicopathological Importance in Differentiation From Testicular Malignant Lymphoma. *C. Ohyama, S. Orikasa, M. Satoh, S. Saito, H. Ohtani and Y. Fukushi* ..... 72
- Comparison Between Clinical and Pathological Staging in Low Stage Nonseminomatous Germ Cell Testicular Tumors. *G. Pizzocaro, N. Nicolai, R. Salvioni, L. Piva, M. Faustini, F. Zanoni and A. Milani* (Editorial Comment by J. P. Richie) ..... 76
- Prostatic Abscess: Diagnosis and Treatment. *E. A. Granados, G. Riley, J. Salvador and J. Vicente* (Editorial Comments by J. N. Krieger and D. T. Uehling) ..... 80
- Effect of Digital Rectal Examination on Serum Prostate Specific Antigen Concentration: Results of Randomized Study. *F. M. Chybowski, E. J. Bergstralh and J. E. Oesterling* ..... 83
- Correlation of Prostate Cancer Nuclear Deoxyribonucleic Acid, Size, Shape and Gleason Grade With Pathological Stage at Radical Prostatectomy. *J. I. Epstein, G. Pizov, G. D. Steinberg, H. B. Carter, R. Pitcock, O. A. Armas, A. Partin and P. C. Walsh* ..... 87
- Early Continence After Radical Prostatectomy. *E. A. Klein* (Editorial Comment by E. J. McGuire) ..... 92

Contents continued on page A9

**Urologists At Work**

Laparoscopic Drainage of Lymphocele After Renal Transplantation. *S. A. Slavis, L. D. Gardner, C. Swift and M. L. Gross* ..... 96

New Procedure for Biopsy of Solid Renal Mass: Transurethral Approach Under Fluoroscopic Control. *J. J. Leal* ..... 98

Choice of Gastroepiploic Vessels for Gastrocystoplasty. *S. A. Bissada and N. K. Bissada* ..... 101

Improved Pump Placement With Infrapubic Penile Prosthetic Implantation. *R. J. Graydon and B. B. Berlin* ..... 102

**Urological Neurology and Urodynamics**

Detrusor Function With Lesions of Conus Medullaris. *A. Beric and J. K. Light* ..... 104

Influence of Anterior Root Stimulation (S2) in Deafferented Spinal Cord Injury Men on Cavernous Electrical Activity. *C. G. Stief, D. Sauerwein, W. F. Thon, E. P. Allhoff and U. Jonas* ..... 107

Improved Indication and Followup in Transurethral Resection of Prostate Using Computer Program CLIM: Prospective Study. *H. J. Rollema and R. van Mastrigt* (Editorial Comments by R. C. Bruskevitz and J. G. Blaivas) ..... 111

**Pediatric Articles**

Continent Appendicocolostomy: Variation of Mitrofanoff Principle in Pediatric Urinary Tract Reconstruction. *J. S. Elder* ..... 117

Contrast-Induced Central Nervous System Toxicity After Radiographic Evaluation of Lower Urinary Tract in Myelodysplastic Patients With Ventriculoperitoneal Shunts. *B. Dalkin, I. Franco, E. F. Reda, D. McLone, L. Godine and W. E. Kaplan* ..... 120

Predictive Value of Ultrasonography in Evaluation of Infants With Posterior Urethral Valves. *W. C. Hulbert, H. K. Rosenberg, P. C. Cartwright, J. W. Duckett and H. McC. Snyder* ..... 122

Prognosis for Patients With Prenatally Diagnosed Posterior Urethral Valves. *Y. Reinberg, I. de Castano and R. Gonzalez* ..... 125

Treatment of Urinary Incontinence in Children Using Glutaraldehyde Cross-Linked Collagen. *J. Wan, E. J. McGuire, D. A. Bloom and M. L. Ritchey* ..... 127

Primary Endodermal Sinus Tumor of Penis. *S. S. Alurkar, B. N. Dhabhar, N. A. Jambhekar, J. N. Kulkarni and S. H. Advani* ..... 131

Acute Bilateral Testicular Torsion in Adolescent. *B. N. Benge, G. R. Eure and B. H. Winslow* ..... 134

Bilateral Primary Neuroblastomas in Inguinal Canal. *M. E. Leo, M. J. McManus, L. R. Strawbridge and S. A. Kramer* ..... 135

**Case Reports**

Spontaneous Regression of Metastases in Case of Bilateral Renal Cell Carcinoma. *J. C. Kallmeyer and O. C. Dittrich* ..... 138

Inflammatory Pseudotumor of Bladder. *D. D. Dietrick, J. N. Kabalin, G. F. Daniels, Jr., A. B. Epstein and I. M. Fielding* ..... 141

Restenosis of Urethra Despite Indwelling Wallstent. *Z. W. Sneller and R. J. L. H. Bosch* (Editorial Comments by R. O. Parra and C. J. Devine, Jr.) ..... 145

False Diagnoses of Venous Leak Impotence. *D. K. Montague and M. M. Lakin* ..... 148

Three Cases of DIDMOAD or Wolfram's Syndrome: Urological Aspects. *A. Thomas, A. Farmakis, Z. Sami, E. Davillas and N. Davillas* ..... 150

**INVESTIGATIVE UROLOGY**

Presence of Antibacterial Glycoprotein in Spectrum of Transitional Cell Carcinomas. *R. M. Moldwin, D. Shupp-Byrne, H. J. Callahan and S. G. Mulholland* ..... 154

Effect of Outlet Obstruction on <sup>3</sup>H-Thymidine Uptake: Biochemical and Radioautographic Study. *F. C. Monson, B. A. W. McKenna, A. J. Wein and R. M. Levin* ..... 158

Prevention of Acrolein-Induced Bladder Injury by Pentosanpolysulfate. *S. J. Kalota, P. C. Stein and C. L. Parsons* ..... 163

Collagen and Bladder Function in Streptozotocin-Diabetic Rats: Effects of Insulin and Aminoguanidine. *B. Eika, R. M. Levin and P. A. Longhurst* ..... 167

Characterization of Bovine Bladder Mucin Fractions That Inhibit Escherichia Coli Adherence to Mucin Deficient Rabbit Bladder. *M. R. Ruggieri, R. K. Balagani, J.-J. Rajter and P. M. Hanno* ..... 173

Pharmacological In Vitro Study of Mouse Urinary Bladder at Time of Acute Change in Bladder Reservoir Function After Irradiation. *F. Lundbeck and C. Sjögren* ..... 179

Cystometry in Mice—Influence of Bladder Filling Rate and Circadian Variations in Bladder Compliance. *W. Dörr* ..... 183

Implantable Penile Venous Compression Device: Initial Experience in Acute Canine Model. *J.-S. Paick, B. Marc, J. K. Suh, A. K. Batra, T. F. Lue and E. A. Tanagho* ..... 188

Human Papillomavirus and Herpes Virus DNA are Not Detected in Benign and Malignant Prostatic Tissue Using Polymerase Chain Reaction. *U. Serfling, G. Ciancio, W.-Y. Zhu, C. Leonardi and N. S. Penneys* ..... 192

Detubularization-Induced Contractile Response Change of Ileum Following Ileocystoplasty. *A. K. Batra, P. M. Hanno and M. R. Ruggieri* ..... 195

Comparison of Stone Damage Caused by Different Modes of Shock Wave Generation. <i>C. J. C. Chuong, P. Zhong and G. M. Preminger</i> .....	200
Studies on Afferent and Efferent Renal Nerves Following Autotransplantation of Canine Kidney. <i>B. Sankari, N. Stowe, J. P. Gavin, S. Satoh, J. V. Nally and A. C. Novick</i> .....	206
Entubulization Repair of Severed Cavernous Nerves in Rat Resulting in Return of Erectile Function. <i>R. A. Ball, S. A. Lipton, E. B. Dreyer, J. P. Richie and M. A. Vickers</i> .....	211
Comparative Autonomic Responses of Cat and Rabbit Bladder and Urethra. <i>R. M. Levin, L. Hayes, B. Eika, E. J. McGuire, A. Elbadawi and A. J. Wein</i> .....	216
Optimal Parameters for CO <sub>2</sub> Laser Reconstruction of Urethral Tissue Using Protein Solder. <i>D. P. Poppas, C. T. Rooke and S. M. Schlossberg</i> .....	220

## UROLOGICAL SURVEY

Benign and Malignant Neoplasms of Prostate .....	226
Imaging .....	228
Pediatric Urology .....	231
Perioperative Care .....	237
Urinary Tract Infection .....	241
Book Review .....	245

<b>News and Announcements</b> .....	247
-------------------------------------	-----

### PROPRIETARY NAMES

Many of the words appearing in the JOURNAL OF UROLOGY are proprietary names even though no reference to this fact is made in the text. The appearance of any name without designation as proprietary is, therefore, not to be regarded as a representation by the editorial committee or publisher that it is not the subject of proprietary rights.

### GUIDELINES FOR SUPPLEMENTS

The Editors of the Journal will consider requests for and solicit sponsors of Supplements to The Journal of Urology. For those interested the following are the proposed steps for publication of a Supplement.

1) Proposal formulated by sponsors of the Supplement or solicited by the Journal Editorial Staff that would include an indication of the major topics with a limited outline of subtopics, the nature of the articles to be included (review, original papers with or without discussion), identification of a sponsoring group or individual, identification of the type of internal quality control group available for the Journal Editors to work with and an indication of the financial support available.

2) Response by the Editorial Staff with identification of a specific individual to work with the Editorial Committee of the sponsors.

3) Agree to a deadline for submission of the papers, number of papers and so forth.

4) Formulation of and agreement on procedure for initial screening and editorial evaluation of manuscripts and discussions with active participation by the sponsoring group.

5) Submission to the Editorial Staff of the Journal for their evaluation.

6) Interaction between Journal and sponsoring editorial group. Final decision is retained by Journal Editorial Staff.

7) Redaction, page proofing and so forth by Editorial Staff. Articles in supplements would be indexed in the Journal.

8) Publication.

### DISCLAIMER

The statements and opinions contained in the articles of JOURNAL OF UROLOGY are solely those of the individual authors and contributors and not of the American Urological Association, Inc. or Williams & Wilkins. The appearance of the advertisements in the Journal is not a warranty, endorsement or approval of the products or services advertised or of their effectiveness, quality or safety. The American Urological Association, Inc., and the Publisher disclaim responsibility for any injury to persons or property resulting from any ideas or products referred to in the articles or advertisements.

# THE INFLUENCE OF ANTERIOR ROOT STIMULATION (S2) IN DEAFFERENTED SPINAL CORD INJURY MEN ON CAVERNOUS ELECTRICAL ACTIVITY

CHRISTIAN G. STIEF, DIETER SAUERWEIN, WALTER F. THON, ERNST P. ALLHOFF AND UDO JONAS

*From the Department of Urology, Medizinische Hochschule Hannover, Hannover, and W. Wicker Klinik, Bad Wildungen, Germany*

## ABSTRACT

Registration of cavernous electrical activity (single potential analysis of cavernous electrical activity) was recently suggested for the diagnosis of autonomic cavernous dysfunction. For validation of this method the effect of sacral neurostimulation on cavernous electrical activity was examined. In 3 male patients with a complete spinal cord lesion (T3, T4 and T12, respectively), deafferentation was done at the S2 to S5 levels. Around the anterior roots of S2 to S5 electrodes for neurostimulation were placed. Cavernous electrical activity was recorded with an intracavernous needle electrode and with surface electrodes in the flaccid as well as in the erect states induced by neurostimulation (at 7, 8, 12, 18, 20, 30 and 45 Hz., 30 v. and 0.4 msec.). In all patients similar potentials compared to the normal values, as well as additional pathological potentials were recorded during flaccidity. During neurostimulation all patients achieved full erection with no or markedly decreased cavernous electrical activity to frequencies of 12, 18, 20 and 30 Hz., while to 7, 8 and, more pronounced, 45 Hz. only partial erection with ongoing cavernous electrical activity was found. Our study strongly suggests that cavernous electrical activity and, subsequently, the cavernous smooth muscle tone are dependent on autonomic input. This finding supports the hypothesis that single potential analysis of cavernous electrical activity may be valid in the diagnosis of cavernous autonomic dysfunction. Furthermore, our results suggest a possible role for single potential analysis of cavernous electrical activity in the fine tuning of erection inducing neurostimulators.

KEY WORDS: penile erection; impotence; muscle, smooth; autonomic nervous system

A major drawback in the diagnosis of erectile dysfunction was the lack of a method to examine the integrity of autonomic cavernous innervation responsible for penile erection. In 1988 Wagner<sup>1,2</sup> and Gerstenberg<sup>3</sup> et al first described the registration of cavernous electrical activity. They observed a periodic electrical activity and described that this activity subsided during erection induced by audiovisual sexual stimulation. Since the phenomenon of erection is regulated by autonomic nervous input,<sup>4-6</sup> they assumed that ongoing cavernous periodic electrical activity during audiovisual sexual stimulation may be related to autonomic cavernous dysfunction. In 1990 a different data processing that allows for interpretation of the individual potentials of cavernous electric activity (single potential analysis of cavernous electrical activity) was reported.<sup>7</sup> This method possibly enables the diagnosis of cavernous autonomic dysfunction. Similar to the classical electromyogram of the striated muscles, specific potentials seem to correlate to peripheral or central neurological lesions.

The aforementioned studies and the interpretation of their results must postulate that cavernous electrical activity is under autonomic control and, therefore, an abnormal autonomic cavernous supply should result in an abnormal cavernous electrical activity. We attempt to verify this hypothesis by examining the influence of direct electrical stimulation of the sacral parasympathetic nerves on cavernous electrical activity. For this study patients were examined who had received an implant for bladder evacuation that was also usable to induce penile erection.

## PATIENTS AND METHODS

We examined 3 men with complete post-traumatic spinal cord lesions. Patient 1 was 34, patient 2 was 42 and patient 3

was 47 years old. The complete spinal cord lesion was at the T3 to T4 (and incomplete at C7 to T2), T4 to T6 and T12 levels, respectively. The interval since the accident was 13, 10 and 13 years, respectively. For treatment of bladder spasticity in all patients, sacral deafferentation (dorsal rhizotomy) was done at the level of S2 to S5 (fig. 1) and platinum foil electrodes for neurostimulation were placed around the anterior roots of S2 to S5 in "books" (that is U-shaped electrodes mounted in slots<sup>8</sup>). In all patients complete bladder emptying, bowel evacuation and penile erection could be achieved by different neurostimulation patterns.

Registration was done with a neurophysiological unit.\* Recording parameters were a frequency range of 0.5 to 100 Hz., amplification of 50  $\mu$ v. per unit (amplification  $\times$ 5,000) and a paper speed of 0.5 cm. per second. The examination was done with the patient in the supine position. Recording of cavernous electrical activity was done simultaneously with a coaxial needle electrode (Dantec No. 9013 L, length 4 cm., surface of the tip 0.07 mm.<sup>2</sup>) placed in the left proximal cavernous body as well as with surface electrodes (Dantec 12L30) bilaterally over the proximal cavernous bodies.

During the examination the patients were advised to relax and to close their eyes. After recording of cavernous electrical activity during flaccidity for about 20 to 30 minutes, erection was induced by neurostimulation of the anterior roots of S2 bilaterally using a transcutaneous stimulator.† Stimulation was done using frequencies of 25, 18, 11, 8, 7, 30, 45, 20 and 7.5 Hz. Each frequency was applied for 30 to 40 seconds. Energy was set at 30 v. (because stimulation is applied transcutaneously, only volts and not milliamperes can be indicated, since the actual stimulation current cannot be measured without invasive

Accepted for publication November 8, 1991.

Supported by Grants Sti 96/2-1 and Sti 96/2-2 from the Deutsche Forschungsgemeinschaft.

\* Space, Wiest, Germany and modified Neuromatic, Dantec, Denmark.

† Brindley stimulator, England.

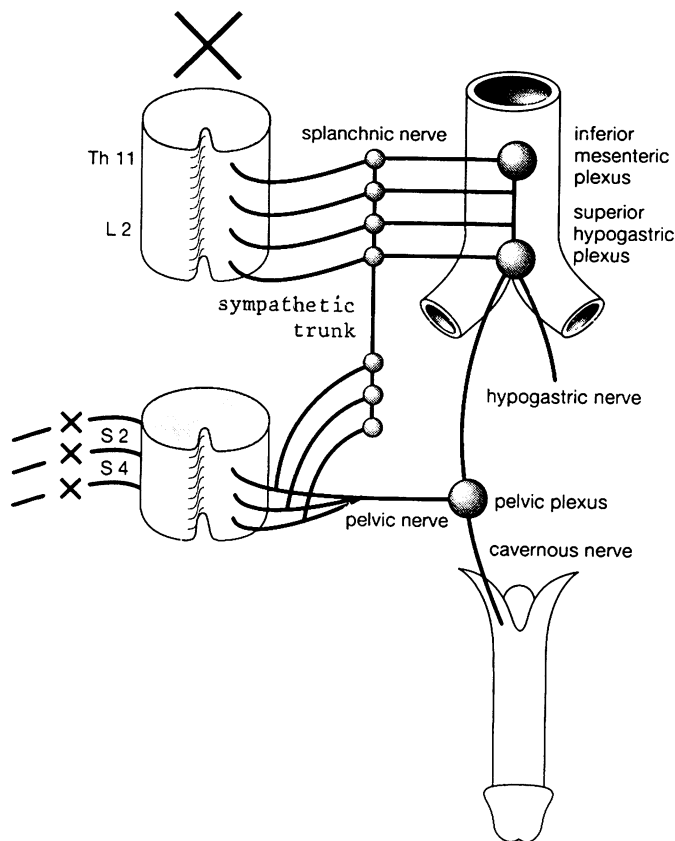


FIG. 1. Autonomic cavernous nerve supply in 3 patients with complete spinal cord injury and sacral deafferentation.

procedures) and pulse width was 400  $\mu$ sec. The erectile response was evaluated by the examiner by inspection and palpation. To verify reproducibility, stimulation was repeated after a 20-minute period of flaccidity. Frequencies used were then 20, 7, 8, 12, 18, 20, 30, 45 and 20 Hz.

#### RESULTS

All patients reported an absence of reflexogenic erections. Patients 2 (T4 to T6) and 3 (T12) reported psychogenic erections with good tumescence but insufficient rigidity for intramission. During flaccidity patient 1 showed cavernous electrical activity similar to patients with peripheral autonomic lesions.<sup>7</sup> No normal cavernous electrical potentials were observed. In patients 2 and 3 potentials similar to those found in the normal (fig. 2) as well as highly abnormal whips (fig. 3) were recorded.

Stimulation of the anterior roots of S2 induced a frequency dependent erectile response in all patients. A full rigid erection was noted with frequencies of 12, 18, 20 and 30 Hz. while to 7, 8 and 45 Hz. full tumescence with no or only minor rigidity

was observed. When the stimulation frequency was 12 to 30 Hz. and a full erectile response was observed, cavernous electrical activity was decreased dramatically and showed only small potentials of high frequency (fig. 4, A to G). To frequencies of 7 and 8 Hz. only penile tumescence with mild rigidity was achieved and cavernous electrical activity showed a wave-like pattern (fig. 4, C to E and H). To 45 Hz. only tumescence without rigidity was observed and cavernous electrical activity showed a comparable pattern to that during flaccidity before neurostimulation (fig. 4, F and G). All recordings were reproducible in each patient.

#### DISCUSSION

In all 3 patients complete spinal cord injury above the level of S2 combined with complete sacral deafferentation excludes reflex activity of the sacral parasympathetic system for erection. Nevertheless, recording of cavernous electrical activity in patients 2 and 3 showed mostly normal potentials, together with scattered abnormal whips. This may be explained by the fact that the sympathetic system functions normally in these patients and synchronizes the cavernous electrical activity in the flaccid state. The origin of the whips in these patients remains unclear. It may be due either to focal lesions to the sympathetic system by the initial trauma itself, to minor lesions to the anterior roots of S2 during the electrode placement or to the central denervation of the sacral parasympathetic system. Another explanation may be longitudinal injury to the sacral cord at the time of injury.

In patient 1 no normal potentials and no repetitive synchronous cavernous electrical activity (with an amplitude of more than 10  $\mu$ v.) were recorded. This patient had an incomplete lesion from C7 to T2 and a complete lesion of T3 and T4. He did not report any psychogenic erections. A possible explanation may be the complete destruction of the sympathetic system at the C7 level and below by the initial trauma. Since C7 is the most cranial level of communication between the spinal cord and sympathetic trunks, such a destruction would completely interrupt the central sympathetic input to the cavernous bodies. This interruption would explain the absence of psychogenic erections and the nonsynchronization of the cavernous electrical activity.

Electrical stimulation of the anterior roots of S2 induced an erectile response depending on the applied stimulation frequency. To 12 to 30 Hz. a full erection with a cavernous electrical activity of high frequency and low amplitude was observed. This finding is in correlation with the recordings in normal men, in whom full erection is accompanied by cavernous electrical activity of high frequency and low amplitude.<sup>7</sup> To frequencies of 7, 8 and 45 Hz. only an incomplete erectile response with pronounced or even normal cavernous electrical activity was found. This corresponds well to the findings in animals, where neurostimulation of the cavernous nerve induces a full erection to frequencies of 15 to 30 Hz., with lower




FIG. 2. Upper recording is done with needle electrode and lower recording with surface electrodes. Recording shows normal cavernous electrical potential. Horizontal bar is 5 seconds. Vertical bar is 100  $\mu$ v.

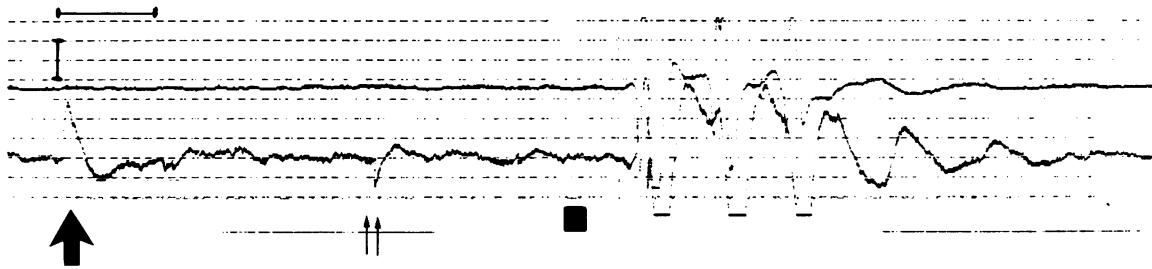


FIG. 3. In same patient as in figure 2. recording of surface electrodes shows positive (large arrow) and negative (double arrows) whips. Horizontal bar is 5 seconds. Vertical bar is 40  $\mu\text{v}$ .

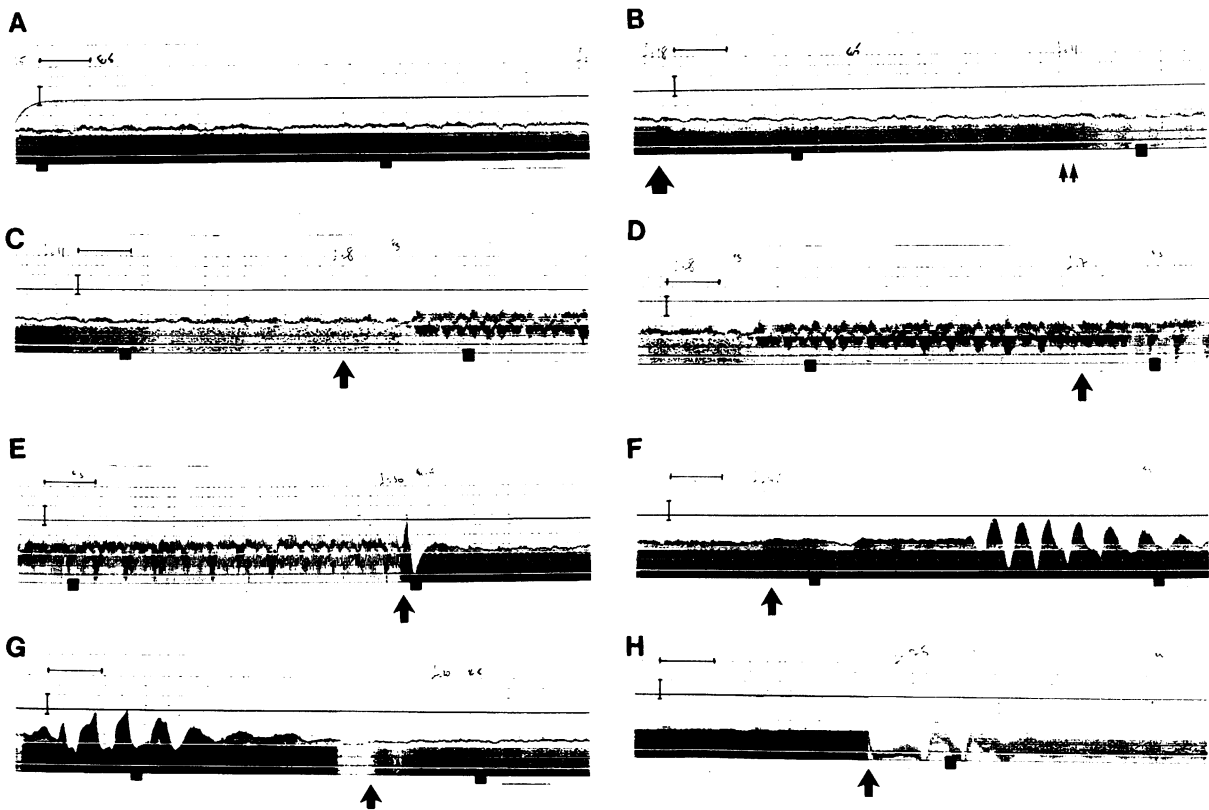


FIG. 4. Continuous recording of cavernous electrical activity with surface electrodes (lower tracing) during stimulation of anterior roots of S2 at different frequencies. Needle electrode recording (upper tracing) had to be shut off due to extensive stimulus artifacts. Dark surface below lower tracing is due to stimulus artifact (spikes at stimulation frequency), so that in lower tracing attention should be directed to upper portion. During full erection no or only minimal wave-like electrical activity is observed. Pronounced wave-like electrical activity is correlated with incomplete erection. Since electrical stimulation induced penile tumescence with or without rigidity in this continuous recording, no action potentials (as in figure 2 or 3) but only more or less pronounced wave-like activity, or almost no activity is observed. Horizontal bar is 5 seconds. Vertical bar is 100  $\mu\text{v}$ . Recording starts during stimulation with 25 Hz. Arrows in different tracings indicate moment when stimulation frequency is changed to new stimulation frequency. A, markedly decreased cavernous electrical activity during stimulation with 25 Hz. resulting in full erection. B, change to 18 Hz. (arrow) did not induce significant changes to cavernous electrical activity and also resulted in full erection. Same response was observed after application of 11 Hz. (double arrows). C, after changing to 8 Hz. (arrow) wave-like cavernous activity together with penile tumescence and incomplete rigidity were noted. D, application of 7 Hz. (arrow) induced little more pronounced cavernous electrical activity and no change in penile response, compared to 8 Hz. E, frequency change to 30 Hz. (arrow) resulted in markedly decreased cavernous electrical activity with full penile erection. F, change to 45 Hz. (arrow) resulted in penile tumescence with almost no rigidity after some seconds. After 20 seconds pronounced wave-like cavernous electrical activity was observed. G, application of 20 Hz. (arrow) induced full erection with markedly decreased cavernous electrical activity. H, change to 7.5 Hz. (arrow) induced wave-like cavernous electrical activity with penile tumescence and incomplete rigidity.

or higher frequencies inducing only an incomplete erectile response.<sup>9</sup>

The anterior roots of S2 contain, besides parasympathetic autonomic fibers, also a minor portion of sympathetic autonomic as well as somatosensory fibers. In regard to autonomic effects, stimulation of the anterior roots of S2 bilaterally seems to activate mainly parasympathetic fibers, since an erection

was induced in all 3 patients. Similarly, Brindley et al induced erection in 26 of 38 patients by neurostimulation of different anterior sacral roots.<sup>8</sup> The activation of the sympathetic fibers does not seem to have an important role, since sympathetic stimulation alone inhibits penile erection.<sup>10,11</sup>

Our findings strongly support the hypothesis that cavernous electrical activity is modulated by the sympathetic and the

parasympathetic systems. In the flaccid state cavernous electrical activity seems to be synchronized by the sympathetic system, resulting in low frequency potentials of high amplitude. Activation of the parasympathetic input induces penile erection with concomitant cavernous electrical activity of high frequency and low amplitude. In showing that cavernous electrical activity is modulated by the cavernous autonomic input, we postulate that alterations of the cavernous autonomic innervation should change the pattern of cavernous electrical activity. This changed pattern of cavernous electric activity should then be diagnosed by single potential analysis of cavernous electrical activity.

#### REFERENCES

1. Wagner, G. and Gerstenberg, T.: Human in vivo studies of electrical activity of corpus cavernosum (EACC). *J. Urol.*, part 2, **139**: 327A, abstract 659, 1988.
2. Wagner, G., Gerstenberg, T. and Levin, R. J.: Electrical activity of corpus cavernosum during flaccidity and erection of the human penis: a new diagnostic method? *J. Urol.*, **142**: 723, 1989.
3. Gerstenberg, T. C., Nordling, J., Hald, H. and Wagner, G.: Standardized evaluation of erectile dysfunction in 95 consecutive patients. *J. Urol.*, **141**: 857, 1989.
4. Lue, T. F., Hricak, H., Marich, K. W. and Tanagho, E. T.: Evaluation of arteriogenic impotence with intracorporal injection of papaverine and the duplex ultrasound scanner. *Sem. Urol.*, **3**: 43, 1985.
5. Saenz de Tejada, S., Goldstein, I. and Krane, R. J.: Local control of penile erection. Nerves, smooth muscle, and endothelium. *Urol. Clin. N. Amer.*, **15**: 9, 1988.
6. de Groat, W. C. and Steers, W. D.: Neuroanatomy and neurophysiology of penile erection. In: *Contemporary Management of Impotence and Infertility*. Edited by E. A. Tanagho, T. F. Lue and R. D. McClure. Baltimore: Williams & Wilkins, chapt. 1, pp. 3-27, 1988.
7. Stief, C. G., Djamilian, M., Schaebsdau, F., Truss, M. C., Schlick, R. W., Abicht, J. H., Allhoff, E. P. and Jonas, U.: Single potential analysis of cavernous electrical activity. A possible diagnosis of autonomic impotence. *World. J. Urol.*, **8**: 75, 1990.
8. Brindley, G. S., Polkey, C. E., Rushton, D. N. and Cardozo, L.: Sacral anterior root stimulators for bladder control in paraplegia: the first 50 cases. *J. Neurol. Neurosurg. Psychiatr.*, **49**: 1104, 1986.
9. Lue, T. F.: Personal communication.
10. Carati, C. J., Creed, K. E. and Keogh, E. J.: Autonomic control of penile erection in the dog. *J. Physiol.*, **384**: 525, 1987.
11. Diederichs, W., Stief, C. G., Benard, F., Bosch, R. J. L. H., Lue, T. F. and Tanagho, E. A.: Sympathetic effect on erection in dogs and monkeys. *J. Urol.*, part 2, **139**: 253A, abstract 361, 1988.