



## Multiple sclerosis and subclinical neuropathology in healthy individuals with familial risk: A scoping review of MRI studies

Matin Mortazavi<sup>a,b,\*</sup>, Öznur Hizarci<sup>a,b</sup>, Lisa Ann Gerdes<sup>d,e</sup>, Joachim Havla<sup>d,f</sup>, Tania Kümpfel<sup>d</sup>, Reinhard Hohlfeld<sup>d,e</sup>, Sophia Stöcklein<sup>a</sup>, Daniel Keeser<sup>a,b</sup>, Birgit Ertl-Wagner<sup>a,c</sup>

<sup>a</sup> Department of Radiology, LMU Klinikum, Munich, Germany

<sup>b</sup> Department of Psychiatry and Psychotherapy, LMU Klinikum, Munich, Germany

<sup>c</sup> Department of Medical Imaging, The Hospital for Sick Children, University of Toronto, Toronto, Ontario, Canada

<sup>d</sup> Institute of Clinical Neuroimmunology, LMU Klinikum, Munich, Germany

<sup>e</sup> Munich Cluster of Systems Neurology, 81377 Munich, Germany

<sup>f</sup> Data Integration for Future Medicine (DIFUTURE) Consortium, Technical University of Munich and Ludwig-Maximilians University, Munich, Germany

### ARTICLE INFO

#### Keywords:

Multiple sclerosis  
Magnetic resonance imaging  
Subclinical pathology  
Familial risk  
Prodromal phase  
Clinical discordance

### ABSTRACT

Multiple genetic and non-heritable factors have been linked to the risk of multiple sclerosis (MS). These factors seem to contribute to disease pathogenesis before the onset of clinical symptoms, as suggested by incidental MRI evidence of subclinical MS neuropathology in individuals without clinical symptoms. Individuals with high familial risk for MS, such as first-degree relatives of patients with MS, can be studied by MRI to characterize the neuropathology during a subclinical period of MS. 16 studies published in English, which performed brain MRI on healthy individuals with high familial risk of MS were included in this scoping review. Studies suggest either no conclusive (5), or inconclusive yet considerable (4), or conclusive evidence (7) for the incidence of subclinical neuropathology, including focal and diffuse tissue damage. Across all studies, white matter lesions fulfilling MS criteria were observed in 86 of 613 individuals (14%). Future research is needed to evaluate the longitudinal dynamics and clinical relevance of preclinical imaging abnormalities in MS.

### 1. Introduction

Multiple sclerosis (MS) is the most prevalent inflammatory disorder of the central nervous system (CNS), which is associated with neuroinflammation and neurodegenerative processes and could result in irreversible and progressive neurological disability and cognitive decline (Compston, 2008; Lassmann et al., 2007, 2012; Thompson et al., 2018a, 2018b). MS is associated with damage to the structural integrity of the brain, including demyelination, manifested through the formation of white matter (WM) lesions, which serve as the hallmark of the disease, diffuse atrophy in the non-demyelinated WM, and damage to grey matter (GM) (Keegan and Noseworthy, 2002; Lassmann et al., 2012; Thompson et al., 2018a, 2018b). Magnetic resonance imaging (MRI) is a mainstay in the diagnosis and monitoring of MS (De Stefano et al., 2014; Filippi et al., 2016; Rocca et al., 2017). The observation of MRI abnormalities even in the earliest clinical stages of the disease and incidental in-vivo or post-mortem findings of WM lesions in individuals without a clinical history of neurological symptoms or MS has led to the notion

that there may be an insidious subclinical period to the disease (Tremlett and Marrie, 2020; Compston, 2008; Dalton et al., 2004; De Stefano et al., 2010, 2014; Fernando et al., 2005; Filippi and Rocca, 2007; Laule et al., 2004; Granberg et al., 2013; Engell, 1989; Okuda et al., 2009). It is important to diagnose MS early for possible early treatment, to potentially prevent irreversible neurological consequences. Longitudinal neuroimaging research has shown a 34% risk for patients with radiologically isolated syndrome (RIS) to convert to clinical manifest MS within 5 years and has provided evidence of an accelerated progression of brain atrophy after the first clinical manifestation of MS (Dalton et al., 2004; Okuda et al., 2009, 2014). Furthermore, numerous clinical trials have shown attenuating effects of early disease-modifying interventions on disability accrual (Thompson et al., 2018a, 2018b; Comi et al., 2009; Goodin et al., 2012; Kappos et al., 2009), underscoring the importance of an early diagnosis.

Identification of individuals with a high susceptibility to develop MS allows a better understanding of the evolution of MS in its early subclinical stages, may help identify triggering factors, and could contribute

\* Corresponding author at: Department of Psychiatry and Psychotherapy, Nussbaumstr. 7, 80336 Munich, Germany.

E-mail address: [M.Mortazavi@med.uni-muenchen.de](mailto:M.Mortazavi@med.uni-muenchen.de) (M. Mortazavi).

<https://doi.org/10.1016/j.nicl.2021.102734>

Received 15 March 2021; Received in revised form 11 May 2021; Accepted 15 June 2021

Available online 18 June 2021

2213-1582/© 2021 The Authors.

Published by Elsevier Inc.

This is an open access article under the CC BY-NC-ND license

(<http://creativecommons.org/licenses/by-nc-nd/4.0/>).

to early therapeutic decision-making. Genome-wide association studies (GWAS) have identified genes that are involved in the risk of developing MS, such as genetic variations within the major histocompatibility complex (MHC) (International Multiple Sclerosis Genetics Consortium, 2019, 2007). In addition, non-heritable environmental factors as well as their interaction with the genes contribute to the risk of MS (Ebers, 2008; Buscarinu et al., 2020). Altogether, familial relatives of patients with MS, especially first-degree relatives, are more susceptible to MS compared to the general population, as they share a great proportion of heritable and non-heritable factors with patients who have already shown clinical manifestation of MS. This is supported by past epidemiological studies, which have shown an increase in the risk of developing MS for first-degree relatives of patients with MS as compared to the general population, an increase which has also been observed in second- and third-degree relatives of patients with MS (Sadovnick et al., 1998). The risk to develop MS is closely related to the degree of relationship, as monozygotic twins have consistently shown higher clinical concordance rates of up to 20%, whereas concordance rates are up to 5% in dizygotic twins, and 1% in non-twin siblings (Sadovnick et al., 1998; O’Gorman et al., 2013; Willer et al., 2003; Westerlind et al., 2014).

The evolution of disease-related traces in preclinical stages of MS and their imaging characteristics, including focal lesions and atrophy, are currently not well elucidated. Healthy individuals with high familial risk of developing MS, namely first-degree relatives of patients with MS, and especially monozygotic and dizygotic co-twins, offer a good model to study the features of such subclinical phases. Our systematic review aimed to summarize prior studies which investigated subclinical neuropathology using MRI in healthy individuals with high familial risk. We aimed to evaluate the incidence and elucidate subclinical neuropathology on MRI. Of note, the use of the term “neuropathology” in this scoping review does not reflect histopathological findings in the nervous system, such as patterns of tissue damage found in biopsies or post-mortem investigations. We use the term to refer to any reported imaging abnormality found in the brain, representing different phenomena ranging from WM neuroinflammatory lesions to signs of tissue atrophy and microstructural damage, as observed using various MRI techniques.

## 2. Methods

We included all English-language research articles that investigated subclinical traces of MS neuropathology using MRI in individuals with high familial risk for MS, which included twin-pairs and first-degree relatives of patients with MS. In order to maximize the range of our search and minimize the chances of missing related reports, various combinations of keywords were used in the PubMed search engine. These word combinations and their corresponding number of results are as follows: (multiple sclerosis[Title/Abstract] AND (twins[Title/Abstract]): 196 results, (multiple sclerosis[Title/Abstract] AND (family [Title/Abstract] AND (imaging[Title/Abstract]): 103 results, (multiple sclerosis[Title/Abstract] AND (relatives[Title/Abstract] AND (imaging[Title/Abstract]): 14 results, (multiple sclerosis[Title/Abstract] AND (relatives[Title/Abstract] AND (mri[Title/Abstract]): 13 results, (multiple sclerosis[Title/Abstract] AND (twins[Title/Abstract] AND (mri[Title/Abstract]): 8 results, (multiple sclerosis[Title/Abstract] AND (twins[Title/Abstract] AND (imaging[Title/Abstract]): 14 results. Altogether, 348 items were filtered manually as follows: 1) the items found included either in their title or abstract the searched word combinations. In the first step of refining the search results, the titles and, when necessary, the displayed summaries of the items were analyzed and the items deemed irrelevant to the topic were excluded. Only in-vivo studies were chosen and post-mortem reports were excluded. 2) The abstract sections of the remaining items were read and analyzed carefully to identify research items with a primary aim of studying the subclinical MRI correlates in healthy individuals at high risk for MS or with secondary aims and / or results in this regards. When in doubt, the full-text of the report was consulted. In case of multiple reports on the

same cohort, the most recent report or the report dedicated to MRI findings of the cohort was selected and reviewed. 3) In addition, the reference lists of the selected reports were analyzed to find studies that were not identified during steps 1 and 2. These steps led to 20 research articles, among which one article was in Spanish and was excluded. The full-length report could not be located for three studies (Lynch et al., 1990; McFarland et al., 1985; Siger-Zajdel et al., 2002) and these were excluded from further analysis (see Fig. 1). The remaining 16 research articles were reviewed and are presented in Table 3 along with their main findings, key characteristics of the investigated cohorts, and MRI techniques and measures used.

The reviewed studies were divided into the following three categories depending on their findings and conclusions on subclinical traces of neuropathology in healthy individuals with high familial susceptibility to MS: 1) no conclusive evidence of subclinical neuropathology, 2) suspicious/inconclusive evidence of subclinical neuropathology, or 3) conclusive evidence of subclinical neuropathology. The studies were assigned to one of these categories solely based on the conclusions made by the authors of each report.

## 3. Results

### 3.1. MRI techniques, measures, and criteria of MS neuropathology

The reviewed studies used different MRI measures extracted from various conventional and non-conventional imaging techniques, using different magnetic field strengths, and applied various MRI criteria to evaluate WM lesions and their dissemination in space and time, depending on the year in which the research was conducted (ranging from years 1985–2019) or on the research question. Table 3 provides a list of imaging details and MRI techniques used in each individual study.

*MRI criteria of MS neuroinflammation and degeneration:* One or more of the following MRI criteria were used in the reviewed studies to evaluate the observed imaging features and classify whether these fit the imaging criteria for MS: Schumacher et al. (1965), Fazekas’s criteria (1988), Paty et al. (1988), Barkhof et al. (1997), 2010 and 2017 McDonald’s criteria (Polman et al., 2011; Thompson et al., 2018a, 2018b), Swanton et al. (2006), Okuda et al. (2009), and the consensus guidelines of MAGNIMS (2016). The preference of one criterion over others was sometimes explained in the report, for instance when evaluating older individuals, in whom the observed WM abnormalities could possibly be attributed to vascular changes. Furthermore, several studies investigated the diagnosis of healthy individuals with radiologically isolated syndrome (RIS), which necessitated the use of specific criteria for this purpose, such as the one of Okuda’s (Okuda et al., 2009).

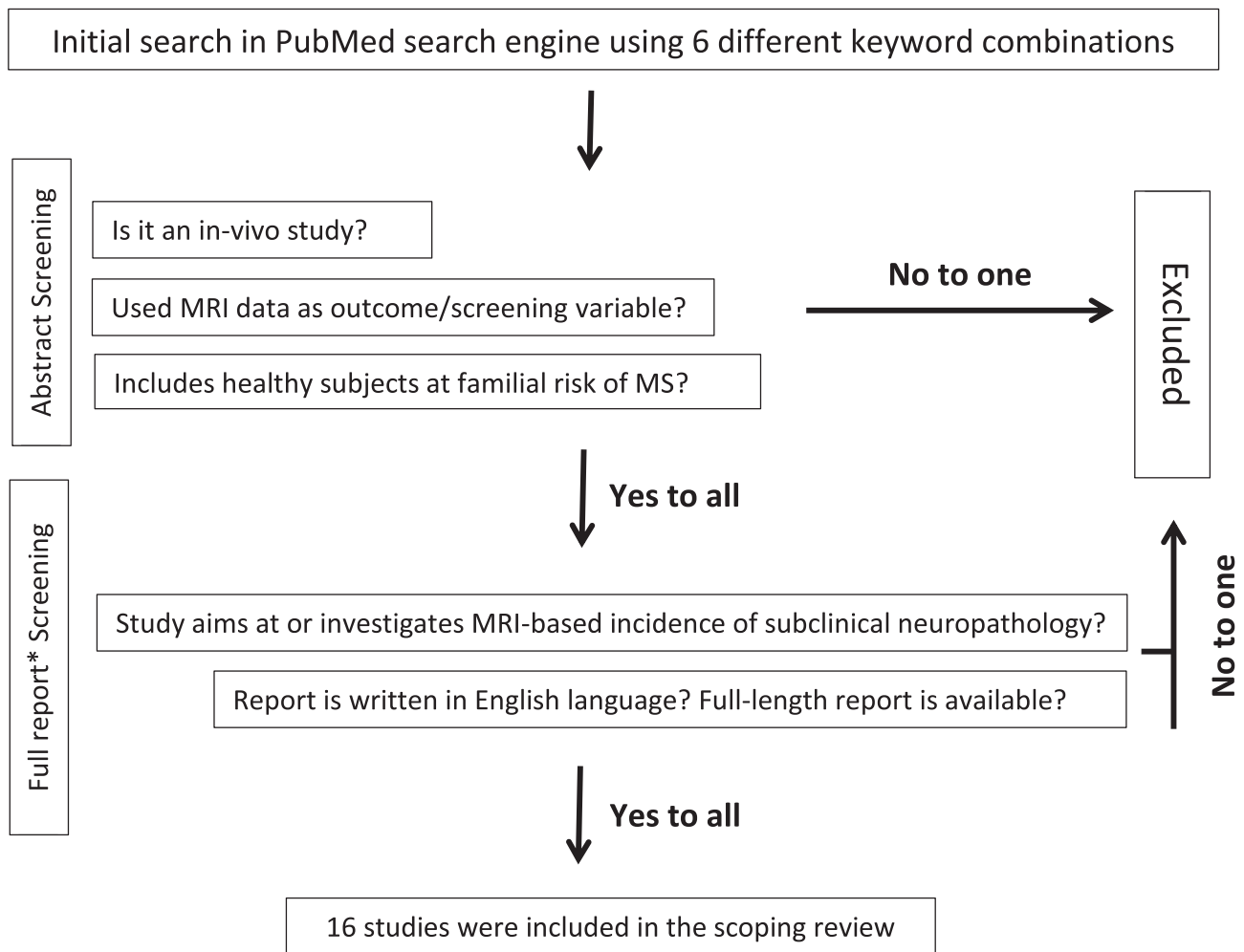
In addition to the evaluation of WM lesions, other quantitative MRI measures and techniques were used, which are briefly described in Table 1.

### 3.2. Findings

Among the 16 reviewed studies, 5 reports showed no conclusive evidence of subclinical neuropathology in healthy individuals with high familial risk of MS. Eleven studies detected evidence of subclinical neuropathology in healthy individuals with high familial risk of MS, among which 4 reports showed suspicious/inconclusive evidence and 7 reports showed conclusive evidence.

#### 3.2.1. No conclusive evidence of subclinical neuropathology

Five studies did not confirm MR imaging signs of subclinical neuropathology in clinically healthy individuals with high familial susceptibility to MS. An older study by Kinnunen et al. (1988) performed MRI in 11 Finish clinically discordant twin-pairs (5 monozygotic (MZ), 6 dizygotic (DZ)). All participants underwent detailed neurological examinations, MR imaging using a very low magnetic field of 0.02 Tesla, and visual evoked potentials (VEP). MR imaging showed WM



**Fig. 1.** Article inclusion flowchart. First, the PubMed search engine was used to look for research reports that included any of our 6 different combinations of keywords, which described our target subject sample and data type (e.g., the combination “multiple sclerosis” AND “relatives” AND “imaging”). The abstract/summary of the initially found papers were screened to only include reports of in-vivo studies which included healthy/asymptomatic individuals at familial risk of MS and also used variables derived from MRI data as one of their main outcomes or screening measures. Then, the full reports of the nominated studies were read and only 16 studies were selected to be included in the review paper. These were studies in English language which aimed at or investigated MRI-based incidence of subclinical neuropathology in healthy subjects with high familial risk of MS.

abnormalities typical of MS in all patients with MS according to the criteria of the Schumacher Committee (Schumacher et al., 1965) and VEP were abnormal for most patients (all except 2). No abnormal MRI or VEP findings were reported for the healthy co-twins. The spatial resolution of the MRI was very limited in this study due to the very low field strength of 0.02 Tesla, which may have led to false negative results. The results therefore need to be interpreted with caution. In another study, the French Research Group on MS (1992) assessed MR imaging and VEP of 13 MZ and 29 DZ twin pairs clinically discordant for MS. MRI of 9 healthy co-twins (3 MZ, 6 DZ) were reported to be indicative of MS according to the criteria of Paty et al (1988), among whom 7 showed signs highly indicative of MS. The VEP recordings showed abnormalities for 3 healthy co-twins (1 MZ, 2 DZ), all of whom had normal MRI scans. The authors reported similar concordance rates for MZ (29%) and DZ (24%) twin pairs which is in contrast to most MS epidemiological studies showing significantly higher concordance rates in MZ twins (for a review: Buscarinu et al., 2020). The study reports all healthy co-twins with abnormal MRI scans suggestive of subclinical MS to be older than 45 years of age and acknowledges the inappropriateness of the criteria they used to evaluate WM MRI lesions in this age group. In light of this explanation, the study concluded no confirmed evidence of subclinical neuropathology in healthy co-twins and ascribes abnormal MRI findings

in these individuals as a possible result of aging.

Filippi and colleagues (1997) used MTR scores in siblings of patients with MS (10 females, 5 males) to investigate possible diffuse damage in NAWM compared to an independent sample of healthy control individuals. Both groups did not have a history of neurological deficits and underwent 1.5 T MRI to investigate MTR scores for NAWM of the entire brain and for specific WM regions (frontal, occipital, and periventricular WM, centrum semiovale, internal capsule, genu and splenium of corpus callosum). The results demonstrated comparable MTR scores between the two groups for the entire brain as well as for the specific WM regions, thus showing no subtle diffuse changes of the WM matter in siblings of patients with MS. In addition, no apparent WM lesions were observed in this group. Filippi et al. (1997) acknowledged the limited spatial resolution and possible lack of sensitivity of the MTR method to detect subclinical changes in the NAWM of siblings. Other studies have demonstrated a lower sensitivity of MTR compared to other MRI sequences, such as DTI or T1 relaxation time measurements, in detecting damages of NAWM (e.g., Vrenken et al., 2006; Guo et al., 2001). A report of concordance rates in continental Italy and Sardinia by Ristori et al. (2006) also investigated potential subclinical MS neuropathology in high-risk asymptomatic individuals among 51 MZ and 174 DZ twin pairs discordant for MS. However, they only performed neurological

**Table 1**  
Imaging techniques and measures used in the reviewed studies and significant findings derived from them.

Imaging technique	Description and imaging measures <sup>(1)</sup>	Reviewed studies using the imaging technique	Significant findings found by reviewed studies using the imaging technique
Conventional MRI sequences: T1-, T2-weighted, FLAIR and Proton Density (PD) imaging	<b>Description:</b> Embedded in routine clinical MRI protocols, <b>Measures:</b> 1) Number, volume, and location of white matter lesions (WM lesions), 2) normal appearing WM (NAWM): WM with no apparent signs of neuroinflammation, 3) Grey matter volume (GMV): consists of cortical GM and sub-cortical GM, 4) non-lesional brain parenchymal volume: NAWM + GM, 5) Dirty appearing WM (DAWM): non-focal area of hyperintensity on the FLAIR/T2w/PD-weighted images, which is brighter than surrounding WM but not as hyperintense as WM lesions, postulated to represent evolving WM lesions or secondary degenerative processes.	All the 19 reviewed studies used one or more conventional imaging methods (often FLAIR, T1- and T2-weighted) and their measures.	-Many subjects showed WM abnormalities. These abnormalities were evaluated using MS MRI criteria (mentioned in section 3.1). Of all 662 cases included in the reviewed studies, 97 subjects (14.7%) had WM MRI lesions compatible with MS, in some cases fulfilling RIS criteria. Thus, WM focal demyelinating lesions seem to be present in a considerable number of healthy individuals with high familial risk of MS. - 3 studies (Kuusisto et al., 2012; De Stefano et al., 2006; Xia et al., 2017) found comparable volumes of NAWM, GM, and parenchymal tissue between healthy individuals at familial risk and an independent healthy cohort. Gabelic et al. (2014) found higher volumes of DAWM in healthy individuals at risk. Measures derived from conventional MRI techniques in the reviewed studies do not seem to provide conclusive evidence about the presence of non-focal, diffuse brain tissue damage in healthy subjects at familial risk for MS.

**Table 1 (continued)**

Imaging technique	Description and imaging measures <sup>(1)</sup>	Reviewed studies using the imaging technique	Significant findings found by reviewed studies using the imaging technique
Diffusion tensor imaging (DTI)	<b>Description:</b> Detects WM abnormalities with more sensitivity compared with conventional sequences and measures (e.g. WM lesions), <b>Measures:</b> fractional anisotropy (FA) and mean diffusivity (MD), both indicate integrity of WM tracts (Higher FA & Lower MD → more intact WM tracts).	-Gabelic et al. (2013)	DTI-derived FA and MD measures, evaluated in the only reviewed study that used DTI to investigate WM tracts more closely, were found to be comparable between healthy relatives of MS patients and an independent healthy cohort.
R2* relaxation rates (1/T2*)	<b>Description:</b> A measure derived from T2* MRI scans, <b>Measure:</b> R2* relaxation rate is a measure closely correlated with certain brain tissue compounds such as iron concentration or myelin content, thus it correlates with focal demyelination as well as diffuse NAWM and GM damage.	Hernandez-Torres et al. (2015)	R2* relaxation rates were found to be increased in healthy siblings of MS patients compared to an independent healthy cohort. This could possibly point towards increased iron levels in the brain, which may play a mediating role in oxidative stress. Increased R2* rates could also indicate increased myelin content in these healthy individuals.
Magnetization transfer ratio (MTR)	<b>Description:</b> Based on principles of magnetization transfer between pools of free and bound water molecules, thus indexing myelin/axonal and neuronal tissue integrity, <b>Measure:</b> A ratio which reflects damage in NAWM and GM prior to the advent of WM lesions, the ratio can also reflect future demyelination or remyelination in WM lesions after formation.	- Filippi et al. (1997) - De Stefano et al. (2006)	Filippi et al. (1997) found no MTR reductions in NAWM of healthy relatives of MS patients. De Stefano et al. (2006) found no MTR irregularities in NAWM, but found MTR reductions in WM lesions found in healthy relatives. MTR findings of reviewed studies are not unanimous, but do not seem to rule out the possibility of brain tissue damage beyond focal WM lesions in healthy individuals with familial risk of MS.

(continued on next page)

Table 1 (continued)

Imaging technique	Description and imaging measures <sup>(1)</sup>	Reviewed studies using the imaging technique	Significant findings found by reviewed studies using the imaging technique
Optical-coherence-tomography (OCT)	<b>Description:</b> An optical imaging technique aimed at determining the thickness of various retinal layers,, especially the nerve fibers entering the brain, to study neuro-axonal degeneration and neuroinflammation, <b>Measure:</b> 1) retinal nerve fiber layer (RNFL) at the levels of parapapillary and macular, the thinning of which is a sign of axonal degeneration, 2) total macular volume (TMV), 3) ganglion cell layer (GCL), 4) inner plexiform layer (INL).	- Gabelic et al. (2013) - Xia et al. (2017)	Both studies using OCT measures found comparable retinal thickness profiles between healthy subjects at familial risk and an independent healthy cohort. Higher WM lesion loads were associated with thinner RNFL and TMV in healthy relatives of MS patients in Gabelic et al. (2013), which could suggest a common underlying pathology in the brain as well as in retinal nerve fibers.

(1): The description of imaging techniques and their measures are based on the following references: Conventional MRI sequences- Filippi et al., 2011; Ge et al., 2003; Rocca et al., 2017; Seewann et al., 2009; DTI - Filippi et al., 2000; Rocca et al., 2000; Rovaris et al., 2005; Tavazzi et al., 2007; R2\* relaxation rates - Stephenson et al., 2014; Gilgun-Sherki et al., 2004; MTR - Enzinger et al., 2015; Filippi and Rocca, 2007; OCT - Petzold et al., 2010, 2017; Balk et al., 2019; Aly et al., 2020.

examinations and MRI of the brain for those 14 “healthy” co-twins (11 MZ, 3 DZ) who self-reported clinical symptoms and observed no findings indicative of clinical MS or subclinical disease. The study concludes that their concordance rates may be artificially low as they did not perform MRI and clinical examinations in the majority of co-twins.

A more recent study by Kuusisto et al. (2012) on a sample of Finnish twins included 7 MZ and 12 DZ (18 females) twin pairs who were clinically discordant for MS. The authors used MR imaging of the brain and spinal cord with various sequences to evaluate the presence of subclinical MS in the clinically unaffected co-twins. The study also compared the overall volume of the brain and spinal cord between patients with MS and their clinically healthy co-twins. Four MZ and five DZ healthy co-twins were found to have focal brain WM lesions, although none of them fulfilled Barkhof’s MRI criteria of MS pathology (Barkhof et al., 1997). Spinal cord imaging detected no lesions in the asymptomatic co-twins. WM lesions in the healthy co-twins were reported to be significantly smaller and less numerous compared to the patients with MS. The volumes of brain and spinal cord were not significantly different between the two groups. All healthy co-twins with WM abnormalities in this study were reported to have either other chronic disorders (e.g., vascular diseases), be above 50 years old, or had excessive alcohol or smoking use, rendering it difficult to attribute the abnormal WM findings to subclinical pathology. The parenchymal volume in patients with MS were comparable to their healthy co-twins, indicating minimal to no brain atrophy in the patient group, is not compatible with the already reported evidence of brain atrophy in patients with MS even in the earliest stages of the disease (De Stefano et al., 2010, 2014).

### 3.2.2. Suspicious evidence of subclinical neuropathology

Several studies provided evidence of suspicious subclinical neuropathology in the CNS of asymptomatic individuals with high familial risk of MS. A study by Uitdehaag et al. (1989) investigated the possibility of subclinical disease in 7 twin-pairs (4 MZ and 3 DZ) who were clinically discordant for MS as well as in one set of MZ triplets with one affected and two clinically healthy co-triplets. The presence of WM lesions was confirmed in T1w and T2w sequences of patients with MS and lesions of similar imaging morphology, although lower in volume, were found in 3 asymptomatic MZ co-twins. The healthy DZ co-twins and the healthy co-twins of the MZ triplet showed no imaging abnormalities. None of the healthy individuals in the study had signs of cortical or subcortical atrophy. All clinically healthy co-twins with WM lesions on MRI were below 45 years of age and had no clinical history of cerebrovascular disorder. A low magnetic field strength of 0.6 Tesla with a limited spatial resolution was used in this study, limiting the detection of small volume WM changes. In a report by Fulton et al. (1999), selected members of three MS multiplex families (i.e., families with multiple MS patients) were studied, among whom one family consisted of an affected mother, father, and son along with another son and one daughter who were both clinically healthy, constituting the only asymptomatic individuals of the sample in this study. All individuals underwent MRI with T1w, T2w, and PD sequences and results showed T2-hyperintense lesions resembling MS lesions in the two healthy family members. Both healthy family members were under the age of 25 years and had no history of cardiovascular disorders. The authors conclude that their findings may be indicative of pre-clinical MS neuropathology in individuals at high familial risk, but that the observed imaging findings may be unspecific.

As the first study of its kind, Gabelic et al. (2013) used DTI and OCT in addition to conventional MRI sequence to investigate subclinical pathology in healthy relatives of MS patients. The number and volume of regions of signal abnormality in WM, the MD and FA indices of DTI, and the RNFL and TMV measures of OCT were compared between 28 asymptomatic first-degree relatives of patients with MS and 40 healthy individuals with no familial risk of MS. 35.7% (10/28) of the relatives of patients with MS and 32.5% (13/40) of the healthy individuals showed signs of MR signal abnormality in their WM similar to MS lesions, detected using a semi-automatic technique with predefined criteria (Zivadinov et al., 2001). Although the proportion of individuals with WM signal abnormalities was higher in the first-degree relatives than the non-relative healthy individuals, this difference remained descriptive and did not reach statistical significance. All DTI and OCT measures were comparable between the two groups. The study demonstrated significant correlations between the lower RNFL and TMV thickness profiles and the higher number and volume of WM abnormalities, which were only present for the healthy relatives of MS patients. Prior studies had demonstrated strong associations between degeneration in RNFL and TMV and higher T2 WM lesion load and brain atrophy in patients with a diagnosis of MS (Siger et al., 2008; Grazioli et al., 2008; Gordon-Lipkin et al., 2007). In a more recent study by Hernandez-Torres and colleagues (2015), the potential presence of microstructural alteration and myelin damage in NAWM of patients with MS, their asymptomatic siblings, and a group of unrelated healthy individuals was investigated using R2\* relaxation rates. The authors used R2\* relaxation rates to detect alterations in myelin architecture and observed lower R2\* rates in patients with MS compared to unrelated healthy controls which was interpreted as indicative of possible loss of myelin and increased water concentrations, consistent with past reports of diffuse damage in non-lesional NAWM of patients with MS from early stages of the disease (Laule et al., 2004; Fernando et al., 2005; De Stefano et al., 2010, 2014). R2\* rates were higher in the group of 31 asymptomatic siblings (including 2 MZ and 8 DZ co-twins) compared to the group of MS patients and to the healthy control group. As a potential explanation, the authors mentioned the increased level of iron in the WM of high risk individuals, which may play a mediating role in oxidative stress.

Previous studies did not show consistent findings in regard to iron levels in early stages of MS, such as in (e.g., [Khalil et al., 2011](#); [Langkammer et al., 2013](#)) and the mere increase of iron levels in the brain has not been established as a risk factor for MS. The study only included healthy individuals with no suspicious WM abnormalities on MRI, thus excluding 3 siblings with focal signal hyperintensities on T2-weighted sequences.

### 3.2.3. Conclusive evidence of subclinical neuropathology

Approximately half (7/16) of the studies that examined signs of subclinical neuropathology in healthy individuals with high familial risk of MS have confirmed the existence of such traces. [Tienari et al. \(1992\)](#) performed detailed neurological examinations and MRI in 17 patients with either clinically definite or probable MS as well as in their 27 healthy siblings, among which 16 participants were younger than 50 years. The authors also used two different MRI criteria of MS pathology, the [Paty et al. criteria \(1988\)](#), which set less stringent requirements meant to be used for individuals under the age of 50 years with low risk for vascular disorders, and the [Fazekas et al. criteria \(1988\)](#) as more stringent criteria for participants older than 50 years old with a higher propensity for neurovascular pathology. All patients with MS showed WM abnormalities on MRI scans, but only 13/17 fulfilled both MRI criteria. Six of the 16 healthy siblings younger than 50 years showed WM lesions on MRI, of whom two fulfilled the Paty criteria, while none met the stricter Fazekas criteria. Eight of the 11 healthy siblings older than 50 years demonstrated WM MRI abnormalities, of whom three fulfilled the Paty criteria and only one fulfilled both criteria. The two younger healthy siblings fulfilling the Paty criteria and the one older healthy sibling fulfilling both criteria were concluded to show definite subclinical signs of MS, while such an assumption was neither confirmed nor rejected for other healthy siblings with WM abnormalities on MRI. This partially inconclusive MRI evidence of MS in some of the healthy high risk individuals and even in 4 patients with clinically established MS could be attributed to the relatively low field strength of 1.0 T and high slice thickness of 5 mm used in the study.

In the British Isles survey of MS in twins, [Thorpe et al. \(1994\)](#) aimed to incorporate MRI findings in the calculation of MS concordance in MZ and DZ twins. 23 MZ and 41 DZ twin pairs clinically discordant for MS underwent detailed neurological examinations and MRI. MS-like lesions were detected in 45% (6/15) of the healthy MZ and 50% (20/40) of the healthy DZ co-twins, of which 3 MZ and 6 DZ individuals fulfilled the stricter Fazekas MRI criteria. The application of these stricter criteria was considered a cautious step towards not over interpreting incidental findings. However, the mean age of both MZ and DZ healthy co-twins was below 45 years and the use of the Fazekas criteria in all the healthy co-twins of this sample may have led to an underestimation in prevalence of subclinical traces of MS among these participants. The presence of subclinical MS in a number of healthy co-twins, even after applying the more stringent Fazekas criteria, increased concordance rates by 10% in the twin-pairs. In a population-based study on Canadian twins, [Eber et al. \(1986\)](#) investigated the clinical concordance of MS and [Sadovnick et al. \(1993\)](#) reported the final results on the clinical and radiological data of this sample in a 7.5 years follow-up study, in addition to investigating a second series of Canadian twins which served as a replication sample. In the original sample, 14% (2/14) of the healthy MZ and 14% (1/7) of the healthy DZ co-twins showed WM lesions that fulfilled the criteria of [Fazekas et al. \(1988\)](#). In the replication sample of twins, 29% (2/7) of the healthy MZ and none of the healthy DZ co-twins (0/4) demonstrated WM lesions fulfilling the Fazekas criteria. The findings were interpreted as evidence for subclinical disease in high risk individuals. The authors suggested they may have underestimated the presence of subclinical MS in the healthy co-twins by applying the stricter Fazekas criteria. Moreover, the healthy DZ co-twins were claimed to be less compliant and thus not many of them received MRI scans, making it again a possible source of underestimation of subclinical MS in the sample. The addition of subclinical MRI

findings to the concordance calculations in both the British and the Canadian twin samples did not significantly increase the concordance rates in MZ or DZ co-twins ([Sadovnick et al., 1993](#); [Thorpe et al., 1994](#)) and the majority of investigated twin-pairs remained clinically and radiologically discordant for MS. Both studies argued this to be indicative of an important contribution of non-heritable factors in the etiology of MS. It is important to note that concordance in twins usually refers to a similarity in the clinical status of the co-twins (i.e., whether both are diagnosed with MS or not). Therefore, the re-calculated concordance rates in the Canadian and British twin populations, after adding findings of healthy co-twins with MRI-traces of subclinical MS pathology, represent a kind of “radiological concordance” rate, and not the classical clinical concordance rates typically calculated in epidemiological studies.

[De Stefano et al. \(2006\)](#) used conventional MRI sequences and MTR to evaluate clinically healthy first degree relatives of familial (88 participants) as well as sporadic (152 participants) patients with MS compared to a group of 56 unrelated healthy controls. Unlike sporadic patients with MS, familial patients belong to families in which at least another individual has been diagnosed with the disorder. The study took advantage of the genetic homogeneity of the Sardinian population, from which the sample was recruited, with its relatively high prevalence of MS ([Granieri et al., 2000](#)). Moreover, the inclusion of first degree relatives of both familial and sporadic patients with MS was meant to further examine the contribution of genetic factors in the possible formation of subclinical disease, with familial MS likely representing a higher genetic disposition to MS than sporadic MS. The presence of WM lesions, their volume, and the normalized parenchymal brain volume were evaluated along with MTR values for NAWM. It was also determined if the observed MRI abnormalities met the Fazekas or Barkhof MRI criteria for MS. WM lesions fulfilling the Fazekas criteria were found in 4.6% of the healthy relatives of sporadic patients with MS (3.9% for Barkhof's criteria), in 11.3% of the healthy relatives of familial patients with MS (10.2% for Barkhof's criteria), and in none of the healthy control individuals representing the general population. The volume of WM abnormalities was significantly higher in relatives of patients with MS as compared to unrelated healthy controls and the lesion burden was only descriptively, but not significantly, higher in healthy relatives of familial compared to sporadic patients with MS. The study reported no differences in normalized parenchymal volume and the MTR values of NAWM between relatives of patients with MS and unrelated healthy controls, while showing significantly decreased MTR values in WM lesions in relatives of patients with MS. These findings indicate the presence of subclinical MS pathology in clinically healthy first degree relatives of patients with MS. The comparable brain volume and MTR of GM and NAWM tissues suggest that subclinical MS pathology could be limited to regions of demyelination and not include diffuse widespread damage to normal appearing brain tissue. This study, however, used a magnetic field strength of 1.0 T and did not employ other advanced imaging methods such as DTI or voxel-based morphometry. Thus, the negative findings in regard to subclinical pathology in NAWM and GM should be interpreted with caution, considering previous evidence of damage observed in normal appearing tissue even in the earliest stages of clinical MS ([Laule et al., 2004](#); [Fernando et al., 2005](#); [De Stefano et al., 2010, 2014](#)). The very low MTR values of lesional tissue shows the high extent of myelin and possibly axonal damage during the formation of subclinical disease in these high risk individuals.

In a later study by [Gabelic et al. \(2014\)](#) extensive investigations were performed to evaluate focal and semi-focal WM abnormalities using a 3 T magnetic field strength in healthy individuals with high familial susceptibility to MS. These were sixty-eight clinically healthy individuals with at least one first degree relative clinically diagnosed with MS and 82 healthy individuals with no familial history of MS, who underwent extensive physical, neurological, and MRI examinations. In addition to assessing the volumes and numbers of MS-like WM abnormalities, every participant was evaluated based on two similar but slightly different

MRI criteria for radiologically isolated syndrome (RIS). Both of these criteria are based on the guidelines suggested by Okuda et al. (2009) to diagnose RIS, while each of them uses a different definition to examine the dissemination of intracranial WM lesions (one follows Barkhof et al. (1997) and the other one follows Swanton et al. (2006)). While the classification by Barkhof et al. is included in the standard guidelines of the Okuda et al. criteria, the Swanton et al. criteria are less stringent to confirm the dissemination of WM lesions in space. Gabelic et al. (2014) also reported a higher prevalence of RIS in healthy relatives of patients with MS using both the Okuda et al. criteria (healthy relatives: 2.9% vs. healthy non-relatives 2.4%) and the more lenient Swanton et al. criteria (healthy relatives: 10.3% vs. healthy non-relatives 3.7%), these differences did not reach statistical significance, though. The study also reported an increased incidence of smoking and obesity in clinically healthy relatives of patients with MS with higher WM lesion loads, but not in healthy participants without first degree relatives with MS. This was discussed to possibly indicate a differential role played by risk factors in the formation of WM abnormality in high risk individuals compared to the general population. Gabelic et al. (2014) also delineated and quantified the volume of DAWM, corresponding to regions of signal abnormality that represent neither WM lesions nor NAWM. There were no significant differences in WM lesion volume or DAWM volume, respectively, between the two groups of clinically healthy individuals. However, when these two indices of WM abnormality were combined, the healthy relatives of patients with MS had significantly higher volumes of WM abnormalities than the healthy individuals with no family history of MS. The only WM areas with significantly higher volumes of signal abnormality in the healthy relatives of patients with MS were the periventricular regions, while juxtacortical, infratentorial, and deep WM regions showed comparable patterns of tissue signal abnormality in the two groups. This may be interpreted as a preferential involvement of periventricular WM in subclinical MS pathology. A propensity of periventricular WM regions to form new WM lesions was described in patients with clinical MS and possibly linked to damage or abnormal permeability in the blood-brain-barrier (Cramer et al., 2014; Sweeney et al., 2018; Varatharaj and Galea, 2017).

Further evidence of subclinical neuropathology in healthy individuals with high MS risk stems from the Genes and Environment in Multiple Sclerosis (GEMS) project (Xia et al., 2016, 2017). In this ongoing project, healthy first-degree relatives of patients with MS, who were younger than 50 years, were each given an aggregate MS susceptibility risk score, which took into account all known cardinal genetic and environmental MS risk factors. In their most recent study (Xia et al., 2017), healthy females younger than 50 years with at least one first-degree relative with MS were recruited and underwent detailed neurological examinations as well as MRI and OCT. Two sub-groups were formed each representing the 10% highest (40 individuals) and 10% lowest (25 individuals) possible MS susceptibility scores, allowing the objective investigation of subclinical MS pathology in healthy individuals of lower and higher risks using a precise susceptibility criteria. A previous report from this project had shown their susceptibility score to be more informative of MS risk than the family history alone, with individuals in the upper strata of the risk score distribution having the greatest probability of having clinical MS (Xia et al., 2016). The study reviewed here (Xia et al., 2017) included only females in order to avoid a confounding role of sex, since females dominated the sub-group with the highest susceptibility scores and female sex was used as a risk factor to determine the susceptibility scores and has been shown to be generally more prone to develop clinical MS (Ebers, 2008; Ramagopalan et al., 2010; Xia et al., 2016). WM abnormalities of 5 participants (4 with higher and 1 with lower risk scores) fulfilled the 2010 McDonald MRI criteria (Polman et al., 2011), three participants (two with higher risk scores) fulfilled the MAGNIMS 2016 consensus MRI criteria for MS diagnosis (Filippi et al., 2016), and two participants (one with higher risk) met the requirements for RIS according to Okuda et al. (2009). There were no statistically significant differences between participants

with higher and lower risk scores, though. Moreover, all other MRI measures of normalized brain volume, volume of GM, WM, and thalamus as well as the RNFL and TMV thickness profiles derived from OCT were comparable between the two groups. Nevertheless, 40% of the T2-hyperintense WM lesions in 14 individuals had a *peri-venous* appearance, a pattern which was significantly more common in higher risk (12 individuals) than in lower risk (2 individuals) individuals. Spinal cord imaging detected a focal upper cervical lesion in one of these 14 individuals. Such a *peri-venous* lesion appearance has been described to differentiate MS lesions from WM lesions attributed to other underlying causes (Solomon et al., 2016; Tallantyre et al., 2011). In addition, Xia et al. observed a significantly impaired vibration perception in higher risk as compared to lower risk individuals, which could represent a subtle subclinical neurological dysfunction. The study was concluded to offer neurological and radiological evidence of subclinical signs of MS in healthy individuals at higher risk of developing MS. The study did not provide evidence, however, of more diffuse neurodegeneration in these individuals which was attributed to the potentially underpowered nature of the study and to the measures, which may not be sensitive enough to detect more subtle changes in clinically healthy individuals.

Another finding of subclinical MS neuropathology in high risk healthy individuals comes from the German MS TWIN STUDY (Beltrán et al., 2019). This study included a large sample of MZ twins who are clinically discordant for MS and examined a subset of twin-pairs and healthy co-twins who had undergone CSF analysis to identify potential cellular CSF markers of prodromal stages of MS. WM lesions similar to MS-typical demyelinating lesions were found in 6 of 8 healthy MZ co-twins of patients with MS, among whom two fulfilled the RIS criteria for dissemination in space (De Stefano et al., 2018), and two expressed oligoclonal bands (OCB) in their CSF analysis. Although two healthy co-twins did not show any signs of neuroinflammation, the MRI observations in the other healthy co-twins were interpreted as evidence of subclinical neuroinflammation in healthy individuals with high familial risk of developing MS. Subclinical neuroinflammation in these clinically healthy co-twins was associated with the presence of expanded and activated CD8 + T immune cells in the CSF profiles, which supports the assumption that the observed WM lesions in the high risk healthy co-twins are related to neuroinflammatory processes in early subclinical stages of MS.

#### 4. Discussion

Subclinical MRI traces of MS neuropathology can generally be investigated based on an individual's familial risk or regional susceptibility to MS. These investigations are complementary to the concept of RIS, which is usually discovered by chance. This systematic review included the available English-language publications to-date which investigated asymptomatic individuals with familial risk of MS, including first-degree relatives or individuals with the highest possible familial risk, namely co-twins of patients with MS, for MRI-based traces of subclinical neuropathology in the brain. The overall aims were to evaluate the incidence of subclinical MS pathology in these highly susceptible individuals, which could suggest a subclinical prodromal stage of the disease, and to characterize this clinically silent neuropathology.

Of the 16 studies conducted on the matter and reviewed here, 5 studies found suspicious and 9 studies conclusive evidence of MS neuropathology, which may mark the beginning of a subclinical period of MS in individuals who are susceptible to developing the disease, but are otherwise clinically healthy and asymptomatic. Table 3 summarizes the main outcomes of every study and provides the total number of individuals included along with the frequency of those who showed WM lesions indicative of MS neuropathology, as determined by the fulfillment of various MRI criteria of MS or RIS. 14% (86 out of 613) of the healthy individuals with high familial risk included in all the reviewed studies were found to have WM lesions on MRI compatible with MS neuropathology (see Table 2 for a demographics summary of the

**Table 2**

Summary of main demographic features of all healthy individuals with high familial risk for MS who were included in the 16 reviewed studies.

Non-twin first degree relatives				
Approximate Mean Age <sup>1</sup>	Gender distribution (F:M ratio) <sup>2</sup>	Known number of parents/children <sup>3</sup>	Known number of siblings <sup>3</sup>	Total First degree relatives <sup>3</sup>
39.92 years	1.66:1	0	65	397
Twins				
Approximate Mean Age <sup>1</sup>	Gender distribution (F:M ratio) <sup>2</sup>	Number of monozygotic co-twins	Number of dizygotic co-twins	
43.15 years	1.90:1	96	120	

(1): The mean age shown here is a sample size-weighted mean of the reviewed studies in which the mean age of the sample was mentioned. This information was missing in 3 of the 16 reviewed studies, (2): 2 studies did not provide gender distribution details and were thus not included in the female to male ratio here, (3): Total number of first degree relatives were always mentioned by the studies and the figure here shows the sum of all relatives included in the 16 reviewed studies. Known number of parents/children or siblings in the table are the sum of these numbers when these were specified in the reviewed studies.

cohorts). There were numerous additional individuals with WM abnormalities on MRI who did not fulfill the various MRI criteria of MS or RIS. Moreover, a few studies used imaging measures other than WM lesions as their main outcomes (MTR values, R2\* relaxation rates, DTI and OCT measures), some of which demonstrated changes indicative of diffuse subclinical pathology in NAWM and GM of healthy co-twins or first-degree relatives of patients with MS. The number of past research reports highly suggesting or confirming the incidence of subclinical MS neuropathology in healthy individuals with familial risk and the total rate of this incidence among these individuals are indicative of the significance of the topic. Overall, these findings support the notion that the advent of MS neuropathology in the brain entails a subclinical period (Tremlett and Marrie, 2020). The early diagnosis of MS subclinical neuropathology could contribute to preemptive therapeutic strategies. Of the 5 studies in which no evidence of subclinical neuroinflammation was found, three had used MRI scanners with unknown or very low magnetic field strengths and 4 used sample sizes with less than 15 individuals. In addition to these studies showing no evidence of subclinical MS neuropathology, many healthy individuals with high familial risk of MS in the other studies also did not show significant signs of MS and thus did not differ from the rest of the healthy general population. These findings emphasize the complexity of MS pathophysiology and highlight again the important role that non-heritable environmental factors play in the etiology of MS neuropathology.

The most commonly investigated marker of MS neuropathology in the reviewed studies was the presence, number, and/or volume of WM lesions. Most studies used conventional MRI sequence techniques and employed various older and more recent classification criteria to examine the extent to which the lesions represent MS-specific pathology. Almost all studies showing suspicious or confirmed imaging evidence of subclinical MS neuropathology demonstrated WM lesions in healthy individuals with high familial risk. Beside WM lesions, many of the reviewed studies also used other MRI measures derived from various imaging techniques to evaluate MS-related tissue abnormalities. While findings coming from three studies (Kuusisto et al., 2012; De Stefano et al., 2006; Xia et al., 2017) using conventional MRI sequences, two of which used lower magnetic field strengths ( $\leq 1.5$  Tesla), showed no significant abnormalities in NAWM, GM, and parenchymal tissue in healthy individuals with higher familial risk of MS, one study (Gabelic et al., 2014) presented evidence of higher diffuse WM abnormalities in these individuals compared to a control healthy cohort. Most of the reviewed studies using only conventional MRI techniques suggest that subclinical MS neuropathology may potentially be limited to focal WM

lesions, while more diffuse changes and secondary neurodegeneration appear only in the later stages of the disease. This is reinforced when incorporating the results reported by Gabelic et al. (2013), who used DTI, a method known to be more sensitive to WM abnormalities compared to conventional MRI sequences, and showed normal global integrity of WM tracts in healthy relatives of patients with MS. However, another study (Filippi et al., 1997) using MTR, a technique evidenced to reflect diffuse damage in brain tissue before the advent of focal lesions, found no MTR abnormalities in NAWM of healthy relatives of patients with MS. De Stefano et al. (2006) used MTR and demonstrated no damage in NAWM of relatives of patients with MS, but showed significant MTR reductions in WM focal lesions in this group. The notion that subclinical tissue abnormalities in healthy relatives of patients with MS is limited to focal WM lesions is further challenged by Hernandez-Torres et al. (2015), who used R2\* relaxation rates and suggested an increase in cerebral iron levels in healthy siblings of patients with MS, a phenomenon which might play a mediating role in increased oxidative stress. Furthermore, even though reviewed findings from OCT imaging (Gabelic et al., 2013; Xia et al., 2017) showed comparable retinal thickness profiles between healthy individuals with high familial risk and healthy control cohorts, one study (Gabelic et al., 2013) pointed towards a common underlying pathology in brain and retinal nerve fibers in high risk individuals. While findings from most reviewed studies with conclusive or suspicious evidence of subclinical MS neuropathology suggest WM focal lesions as the main type of such neuropathology, a few studies suggest that this subclinical neuropathology might also include NAWM and GM tissue abnormalities. The latter is congruent with evidence from the literature showing focal as well as widespread pathology in all MS clinical phenotypes, also in the earliest clinical stages of the disease (Compston, 2008; Dalton et al., 2004; De Stefano et al., 2010, 2014; Fernando et al., 2005; Filippi and Rocca, 2007; Laule et al., 2004). In summary, the findings on the nature of subclinical neuropathology in healthy individuals with high familial risk are not unanimous and point to different directions. Further studies with larger sample sizes, higher imaging resolution, more extensive imaging protocols, and more objective measures of MS risk are needed to shed light on different features of subclinical neuropathology in early clinically silent stages of MS.

There are several important limitations in many of the reviewed studies, which include: 1) small sample sizes and commonly a lack of a priori sample size calculations, 2) a lack of quantitative MS risk scores in healthy individuals based on the known genetic and environmental risk factors, as it was done in the GEMS project (Xia et al., 2016, 2017), 3) limited MR imaging protocols, with limited spatial resolution and relatively low field strengths, 4) the reviewed studies do not report follow-up screenings of healthy individuals presenting confirmed MRI-traces of MS to investigate conversion to clinical disease. A longitudinal approach in healthy individuals at high familial risk of MS is of benefit in future studies. A further limitation of our scoping review is that the included publication used different criteria for MS lesions, which reflected the time when the study was performed and sometimes the characteristics of the sample, e.g., age. Most of the reviewed studies have not incorporated MRI criteria for RIS when evaluating tissue abnormalities compatible with MS lesions. A consensus by MAGNIMS (De Stefano et al., 2018) recommends the use of MRI criteria for RIS when evaluating MRI abnormalities resembling those of MS in asymptomatic individuals, in order to distinguish between incidentals MRI signs related to MS from those of other disorders. Incorporating the MRI criteria for RIS is, thus, an important element of any future studies looking at asymptomatic individuals with high familial risk of MS. It is worth noting that no study to-date has systematically investigated functional MRI (fMRI) abnormalities in healthy individuals with high familial risk of MS. Finally, since the MRI criteria for MS applied in the reviewed studies use various differing descriptions and requirements to evaluate brain WM lesions, the retrieval and re-analyses of the MRI data from all these studies using the most recent criteria could be of great value.



**Table 3**

Studies investigating subclinical MS neuropathology using brain MRI in healthy subjects with high familial risk (listed here in the same order as mentioned in the results section).

Study	Sample's Gender/Age <sup>+</sup>	High familial risk healthy subjects recruited	MRI techniques + other methods used	MRI magnetic field's strength	Main findings	Conclusion on subclinical MS neuropathology	Journal
Kinnunen et al. (1988)	14F, 8 M/29-59yrs	5 MZ and 6 DZ co-twins	Conventional MRI sequences + VEP	0.02 Tesla	- No WM abnormalities in the healthy co-twins	No conclusive evidence	Archives of neurology
French Research Group on MS (1992)	F:M ratio was 2.2:1/Mean age = 42.2yrs	13 MZ and 29 DZ co-twins	Conventional MRI sequences + VEP	Not mentioned	-3 MZ and 6 DZ healthy co-twins showed WM lesions indicative of MS. 7 of these had lesions highly indicative of MS. -3 healthy co-twins had abnormal VEP patterns.	No conclusive evidence	Annals of Neurology
Filippi et al. (1997)	10F, 5 M/ Mean age = 31.7yrs	15 siblings	-MTR -Conventional MRI sequences	1.5 Tesla	-No MTR reduction in NAWM of siblings -No apparent WM lesions for siblings	No conclusive evidence	Journal of the neurological sciences
Ristori et al. (2006)	F:M ratio was 1.84/ Mean age = 41.3yrs	11 MZ and 3 DZ healthy co-twins with self-report of slight clinical symptoms	Conventional MRI sequences	Not mentioned	-No WM abnormalities were found	No conclusive evidence	Annals of neurology
Kuusisto et al. (2012)	26F, 12 M/Age range = 30-66yrs	7 MZ and 12 DZ co-twins	Conventional MRI sequences	1.5 Tesla	- 9 co-twins showed WM abnormalities, but did not fulfill any criteria - Comparable brain parenchymal volume between patients and healthy co-twins.	No conclusive evidence	Medicina
Uitdehaag et al. (1989)	7F, 2 M/ Mean age = 40.33yrs	6 MZ and 3 DZ co-twins	Conventional MRI sequences	0.6 Tesla	-3 MZ co-twins showed MS-like WM abnormalities -No central or cortical atrophy was observed	Suspicious evidence of MS neuropathology	Journal of Neurology, Neurosurgery & Psychiatry
Fulton et al. (1999)	1F, 1 M/ Under 25yrs old	1 son and 1 daughter of a MS multiplex family	Conventional MRI sequences	1.5 Tesla	-WM hyperintensities similar to MS WM lesions in the healthy subjects	Suspicious evidence of MS neuropathology	Multiple Sclerosis Journal
Gabelic et al. (2013)	19F, 9 M/ Mean age = 35yrs	28 first-degree relatives of MS patients	- Conventional MRI sequences -DTI + OCT	3 Tesla	-Comparable OCT thickness profiles and DTI indexes of WM integrity between relatives and control healthy subjects -Strong correlations between decreased RNFL and TMV thickness and volume of WM lesions only in the healthy relatives	Suspicious evidence of MS neuropathology	Clinical neurology and neurosurgery
Hernandez-Torres et al. (2015)	20F, 11 M/ Mean age = 50.6yrs	-2 MZ and 8 DZ co-twins -21 singleton siblings	-Conventional MRI sequences- R2* relaxation rates	3 Tesla	-Increased R2* rates in healthy siblings of MS patients, indicating possible increase of brain's iron levels -WM abnormalities suspicious of MS in 3 siblings	Suspicious evidence of MS neuropathology	PloS one
Sadovnick et al. (1993), a follow-up of the Eber et al. (1986)	Unknown gender distribution /Mean age = 46.27yrs	21 MZ and 18 DZ co-twins	Conventional MRI sequences	Multiple scanners used depending on the geographical proximity to twins. Magnetic field strengths are not mentioned.	-19% of MZ and 9% of DZ co-twins showed WM lesions fulfilling MRI criteria of MS lesions	Conclusive evidence of subclinical neuropathology	Annals of neurology
Tienari et al. (1992)	Unknown gender distribution/ Mean age = 46.33yrs	27 siblings of MS patients	Conventional MRI sequences	1 Tesla	-WM lesions indicative of MS pathology in 2 younger siblings and 1 older sibling	Conclusive evidence of subclinical neuropathology	Journal of Neurology, Neurosurgery & Psychiatry
Thorpe et al. (1994)	38F, 26 M/ Mean age = 41.86yrs	23 MZ and 41 DZ co-twins	Conventional MRI sequences	Multiple scanners used:24 subjects with 0.5 Tesla, 34 with 1.5 Tesla, 2 with 0.15	-MS-like lesions in 45% of MZ and 50% of DZ twins -14.5% of co-twins had WM lesions fulfilling strict MRI MS criteria	Conclusive evidence of subclinical neuropathology	Journal of Neurology, Neurosurgery & Psychiatry

(continued on next page)

Table 3 (continued)

Study	Sample's Gender/Age <sup>+</sup>	High familial risk healthy subjects recruited	MRI techniques + other methods used	MRI magnetic field's strength	Main findings	Conclusion on subclinical MS neuropathology	Journal
De Stefano et al. (2006)	- 38F, 50 M/ Mean age = 42yrs - 82F, 70 M/ Mean age = 40yrs	-88 first degree relatives of familial MS patients -152 first degree relatives of sporadic MS patients	-MTR- Conventional MRI sequences	Tesla, and 4 with 0.5 Tesla. 1 Tesla	-3.9% and 10.2% of healthy relatives of sporadic and familial MS patients, respectively, have WM lesions fulfilling multiple MS criteria. -Significantly higher WM lesions in relatives compared to control sample -Comparable parenchymal volume and MTR values of NAWM between relatives and control sample -significantly decreased MTR values in MS lesions of relatives	Conclusive evidence of subclinical neuropathology	Annals of Neurology
Gabelic et al. (2014)	45F, 23 M/ Mean age = 39.5yrs	68 first degree relatives of MS patients	Conventional MRI sequences	3 Tesla	-Higher volumes of WM lesions and DAWM combined in the relatives, especially in the periventricular WM regions. -More incidence of RIS in relatives compared to the general population (statistically not significant)	Conclusive evidence of subclinical neuropathology	American Journal of Neuroradiology
Xia et al. (2017) (The GEMS project)	65F, 0 M/ Mean age = 35.1yrs	40 high risk and 25 low risk first degree female relatives of MS patients	Conventional MRI sequences+ OCT	3 Tesla	-Multiple high and low risk relatives (>5) showed WM lesions fulfilling various MRI criteria of MS pathology and RIS. -Comparable brain volume, WM, GM, thalamic volume, and RNFL and TMV thickness profiles between relatives and the control sample -WM lesions with <i>perivenous</i> morphology in relatives and more commonly in relatives with higher risk. -Significantly reduced sense of vibration in relatives with higher risk of MS.	Conclusive evidence of subclinical neuropathology	JAMA neurology
Beltrán et al. (2019) (The German MS TWINS Study)	7F, 1 M/ Mean age = 40.38yrs	8 MZ co-twins	Conventional MRI sequences - DTI (to evaluate WM lesions)	3 Tesla	-WM lesions similar to MS pathology in 6 co-twins, 2 of whom fulfilled RIS criteria. -CD8 + T cells in the CSF puncture of co-twins with confirmed MS lesions	Conclusive evidence of subclinical neuropathology	Journal of Clinical Investigation,

(F): Female, (M): Male, (MZ): Monozygotic, (DZ): Dizygotic, (yrs): Years, (WM): white matter, (GM): grey matter, (NAWM): normal appearing white matter, (RIS): radiologically isolated syndrome, (DAWM): dirty appearing white matter, (MTR): magnetization transfer ratio, (OCT): ocular coherence tomography, (RNFL): retinal nerve fiber layer, (TMV): total macular volume, (DTI): diffusion tensor imaging, (CSF): cerebrospinal fluid, (VEP): visual evoked potential, (+) This column describes the gender/age distribution for the high familial risk subjects included in the study when this information was provided by the authors, when not, the gender/age distribution of the entire study's sample was described here.

## 5. Conclusion

Past research on the incidence of MRI-based subclinical MS neuropathology in healthy individuals with high familial risk has shown differing results. The majority of studies points toward a higher prevalence of subclinical MS neuropathology in MRI examinations of healthy individuals with high familial risk. This may correspond to a prodromal stage of the disease in these highly susceptible individuals. Focal WM

lesions have been demonstrated in the majority of studies, while some studies have reported evidence of non-focal diffuse tissue damage. Investigating subclinical MS neuropathology in healthy individuals with high familial risk helps characterizing the subclinical stages of the disease, which contributes to the better understanding of the pathophysiology of MS and factors associated with neuroprotection or clinical manifestation of the disease. It could also improve clinical management in these highly susceptible individuals and consequently lead to better

prognosis. Further studies are needed to clarify the prevalence and nature of such a potential prodromal stage.

### Authorship note

M.M. and Ö.H. are co-first authors and D.K. and B.E. are co-last authors.

### Funding

Matin Mortazavi is supported by a PhD stipend from the Avicenna-Studienwerk. Lisa Ann Gerdes and Reinhard Hohlfeld are supported by the Munich Cluster for Systems Neurology (SyNergy EXC 2145, project 390857198). Joachim Havla is (partially) funded by the German Federal Ministry of Education and Research under 01ZZ1603[A-D] and 01ZZ1804[A-H] (DIFUTURE).

### Declaration of Competing Interest

The authors declare that they have no known competing financial interests or personal relationships that could have appeared to influence the work reported in this paper.

### Acknowledgment

This work is part of the PhD work of M.M. and O.H. We would like to thank Ms. Köstler for her help with proofreading the paper and language editing.

### References

- Aly, L., Havla, J., Lepennetier, G., Andlauer, T.F., Sie, C., Strauß, E.M., Mühlau, M., 2020. Inner retinal layer thinning in radiologically isolated syndrome predicts conversion to multiple sclerosis. *European Journal of Neurology*.
- L.J. Balk D. Coric B. Knier H.G. Zimmermann R. Behbehani R. Alroughani P. Albrecht Retinal inner nuclear layer volume reflects inflammatory disease activity in multiple sclerosis; a longitudinal OCT study *Multiple Sclerosis Journal-Experimental, Translational and Clinical* 5 3 2019 2055217319871582.
- Barkhof, F., Filippi, M., Miller, D.H., Scheltens, P., Campi, A., Polman, C.H., Valk, J., 1997. Comparison of MRI criteria at first presentation to predict conversion to clinically definite multiple sclerosis. *Brain: a journal of neurology* 120 (11), 2059–2069.
- Beltrán, E., Gerdes, L.A., Hansen, J., Flierl-Hecht, A., Krebs, S., Blum, H., Dornmair, K., 2019. Early adaptive immune activation detected in MZ twins with prodromal multiple sclerosis. *Journal of Clinical Investigation* 129 (11), 4758–4768.
- Buscarinu, M.C., Fornasiero, A., Ferraldeschi, M., Romano, S., Reniè, R., Morena, E., Salvetti, M., 2020. Disentangling the molecular mechanisms of multiple sclerosis: The contribution of twin studies. *Neuroscience & Biobehavioral Reviews*.
- Comi, G., Martinelli, V., Rodegher, M., Moiola, L., Bajenaru, O., Carra, A., King, J., 2009. Effect of glatiramer acetate on conversion to clinically definite multiple sclerosis in patients with clinically isolated syndrome (PreCISe study): a randomised, double-blind, placebo-controlled trial. *The Lancet* 374 (9700), 1503–1511.
- Compston, A., 2008. Coles. *Multiple sclerosis*. *Lancet* 372, 1502–1517.
- Cramer, S.P., Simonsen, H., Frederiksen, J.L., Rostrup, E., Larsson, H.B.W., 2014. Abnormal blood–brain barrier permeability in normal appearing white matter in multiple sclerosis investigated by MRI. *NeuroImage: Clinical* 4, 182–189.
- Dalton, C.M., Chard, D.T., Davies, G.R., Miszkil, K.A., Altmann, D.R., Fernando, K., Miller, D.H., 2004. Early development of multiple sclerosis is associated with progressive grey matter atrophy in patients presenting with clinically isolated syndromes. *Brain* 127 (5), 1101–1107.
- De Stefano, N., Airas, L., Grigoriadis, N., Mattle, H.P., O’Riordan, J., Oreja-Guevara, C., Kieseier, B.C., 2014. Clinical relevance of brain volume measures in multiple sclerosis. *CNS drugs* 28 (2), 147–156.
- De Stefano, N., Cocco, E., Lai, M., Battaglini, M., Spissu, A., Marchi, P., Federico, A., 2006. Imaging brain damage in first-degree relatives of sporadic and familial multiple sclerosis. *Annals of Neurology: Official Journal of the American Neurological Association and the Child Neurology Society* 59 (4), 634–639.
- De Stefano, N., Giorgio, A., Battaglini, M., Rovaris, M., Sormani, M.P., Barkhof, F., Dinacci, D., 2010. Assessing brain atrophy rates in a large population of untreated multiple sclerosis subtypes. *Neurology* 74 (23), 1868–1876.
- De Stefano, N., Giorgio, A., Tintorè, M., Pia Amato, M., Kappos, L., Palace, J., Frederiksen, J., 2018. Radiologically isolated syndrome or subclinical multiple sclerosis: MAGNIMS consensus recommendations. *Multiple Sclerosis Journal* 24 (2), 214–221.
- Ebers, G.C., 2008. Environmental factors and multiple sclerosis. *The Lancet Neurology* 7 (3), 268–277.
- Ebers, G.C., Bulman, D.E., Sadovnick, A.D., Paty, D.W., Warren, S., Hader, W., Nelson, R., 1986. A population-based study of multiple sclerosis in twins. *New England Journal of Medicine* 315 (26), 1638–1642.
- Engell, T., 1989. A clinical patho-anatomical study of clinically silent multiple sclerosis. *Acta neurologica scandinavica* 79 (5), 428–430.
- Enzinger, C., Barkhof, F., Ciccarelli, O., Filippi, M., Kappos, L., Rocca, M.A., Vrenken, H., 2015. Nonconventional MRI and microstructural cerebral changes in multiple sclerosis. *Nature Reviews Neurology* 11 (12), 676.
- Fazekas, F., Offenbacher, H., Fuchs, S., Schmidt, R., Niederkorn, K., Horner, S., Lechner, H., 1988. Criteria for an increased specificity of MRI interpretation in elderly subjects with suspected multiple sclerosis. *Neurology* 38 (12), 1822.
- Fernando, K.T.M., Tozer, D.J., Miszkil, K.A., Gordon, R.M., Swanton, J.K., Dalton, C.M., Miller, D.H., 2005. Magnetization transfer histograms in clinically isolated syndromes suggestive of multiple sclerosis. *Brain* 128 (12), 2911–2925.
- Filippi, M., Rocca, M.A., 2007. Magnetization transfer magnetic resonance imaging of the brain, spinal cord, and optic nerve. *Neurotherapeutics* 4 (3), 401–413.
- Filippi, M., Campi, A., Martino, G., Colombo, B., Comi, G., 1997. A magnetization transfer study of white matter in siblings of multiple sclerosis patients. *Journal of the neurological sciences* 147 (2), 151–153.
- Filippi, M., Iannucci, G., Cercignani, M., Rocca, M.A., Pratesi, A., Comi, G., 2000. A quantitative study of water diffusion in multiple sclerosis lesions and normal-appearing white matter using echo-planar imaging. *Archives of neurology* 57 (7), 1017–1021.
- Filippi, M., Rocca, M.A., Ciccarelli, O., De Stefano, N., Evangelou, N., Kappos, L., Gasperini, C., 2016. MRI criteria for the diagnosis of multiple sclerosis: MAGNIMS consensus guidelines. *The Lancet Neurology* 15 (3), 292–303.
- Filippi, M., Rocca, M.A., De Stefano, N., Enzinger, C., Fisher, E., Horsfield, M.A., Comi, G., 2011. Magnetic resonance techniques in multiple sclerosis: the present and the future. *Archives of neurology* 68 (12), 1514–1520.
- French Research Group on Multiple Sclerosis, 1992. Multiple sclerosis in 54 twinships: concordance rate is independent of zygosity. *Annals of Neurology* 32 (6), 724–727.
- Fulton, J.C., Grossman, R.I., Mannon, L.J., Udupa, J., Kolson, D.L., 1999. Familial multiple sclerosis: volumetric assessment in clinically symptomatic and asymptomatic individuals. *Multiple Sclerosis Journal* 5 (2), 74–77.
- Gabelic, T., Ramasamy, D.P., Weinstock-Guttman, B., Hagemeyer, J., Kennedy, C., Melia, R., Zivadinov, R., 2014. Prevalence of radiologically isolated syndrome and white matter signal abnormalities in healthy relatives of patients with multiple sclerosis. *American Journal of Neuroradiology* 35 (1), 106–112.
- Gabelic, T., Weinstock-Guttman, B., Melia, R., Lincoff, N., Masud, M.W., Kennedy, C., Ramanathan, M., 2013. Retinal nerve fiber thickness and MRI white matter abnormalities in healthy relatives of multiple sclerosis patients. *Clinical neurology and neurosurgery* 115, S49–S54.
- Ge, Y., Grossman, R.I., Babb, J.S., He, J., Mannon, L.J., 2003. Dirty-appearing white matter in multiple sclerosis: volumetric MR imaging and magnetization transfer ratio histogram analysis. *American Journal of Neuroradiology* 24 (10), 1935–1940.
- Gilgun-Sherki, Y., Melamed, E., Offen, D., 2004. The role of oxidative stress in the pathogenesis of multiple sclerosis: the need for effective antioxidant therapy. *Journal of neurology* 251 (3), 261–268.
- Goodin, D.S., Reder, A.T., Ebers, G.C., Cutter, G., Kremenchutzky, M., Oger, J., Knappertz, V., 2012. Survival in MS: a randomized cohort study 21 years after the start of the pivotal IFNβ-1b trial. *Neurology* 78 (17), 1315–1322.
- Gordon-Lipkin, E., Chodkowski, B., Reich, D.S., Smith, S.A., Pulicken, M., Balcer, L.J., Calabresi, P.A., 2007. Retinal nerve fiber layer is associated with brain atrophy in multiple sclerosis. *Neurology* 69 (16), 1603–1609.
- Granberg, T., Martola, J., Kristoffersen-Wiberg, M., Aspelin, P., Fredrikson, S., 2013. Radiologically isolated syndrome—incidental magnetic resonance imaging findings suggestive of multiple sclerosis, a systematic review. *Multiple Sclerosis Journal* 19 (3), 271–280.
- Granieri, E., Casetta, I., Govoni, V., Tola, M.R., Marchi, D., Murgia, S.B., Rosati, G., 2000. The increasing incidence and prevalence of MS in a Sardinian province. *Neurology* 55 (6), 842–848.
- Grazioli, E., Zivadinov, R., Weinstock-Guttman, B., Lincoff, N., Baier, M., Wong, J.R., Ramanathan, M., 2008. Retinal nerve fiber layer thickness is associated with brain MRI outcomes in multiple sclerosis. *Journal of the neurological sciences* 268 (1–2), 12–17.
- Guo, A.C., Jewells, V.L., Provenzale, J.M., 2001. Analysis of normal-appearing white matter in multiple sclerosis: comparison of diffusion tensor MR imaging and magnetization transfer imaging. *American journal of neuroradiology* 22 (10), 1893–1900.
- Hernández-Torres, E., Wiggermann, V., Hametner, S., Baumeister, T.R., Sadovnick, A.D., Zhao, Y., Rauscher, A., 2015. Orientation dependent MR signal decay differentiates between people with MS, their asymptomatic siblings and unrelated healthy controls. *PLoS one* 10 (10).
- \*International Multiple Sclerosis Genetics Consortium\*†, ANZgene, IIBDGC, & WTCCC2. (2019). Multiple sclerosis genomic map implicates peripheral immune cells and microglia in susceptibility. *Science*, 365(6460), eaav7188.
- International Multiple Sclerosis Genetics Consortium, 2007. Risk alleles for multiple sclerosis identified by a genomewide study. *New England Journal of Medicine* 357 (9), 851–862.
- Kappos, L., Freedman, M.S., Polman, C.H., Edan, G., Hartung, H.P., Miller, D.H., Bauer, L., 2009. Long-term effect of early treatment with interferon beta-1b after a first clinical event suggestive of multiple sclerosis: 5-year active treatment extension of the phase 3 BENEFIT trial. *The Lancet Neurology* 8 (11), 987–997.
- Khalil, M., Langhammer, C., Ropele, S., Petrovic, K., Wallner-Blazek, M., Löffelheld, M., Fuchs, S., 2011. Determinants of brain iron in multiple sclerosis: a quantitative 3T MRI study. *Neurology* 77 (18), 1691–1697.

- Kinnunen, E., Juntunen, J., Ketonen, L., Koskimies, S., Konttinen, Y.T., Salmi, T., Kaprio, J., 1988. Genetic susceptibility to multiple sclerosis: a co-twin study of a nationwide series. *Archives of neurology* 45 (10), 1108–1111.
- Kuusisto, H., Wu, X., Dastidar, P., Luukkaala, T., Elovaara, I., 2012. Volumetric MRI assessment of brain and spinal cord in Finnish twins discordant for multiple sclerosis. *Medicina* 48 (9), 65.
- Langkammer, C., Liu, T., Khalil, M., Enzinger, C., Jehna, M., Fuchs, S., Ropele, S., 2013. Quantitative susceptibility mapping in multiple sclerosis. *Radiology* 267 (2), 551–559.
- Lassmann, H., Brück, W., Lucchinetti, C.F., 2007. The immunopathology of multiple sclerosis: an overview. *Brain pathology* 17 (2), 210–218.
- Lassmann, H., Van Horsen, J., Mahad, D., 2012. Progressive multiple sclerosis: pathology and pathogenesis. *Nature Reviews Neurology* 8 (11), 647–656.
- Laule, C., Vavasour, I.M., Moore, G.R.W., Oger, J., Li, D.K., Paty, D.W., MacKay, A.L., 2004. Water content and myelin water fraction in multiple sclerosis. *Journal of neurology* 251 (3), 284–293.
- Lynch, S.G., Rose, J.W., Smoker, W., Petajan, J.H., 1990. MRI in familial multiple sclerosis. *Neurology* 40 (6), 900.
- McFarland, H., Patronas, N., McFarlin, D., Mandler, R., Beall, S., Cross, A., Krebs, H., 1985. Studies of Multiple Sclerosis in Twins, Using Nuclear Magnetic Resonance: 3: 00 PM7. *Neurology* 35 (4).
- O’Gorman, C., Lin, R., Stankovich, J., Broadley, S.A., 2013. Modelling genetic susceptibility to multiple sclerosis with family data. *Neuroepidemiology* 40 (1), 1–12.
- Okuda, D.T., Mowry, E.M., Beheshtian, A., Waubant, E., Baranzini, S.E., Goodin, D.S., Pelletier, D., 2009. Incidental MRI anomalies suggestive of multiple sclerosis: the radiologically isolated syndrome. *Neurology* 72 (9), 800–805.
- Okuda, D.T., Siva, A., Kantarci, O., Inglese, M., Katz, I., Tutuncu, M., Rovira, A., 2014. Radiologically Isolated Syndrome Consortium (RISC): Club Francophone de la Sclérose en Plaques (CFSEP). Radiologically isolated syndrome: 5-year risk for an initial clinical event. *PLoS One* 9 (3), e90509.
- Paty, D.W., Oger, J.J.F., Kastrukoff, L.F., Hashimoto, S.A., Hooge, J.P., Eisen, A.A., Robertson, W.D., 1988. MRI in the diagnosis of MS: a prospective study with comparison of clinical evaluation, evoked potentials, oligoclonal banding, and CT. *Neurology* 38 (2), 180.
- Petzold, A., Balcer, L.J., Calabresi, P.A., Costello, F., Frohman, T.C., Frohman, E.M., Paul, F., 2017. Retinal layer segmentation in multiple sclerosis: a systematic review and meta-analysis. *The Lancet Neurology* 16 (10), 797–812.
- Petzold, A., de Boer, J.F., Schippling, S., Vermersch, P., Kardon, R., Green, A., Polman, C., 2010. Optical coherence tomography in multiple sclerosis: a systematic review and meta-analysis. *The Lancet Neurology* 9 (9), 921–932.
- Polman, C.H., Reingold, S.C., Banwell, B., Clanet, M., Cohen, J.A., Filippi, M., Lublin, F.D., 2011. Diagnostic criteria for multiple sclerosis: 2010 revisions to the McDonald criteria. *Annals of neurology* 69 (2), 292–302.
- Ramagopalan, S.V., Dobson, R., Meier, U.C., Giovannoni, G., 2010. Multiple sclerosis: risk factors, prodromes, and potential causal pathways. *The Lancet Neurology* 9 (7), 727–739.
- Ristori, G., Cannoni, S., Stazi, M.A., Vanacore, N., Cotichini, R., Alfò, M., Di Giovanni, S., 2006. Multiple sclerosis in twins from continental Italy and Sardinia: a nationwide study. *Annals of neurology* 59 (1), 27–34.
- Rocca, M.A., Battaglini, M., Benedic, R.H., De Stefano, N., Geurts, J.J., Henry, R.G., Filippi, M., 2017. Brain MRI atrophy quantification in MS: from methods to clinical application. *Neurology* 88 (4), 403–413.
- Rocca, M.A., Cercignani, M., Iannucci, G., Comi, G., Filippi, M., 2000. Weekly diffusion-weighted imaging of normal-appearing white matter in MS. *Neurology* 55 (6), 882–884.
- Rovaris, M., Gass, A., Bammer, R., Hickman, S.J., Ciccarelli, O., Miller, D.H., Filippi, M., 2005. Diffusion MRI in multiple sclerosis. *Neurology* 65 (10), 1526–1532.
- Sadovnick, A.D., Armstrong, H., Rice, G.P.A., Bulman, D., Hashimoto, L., Party, D.W., Seland, T.P., 1993. A population-based study of multiple sclerosis in twins: update. *Annals of neurology* 33 (3), 281–285.
- Sadovnick, A.D., Yee, I.M., Ebers, G.C., Risch, N.J., 1998. Effect of age at onset and parental disease status on sibling risks for MS. *Neurology* 50 (3), 719–723.
- Schumacher, G.A., Beebe, G., Kibler, R.F., Kurland, L.T., Kurtzke, J.F., McDowell, F., Willmon, T.L., 1965. Problems of experimental trials of therapy in multiple sclerosis: report by the panel on the evaluation of experimental trials of therapy in multiple sclerosis. *Annals of the New York Academy of Sciences* 122 (1), 552–568.
- Seewann, A., Vrenken, H., van der Valk, P., Blezer, E.L., Knol, D.L., Castelijns, J.A., Geurts, J.J., 2009. Diffusely abnormal white matter in chronic multiple sclerosis: imaging and histopathologic analysis. *Archives of neurology* 66 (5), 601–609.
- Siger, M., Dziegielewska, K., Jasek, L., Bieniek, M., Nicpan, A., Nawrocki, J., Selmaj, K., 2008. Optical coherence tomography in multiple sclerosis. *Journal of neurology* 255 (10), 1555–1560.
- Siger-Zajdel, M., Filippi, M., Selmaj, K., 2002. MTR discloses subtle changes in the normal-appearing tissue from relatives of patients with MS. *Neurology* 58 (2), 317–320.
- Solomon, A.J., Schindler, M.K., Howard, D.B., Watts, R., Sati, P., Nickerson, J.P., Reich, D.S., 2016. “Central vessel sign” on 3T FLAIR<sup>+</sup> MRI for the differentiation of multiple sclerosis from migraine. *Annals of clinical and translational neurology* 3 (2), 82–87.
- Stephenson, E., Nathoo, N., Mahjoub, Y., Dunn, J.F., Yong, V.W., 2014. Iron in multiple sclerosis: roles in neurodegeneration and repair. *Nature Reviews Neurology* 10 (8), 459.
- Swanton, J.K., Fernando, K., Dalton, C.M., Miszkil, K.A., Thompson, A.J., Plant, G.T., Miller, D.H., 2006. Modification of MRI criteria for multiple sclerosis in patients with clinically isolated syndromes. *Journal of Neurology, Neurosurgery & Psychiatry* 77 (7), 830–833.
- Sweeney, M.D., Sagare, A.P., Zlokovic, B.V., 2018. Blood–brain barrier breakdown in Alzheimer disease and other neurodegenerative disorders. *Nature Reviews Neurology* 14 (3), 133.
- Tallantyre, E.C., Dixon, J.E., Donaldson, I., Owens, T., Morgan, P.S., Morris, P.G., Evangelou, N., 2011. Ultra-high-field imaging distinguishes MS lesions from asymptomatic white matter lesions. *Neurology* 76 (6), 534–539.
- Tavazzi, E., Dwyer, M. G., Weinstock-Guttman, B., Lema, J., Bastianello, S., Bergamaschi, R., ... Zivadinov, R., 2007. Quantitative diffusion weighted imaging measures in patients with multiple sclerosis. *Neuroimage*, 36(3), 746-754.
- Thompson, A.J., Banwell, B.L., Barkhof, F., Carroll, W.M., Coetzee, T., Comi, G., Fujihara, K., 2018a. Diagnosis of multiple sclerosis: 2017 revisions of the McDonald criteria. *The Lancet Neurology* 17 (2), 162–173.
- Thompson, A.J., Baranzini, S.E., Geurts, J., Hemmer, B., Ciccarelli, O., 2018b. Multiple sclerosis. *The Lancet* 391 (10130), 1622–1636. [https://doi.org/10.1016/s0140-6736\(18\)30481-1](https://doi.org/10.1016/s0140-6736(18)30481-1).
- Thorpe, J.W., Mumford, C.J., Compston, D.A., Kendall, B.E., MacManus, D.G., McDonald, W.I., Miller, D.H., 1994. British Isles survey of multiple sclerosis in twins: MRI. *Journal of Neurology, Neurosurgery & Psychiatry* 57 (4), 491–496.
- Tienari, P.J., Salonen, O., Wikström, J., Valanne, L., Palo, J., 1992. Familial multiple sclerosis: MRI findings in clinically affected and unaffected siblings. *Journal of Neurology, Neurosurgery & Psychiatry* 55 (10), 883–886.
- Tremlett, H., Marrie, R.A., 2020. The multiple sclerosis prodrome: Emerging evidence, challenges, and opportunities. *Multiple Sclerosis Journal* 1352458520914844.
- Uitdehaag, B.M., Polman, C.H., Valk, J., Koetsier, J.C., Lucas, C.J., 1989. Magnetic resonance imaging studies in multiple sclerosis twins. *Journal of Neurology, Neurosurgery & Psychiatry* 52 (12), 1417–1419.
- Varatharaj, A., Galea, I., 2017. The blood–brain barrier in systemic inflammation. *Brain, behavior, and immunity* 60, 1–12.
- Vrenken, H., Geurts, J.J., Knol, D.L., Polman, C.H., Castelijns, J.A., Pouwels, P.J., Barkhof, F., 2006. Normal-appearing white matter changes vary with distance to lesions in multiple sclerosis. *American journal of neuroradiology* 27 (9), 2005–2011.
- Westerlind, H., Ramanujam, R., Uvehag, D., Kuja-Halkola, R., Boman, M., Bottai, M., Hillert, J., 2014. Modest familial risks for multiple sclerosis: a registry-based study of the population of Sweden. *Brain* 137 (3), 770–778.
- Willer, C. J., Dymont, D. A., Risch, N. J., Sadovnick, A. D., Ebers, G. C., Canadian Collaborative Study Group, 2003. Twin concordance and sibling recurrence rates in multiple sclerosis. *Proceedings of the National Academy of Sciences*, 100(22), 12877-12882.
- Xia, Z., Steele, S.U., Bakshi, A., Clarkson, S.R., White, C.C., Schindler, M.K., Chibnik, L.B., 2017. Assessment of early evidence of multiple sclerosis in a prospective study of asymptomatic high-risk family members. *JAMA neurology* 74 (3), 293–300.
- Xia, Z., White, C.C., Owen, E.K., Korff, A.V., Clarkson, S.R., McCabe, C.A., Cortese, I.C., 2016. Genes and Environment in Multiple Sclerosis project: A platform to investigate multiple sclerosis risk. *Annals of neurology* 79 (2), 178–189.
- Zivadinov, R., Rudick, R.A., De Masi, R., Nasuelli, D., Ukmar, M., Pozzi-Mucelli, R.S., Zorzon, M., 2001. Effects of IV methylprednisolone on brain atrophy in relapsing-remitting MS. *Neurology* 57 (7), 1239–1247.