

Dynamics of Retinal Vessel Loss After Acute Optic Neuritis in Patients With Relapsing Multiple Sclerosis

Lilian Aly, MD, Christina Noll, Rebecca Wicklein, MD, Elisabeth Wolf, Eva Feodora Romahn, Josphine Wauschkuhn, Sami Hosari, MD, Christian Mardin, MD, Achim Berthele, MD, Bernhard Hemmer, MD, Thomas Korn, MD, and Benjamin Knier, MD

Correspondence
Dr. Knier
benjamin.knier@tum.de

Neurol Neuroimmunol Neuroinflamm 2022;9:e1159. doi:10.1212/NXI.0000000000001159

Abstract

Background and Objectives

Rarefaction of the retinal vasculature as measured by optical coherence tomography angiography (OCT-A) is a novel finding in patients with multiple sclerosis (MS). This study aimed to analyze longitudinal dynamics of the retinal vasculature following an acute inflammatory relapse including acute optic neuritis (ON) and to search for associations with alterations of the retinal architecture and visual function.

Methods

This prospective longitudinal cohort study included patients with relapsing-remitting MS or clinically isolated syndrome having an acute ON (n = 20) or a non-ON relapse (n = 33). Patients underwent examinations at baseline and after 7, 14, 28, 90, and 180 days with OCT, OCT-A, and assessment of the high- (HCVA) and low-contrast visual acuity (LCVA).

Results

Retinal vessel loss of the superficial vascular complex (SVC) evolves early after ON and reaches a plateau between 90 and 180 days (relative vessel loss $15\% \pm 8\%$ [mean \pm SD]). In addition, an $18\% \pm 18\%$ intraindividual increase of the foveal avascular zone (FAZ) is evident within 180 days after acute ON. Both SVC thinning and FAZ enlargement were associated with worse HCVA and LCVA. Rarefaction of the SVC evolved simultaneously to thinning of the common ganglion cell and inner plexiform layer (GCIP) after ON. No alterations of the deep vascular complex were seen in eyes with ON, and no alterations of the retinal vasculature were recognized in patients having acute non-ON relapses.

Discussion

Rarefaction of the SVC and growing of the FAZ evolve rapidly after ON and are linked to persistent visual disability. ON-related SVC thinning might be closely linked to GCIP atrophy and might occur due to an altered local metabolic activity within inner retinal layers.

From the Department of Neurology (L.A., C.N., R.W., E.W., E.F.R., J.W., A.B., B.H., T.K., B.K.), Klinikum rechts der Isar, Institute for Experimental Neuroimmunology (L.A., T.K., B.K.), Technical University of Munich; Department of Ophthalmology (S.H., C.M.), University Hospital of Erlangen-Nuremberg; and Munich Cluster for Systems Neurology (SyNergy) (B.H., T.K.), Germany.

Go to [Neurology.org/NN](https://www.neurology.org/NN) for full disclosures. Funding information is provided at the end of the article.

The Article Processing Charge was funded by the authors.

This is an open access article distributed under the terms of the Creative Commons Attribution-NonCommercial-NoDerivatives License 4.0 (CC BY-NC-ND), which permits downloading and sharing the work provided it is properly cited. The work cannot be changed in any way or used commercially without permission from the journal.

Glossary

CIS = clinically isolated syndrome; **DVC** = deep vascular complex; **EDSS** = Expanded Disability Status Scale; **FAZ** = foveal avascular zone; **GCIP** = ganglion cell and inner plexiform layer; **HCVA** = high-contrast visual acuity; **INL** = inner nuclear layer; **LCVA** = low-contrast visual acuity; **MS** = multiple sclerosis; **OCT** = optical coherence tomography; **OCT-A** = OCT angiography; **ON** = optic neuritis; **OPL + ONL** = combined outer plexiform and outer nuclear layer; **pRNFL** = peripapillary RNFL; **RNFL** = retinal nerve fiber layer; **RRMS** = relapsing-remitting MS; **SVC** = superficial vascular complex.

Besides inflammatory and neurodegenerative changes within the brain and spinal cord, patients with multiple sclerosis (MS) commonly reveal alterations of the optic nerve and the retina. Optical coherence tomography (OCT) allows high-resolution visualization of retinal layers and is increasingly applied to study the retinal pathology during the MS disease course. Loss of retinal ganglion cells and atrophy of the retinal nerve fiber layer (RNFL) are a common feature in patients with MS,¹ which may result from retrograde transaxonal neurodegeneration,² previous optic neuritis (ON),³ or subclinical optic neuropathy.⁴

OCT angiography (OCT-A) is a novel technique allowing rapid, noninvasive, and high-resolution imaging of retinal blood flow most likely reflecting blood vessel structures. It acquires consecutive scans at 1 location of the retina, and after removal of stationary tissue signals, the remaining signal reflects the area-intrinsic motion of corpuscular blood constituents in both venous and arterial blood vessels.⁵ There is growing evidence that patients with MS may also reveal changes in the retinal vasculature. In this context, rarefaction of superficial retinal vessels has been reported in eyes with and without a history of ON.^{6,7} The underlying mechanism, however, is not yet understood. It is a matter of debate whether ON-related retinal vessel loss results primarily from direct local inflammatory processes⁸ or whether it is a secondary phenomenon due to metabolic changes and reduced oxygen demand after the decline of ganglion cells and axons.¹

In the current study, we aim to describe longitudinal dynamics of retinal vascular changes in patients with relapsing-remitting MS (RRMS) and clinically isolated syndrome (CIS) having an acute inflammatory relapse. We furthermore integrate alterations of the retinal vasculature into changes of the retinal architecture and visual function to establish a hypothesis about the underlying pathophysiologic mechanisms.

Methods

Study Design

In this prospective longitudinal cohort study, we recruited patients with RRMS or CIS aged 18–60 years from the Department of Neurology, Klinikum rechts der Isar at the Technical University of Munich between 2019 and 2021. Patients were recruited by convenience sampling consecutively. We applied the 2017 McDonald criteria⁹ for the definition of RRMS or CIS. Inclusion criteria consisted of an acute suspected

demyelinating event and a maximum duration since the relapse onset of 30 days. Here, all patients revealed relapse-corresponding inflammatory T2 lesions during MRI of the brain or spinal cord before study inclusion. We excluded patients with substantial eye disease that may affect the integrity of the retinal architecture or vasculature (like macular degeneration, retinal tumor, retinal detachment, vascular occlusions, and history of eye surgery), refractory errors >6 diopters, an additional relapse within 90 days before study enrollment, poor OCT-A quality during baseline examination of any eye if the patient had acute ON or poor OCT-A quality of both eyes if the patient had a non-ON relapse. We furthermore excluded patients with poor OCT-A quality in more than 50% of their OCT examinations. Individual eyes with a history of ON in the past or poor OCT-A quality were removed from the analysis.

At study enrollment (baseline), patients underwent retinal OCT, OCT-A, physical examination with assessment of the Expanded Disability Status Scale (EDSS) and visual testing with recording of the high-contrast (HCVA) and low-contrast visual acuity (LCVA). A detailed medical history, especially on former ON history, was taken from all individuals. Relapse duration was defined as the time period between clinical onset of relapse symptoms and baseline OCT-A measurement. We tested for a history of an unilateral subclinical ON as proposed previously,¹⁰ which was suspected by intereye differences of both the peripapillary RNFL (pRNFL) and the common ganglion cell and inner plexiform layer (GCIP) of more than 5 and 4 μm , respectively.¹⁰ After baseline examination, patients underwent follow-up examinations at 7 ± 2 days (visit 1), 14 ± 2 days (visit 2), 28 ± 2 days (visit 3), 90 ± 7 days (visit 4), and 180 ± 7 days (visit 5) after baseline with OCT and OCT-A analysis and assessment of the HCVA and LCVA. We divided all patients into 2 groups depending on whether they had an acute ON or a non-ON relapse. We followed STROBE guidelines for reporting cohort studies.

Standard Protocol Approvals, Registrations, and Patient Consents

The study was approved by the ethics committee of the Technical University of Munich School of Medicine and adhered to the Declaration of Helsinki. All participants gave written informed consent.

Retinal Imaging

OCT and OCT-A examinations were acquired for both eyes of each patient under low lighting conditions using a spectral-domain OCT with angiography module (Heidelberg Engineering

Spectralis OCT2) by 2 experienced technicians. Conventional OCT images were acquired as described elsewhere¹¹ and included examination of the pRNFL (12° ring scan) and the macula (30° × 25° macular scan). We checked all scans for sufficient quality according to the OSCAR-IB criteria.¹² Retinal segmentation was performed automatically by an inbuilt software algorithm (Eye Explorer, version 2.5.4.) and was manually corrected if necessary.

For OCT-A imaging, en face images and decorrelation signals were recorded with a 15° × 15° angle and a lateral resolution of 5.7 μm/pixel, resulting in a 2.9 × 2.9 mm area focusing on the fovea centralis. Full-spectrum amplitude decorrelation algorithm was used for motion detection and image creation, and active eye tracking was accomplished by TruTrack. Segmentation of the macular area was performed automatically by the in-built software (version 2.5.4) into the superficial vascular complex (SVC) and the deep vascular complex (DVC). For analysis of retinal vessel density measures of the SVC and DVC, we applied the Erlangen Angio tool provided by the Department of Ophthalmology of the University Hospital of Erlangen-Nuremberg as described elsewhere.¹³ In brief, pictures of the SVC and DVC were exported, and a binary picture was generated in which vessel pixel appeared white, and tissue pixel appeared black. The center of the macula (fovea) was marked manually. We then defined the region of interest, which consisted of a circle around the fovea between 0.8 mm and 2.9 mm eccentricity (area 6.1 mm²). The vessel density was calculated as the percentage of white area (vessels) in the total region of interest area. Quantification of the foveal avascular zone (FAZ) was calculated using a self-customized MATLAB (MathWorks, vR2019b) algorithm, which applied a similar approach as the Erlangen Angio tool. A binary picture was generated, and the center of the picture containing the fovea centralis was automatically evaluated. Here, black pixels (tissue) that were exclusively surrounded by black pixels within a radius of 10 pixels were summed up to the FAZ. To ensure sufficient OCT-A image quality, we only included examinations with a signal strength of Q ≥ 30 and correct segmentation. OCT-A recordings with apparent problems (for example, retinal pathology), decentration of the imaging focus, and major motion artifacts defined as a motion artifact score¹⁴ > 2 were excluded.¹⁵

Testing of Visual Function

Monocular visual acuity was measured at high (100%) and low (2.5%) contrast using Early Treatment Diabetic Retinopathy Study charts. Charts were placed in a retroilluminated cabinet (Precision Vision) with 80 candelas per square meter in 2-m distance. Visual acuity was tested with best refractive correction according to the manufacturer's specifications. Visual acuity was calculated from the smallest correctly read line as the decimal value of the Snellen fraction.

Statistical Analysis

We applied GraphPad Prism (version 9.2.0). To account for intereye correlations, we used a paired-eye statistical approach.¹¹ Mean values of both eyes were used as 1 data point when both eyes were available and allocated to the same group

(ON, no ON). If 1 eye was excluded, values of the remaining eye were used. We applied the Fisher exact test for contingency analysis concerning sex, diagnosis, glucocorticoid therapy, occurrence of ON or relapse, and exclusion of OCT-A images. Quantitative differences between 2 groups were calculated using an unpaired *t* test if values were normally distributed and a nonparametric Mann-Whitney *U* test if not. Differences between more than 2 groups were calculated by an ordinary 1-way analysis of variance with Tukey multiple comparisons or a nonparametric Kruskal-Wallis test with Dunn multiple comparisons. To evaluate worsening of visual acuity in eyes with ON, changes in HCVA and LCVA were referenced to the measures of the respective fellow eye without ON at the same time point. To test for differences in longitudinal trends in vessel densities between eyes with and without ON, we applied fixed-effects and random-effects models with Šidák multiple comparisons. Multiple linear regression models were used to test the impact of OCT-A values on OCT measures, clinical disease patterns, and visual acuity. We corrected all models for the covariates age, sex, relapse duration, glucocorticoid therapy, and time to glucocorticoid therapy if not otherwise stated and provide the respective estimates (β value) as regression parameters. Values are provided as mean ± SD if normally distributed, otherwise as median (25%–75% interquartile range). The statistical significance threshold was $p < 0.05$.

Data Availability

Data are available on reasonable request. We will share raw imaging OCT-A data in an anonymized way on request by any qualified investigator. The data are not publicly available due to privacy or ethical restrictions.

Results

Study Cohort and Visual Diagnostics at Baseline

Ninety-one patients were enrolled into our study. Seventy-seven patients completed follow-up examinations and were considered for further analysis. Eight patients were excluded due to poor OCT-A quality ratings in >50% of their examinations and 16 patients because of insufficient OCT-A quality during the baseline examination. Thus, we used 53 patients for the final analysis.

Fifty patients were diagnosed with RRMS and 3 with CIS. Twenty patients (17 RRMS and 3 CIS) had acute ON. We did not detect any unilateral subclinical ON. Disease durations were very short in patients both with ON or non-ON relapses because this was the first relapse in the majority of patients. Most patients of both groups underwent glucocorticoid therapy (Table 1). As expected, eyes having acute ON revealed thickening of the pRNFL and reduced HCVA and LCVA measures at baseline. No differences were seen in volumes of the GCIP, inner nuclear layer (INL), or the combined outer plexiform and outer nuclear layer (OPL + ONL), and no vascular alterations were recognized in eyes with or without ON during the acute relapse (Table 2).

Table 1 Study Population and Baseline Characteristics

| | ON relapse (n = 20) | Non-ON relapse (n = 33) | <i>p</i> Value |
|---|------------------------|----------------------------|-------------------|
| Diagnosis, n (%) | | | 0.049 |
| RRMS | 17 (85) | 33 (100) | |
| CIS | 3 (15) | 0 (0) | |
| Female, n (%) | 15 (75) | 23 (70) | 0.76 |
| Age, y | 35 ± 10 | 33 ± 9 | 0.52 |
| Disease duration, mo | 0 (0–0) | 0 (0–1.5) | 0.43 |
| Relapse duration, d | 11 (6–16) | 9 (5–17) | 0.60 |
| EDSS score | 2.0 (1.0–3.0) | 2.0 (2.0–2.5) | 0.14 |
| Glucocorticoid therapy, n (%) | 19 (95) | 30 (91) | 0.66 |
| Time from onset to glucocorticoid therapy, d | 5 (3–8) | 7 (4–18) | 0.34 |

Abbreviations: CIS = clinically isolated syndrome; EDSS = Expanded Disability Status Scale; ON = optic neuritis; RRMS = relapsing-remitting multiple sclerosis.

Relapse duration reflects days from symptom onset to first optical coherence tomography angiography measurement; Fisher exact test (diagnosis, sex, and glucocorticoid therapy); unpaired *t* test; statistical significant *p* values (<0.05) are indicated in bold.

Dynamics of Retinal Vascular Loss After Acute Relapse

As a first step, we aimed to describe longitudinal dynamics of retinal vessel rarefaction following acute ON. Here, a vessel loss was recognized during the first 90 days after baseline examination (Figure 1A). After this, SVC measures remained

stable between day 90 (23% ± 3%) and day 180 (22% ± 4%). Compared with baseline, eyes having acute ON lost 4% ± 2% points of vessel density after 180 days (relative loss of 15% ± 8%). No SVC vessel loss was recognized in the fellow eyes or in eyes of patients having non-ON relapses (Figure 1A). There was a by trend increase in SVC vessel densities from baseline to day 7 in eyes from individuals with non-ON relapses (*p* = 0.18; 1-way analysis of variance). We did not see any alterations of DVC vessel densities in eyes from any group (Figure 1B), and there were no major differences in FAZ areas on the group level between eyes with or without ON (Figure 1C). Because FAZ measures may vary distinctly between individuals,¹⁶ intra-individual alterations of the FAZ size were analyzed separately as a next step. Starting on day 30 after acute ON, a relative increase of the FAZ compared with baseline was observed in eyes having ON, but not in fellow eyes, leading to an intraindividual relative FAZ growth of 18% ± 18% after 180 days (Figure 1D).

Dynamics of Retinal Injury After Acute Relapse

In line with the literature,³ ON episodes went along with atrophy of the pRNFL and GCIP and worsened visual function. We recognized pRNFL swelling at baseline (Table 2) compared with the fellow eye, which turned into pRNFL atrophy at day 90 and day 180 (Figure 2A). A GCIP loss was seen on day 14 and day 28 and reached a plateau as of day 90 after acute ON (Figure 2B). A by trend but nonsignificant increase of the INL volumes was recognized in eyes having ON (Figure 2C), and no alterations of the OPL + ONL were recognized (Figure 2D). Impairment of high-contrast vision improved mainly during the first 28 days after acute ON and reached pre-ON levels in the majority of eyes (Figure 2E). In contrast, a slight improvement of low-contrast vision was

Table 2 Visual Diagnostics at Baseline

| | ON relapse | | Non-ON relapse | | <i>p</i> Value |
|----------------------------------|-------------------|------------------|-------------------|-----------------|------------------------------|
| | NON eyes (n = 20) | ON eyes (n = 20) | NON eyes (n = 33) | ON eyes (n = 0) | |
| pRNFL, μm | 98 ± 12 | 112 ± 21 | 100 ± 11 | NA | 0.007^a |
| GCIP, mm³ | 1.98 ± 0.16 | 1.94 ± 0.16 | 1.99 ± 0.17 | NA | 0.18 |
| INL, mm³ | 0.96 ± 0.07 | 0.96 ± 0.07 | 0.98 ± 0.05 | NA | 0.36 |
| OPL + ONL, mm³ | 2.56 ± 0.20 | 2.59 ± 0.23 | 2.54 ± 0.18 | NA | 0.71 |
| SVC, % vessel density | 26.4 ± 2.7 | 27.2 ± 2.7 | 25.8 ± 3.4 | NA | 0.50 |
| DVC, % vessel density | 25.3 ± 3.5 | 25.3 ± 2.0 | 25.7 ± 2.4 | NA | 0.33 |
| FAZ, mm² | 0.24 ± 0.10 | 0.25 ± 0.11 | 0.25 ± 0.10 | NA | 0.81 |
| HCVA | 1.0 ± 0.2 | 0.5 ± 0.3 | 0.9 ± 0.2 | NA | <0.001^b |
| LCVA | 0.2 ± 0.1 | 0 ± 0 | 0.3 ± 0.1 | NA | <0.001^c |

Abbreviations: DVC = deep vascular complex; GCIP = ganglion cell and inner plexiform layer; HCVA = high-contrast visual acuity; INL = inner nuclear layer; LCVA = low-contrast visual acuity; NA = not available; NON = no optic neuritis; OCT = optical coherence tomography; ON = optic neuritis; OPL + ONL = combined outer plexiform and outer nuclear layer; pRNFL = peripapillary retinal nerve fiber layer; SVC = superficial vascular complex.

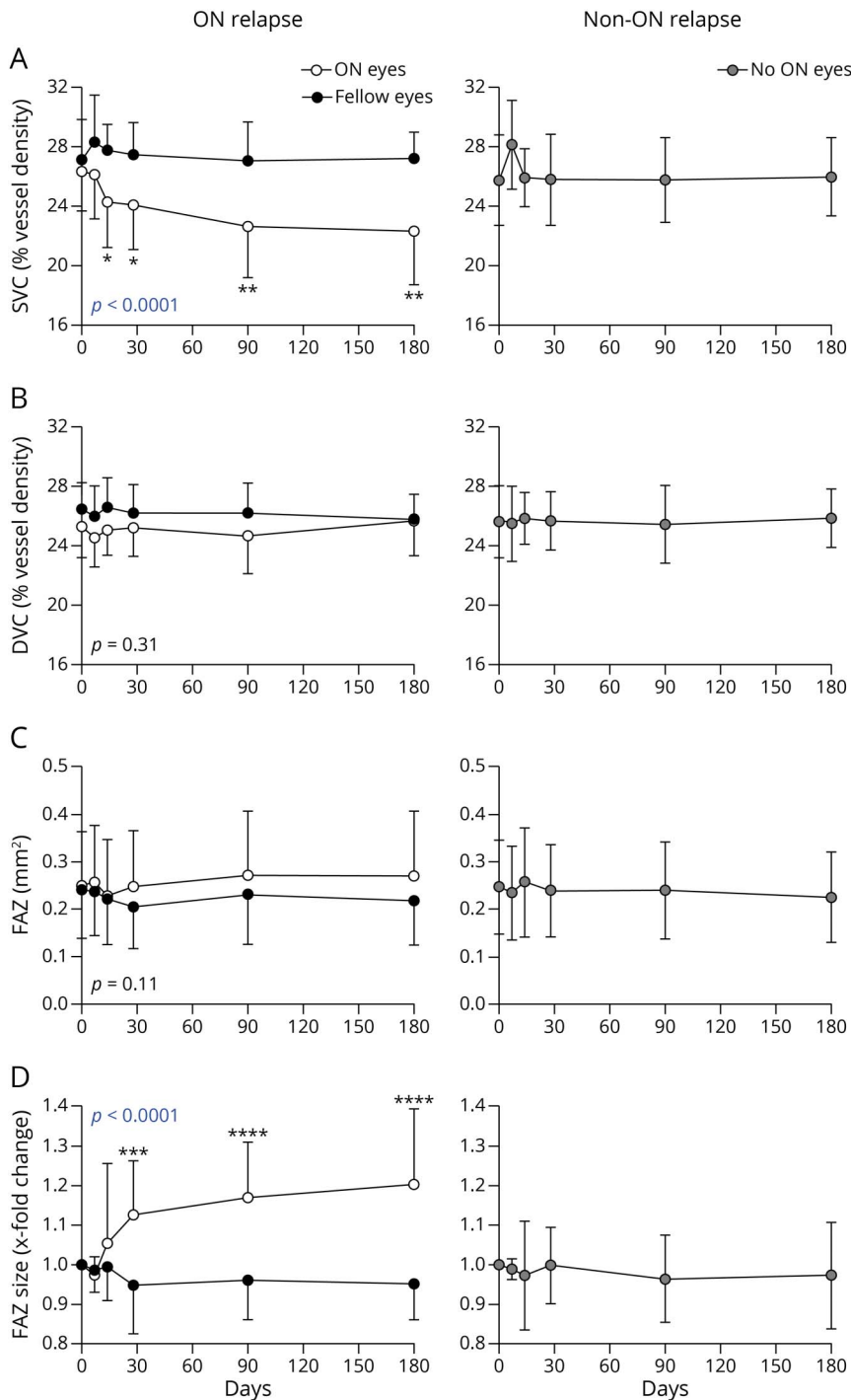
pRNFL, common GCIP, INL, and OPL + ONL as measured by optical coherence tomography OCT; SVC and DVC as measured by OCT angiography; ordinary 1-way analysis of variance with Tukey multiple comparisons or a nonparametric Kruskal-Wallis test with Dunn multiple comparisons; statistical significant *p* values (<0.05) are indicated in bold.

^a pRNFL NON eyes (ON relapse) vs ON eyes (ON relapse) *p* = 0.01; pRNFL NON eyes (non-ON relapse) vs ON eyes (ON relapse) *p* = 0.01.

^b HCVA NON eyes (ON relapse) vs ON eyes (ON relapse) *p* < 0.0001; HCVA NON eyes (non-ON relapse) vs ON eyes (ON relapse) *p* < 0.0001.

^c LCVA NON eyes (ON relapse) vs ON eyes (ON relapse) *p* < 0.0001; LCVA NON eyes (non-ON relapse) vs ON eyes (ON relapse) *p* < 0.0001.

Figure 1 Longitudinal Dynamics of the Retinal Vessel Measures After Acute Relapse



Temporal dynamics after acute relapse (x-axis, days) of vessel densities of the superficial vascular complex (SVC) (A), deep vascular complex (DVC) (B), and the foveal avascular zone (FAZ) (C and D) in patients having acute optic neuritis (ON) (ON relapse, left panels) and relapses other than ON (non-ON relapse, right panels). Symbols depict mean values of single patient values with standard deviations at baseline (ON relapse n = 20, non-ON relapse n = 33), visit 1 (ON relapse n = 14, non-ON relapse n = 24), visit 2 (ON relapse n = 16, non-ON relapse n = 28), visit 3 (ON relapse n = 15, non-ON relapse n = 24), visit 4 (ON relapse n = 17, non-ON relapse n = 29), and visit 5 (ON relapse n = 19, non-ON relapse n = 29). Lines with clear circles depict ON eyes, and lines with black circles illustrate the respective fellow eyes, and lines with gray circles display eyes of individuals with a non-ON relapse. *p* Values indicate differences between both groups all over the time course (fixed-effects model); **p* < 0.05, ***p* < 0.01, ****p* < 0.001, and *****p* < 0.0001 compared with the other group within the respective time points (Sidak multiple comparisons).

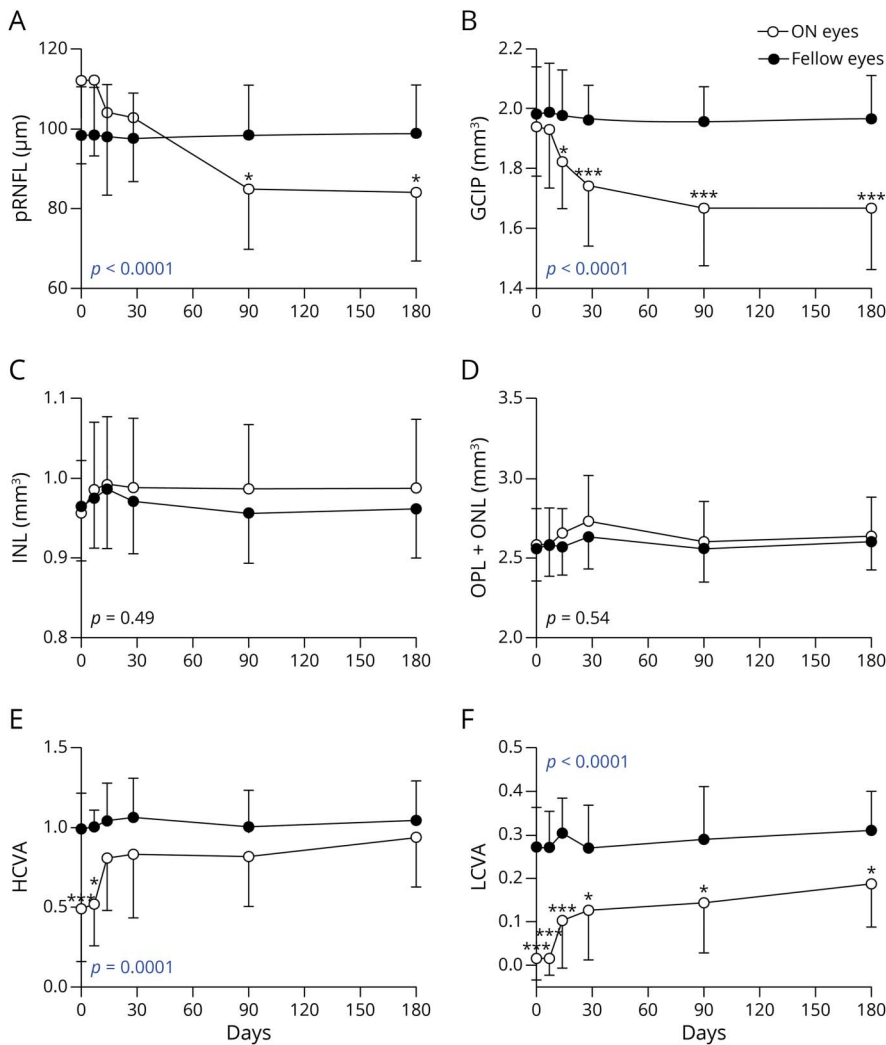
recognized within the first 28 days after acute ON, whereas complete remission of the LCVA did not occur in most eyes by day 180 after acute ON (Figure 2F).

Association of Retinal Vessel Loss, Retinal Injury, and Visual Function

As a next step, we searched for associations between retinal vessel loss, clinical characteristics, and alterations of the retinal

architecture. Applying multiple linear regression models, a decline of the SVC on day 180 was associated with a loss of ganglion cells (Figure 3A) and by trend with thinning of the pRNFL ($p = 0.07$, $\beta = 0.07$, 95% CI -0.01 to 0.16) after acute ON and greater residual impairment of the visual function, in particular of the LCVA (Figure 3B). Similarly, an increase of the FAZ was linked to GCIP loss (Figure 3C) and HCVA impairment (Figure 3D) after 180 days. Moreover, we found

Figure 2 Longitudinal Dynamics of the Retinal Architecture and Visual Function After Acute ON



Temporal dynamics after acute optic neuritis (ON) (x-axis, days) of the peripapillary retinal nerve fiber layer (pRNFL) (A), the common ganglion cell and inner plexiform layer (GCIP) (B), the inner nuclear layer (C), the combined outer plexiform and outer nuclear layer (OPL + ONL) (D), the high-contrast visual acuity (HCVA) (E), and low-contrast visual acuity (LCVA) (F) in patients having acute ON. Symbols depict mean values of eyes having ON (ON eye) and the healthy fellow eye (fellow eye) with standard deviations at baseline (n = 20), visit 1 (n = 14), visit 2 (n = 15), visit 3 (n = 17), and visit 5 (n = 19); p values indicate differences between both groups all over the time course (fixed-effects model); **p* < 0.05, and ****p* < 0.001 compared with the other group within the respective time points (Sidak multiple comparisons).

an association of GCIP loss with impairment of both HCVA ($p = 0.002$, $\beta = 0.49$, 95% CI 0.20–0.78) and LCVA ($p = 0.048$, $\beta = 0.49$, 95% CI 0.01–1.40). When additionally controlling for GCIP atrophy, an increase of the FAZ remained robustly linked to HCVA impairment ($p = 0.007$, $\beta = 0.11$, 95% CI 0.04–0.19), whereas the association of SVC thinning and LCVA impairment got lost ($p = 0.12$, $\beta = 8.3$, 95% CI –2.7 to 19.4). When analyzing relative changes compared with the respective baseline measures, longitudinal SVC vessel and GCIP loss following acute ON revealed very congruent dynamics (Figure 3E). For both parameters SVC and FAZ, no association was found with age, sex, disease duration, EDSS, time to glucocorticoid therapy, INL, or OPL + ONL values (data not shown).

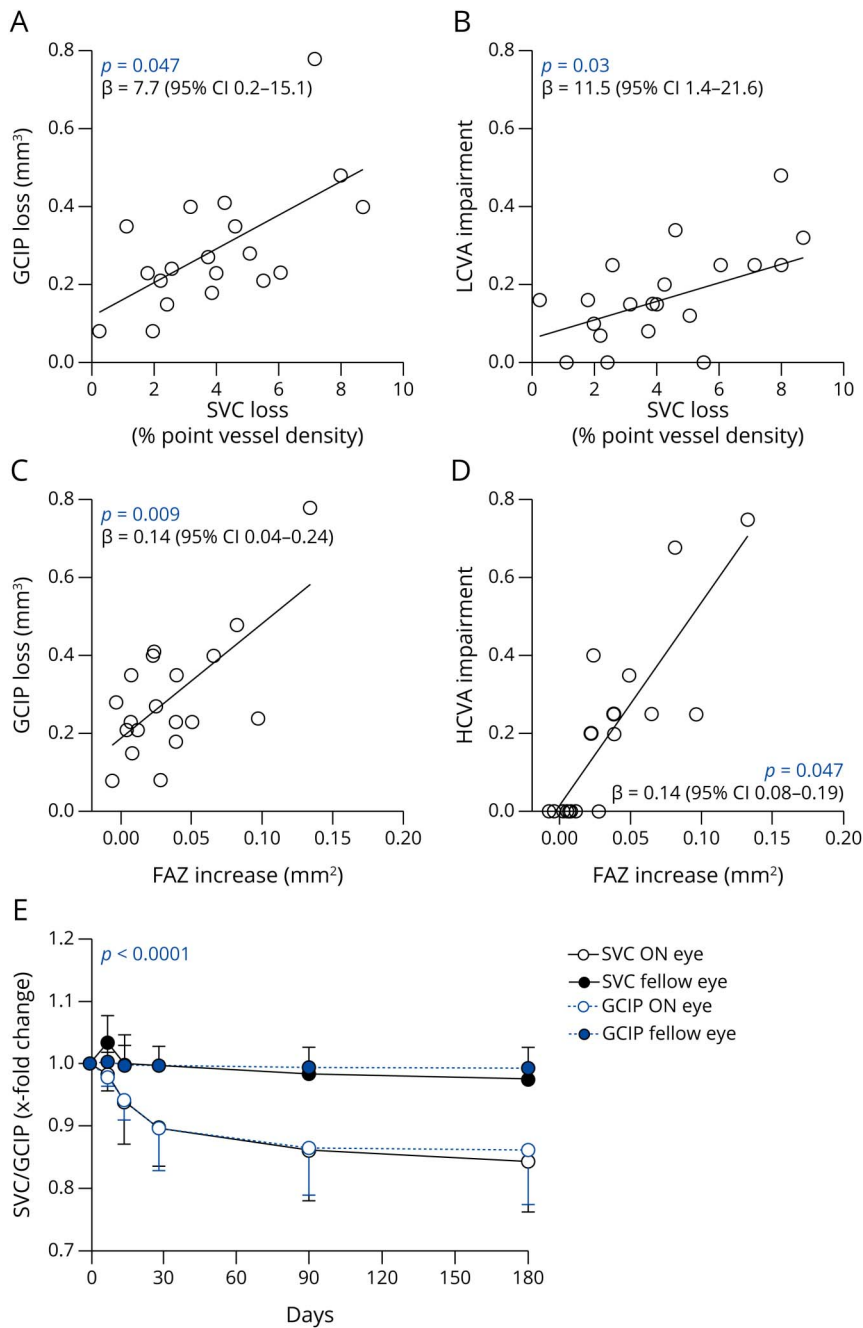
Discussion

Our study describes longitudinal dynamics of macular retinal vessel loss following ON in patients with RRMS

and CIS. Our data indicate a close relation of retinal vessel loss, the decline of ganglion cells, and worsening of the visual function. Based on this, we established the hypothesis that an ON-related decrease in retinal perfusion might be the immediate result of an atrophy of ganglion cells and their axons, potentially due to an altered local metabolic activity.

During the last years, the OCT-A technique has been applied by several groups^{6,17-19} and us^{7,15} to study alterations of retinal vasculature in patients with MS. Here, superficial vessel loss with thinning of the SVC has been shown to be a consistent finding in patients with RRMS and a history of ON of more than 3 months before OCT-A analysis.^{6,7,17-19} In a recent cross-sectional study intereye differences of SVC measures between fellow eyes with and without an ON history were evident in patients with a time lag of more than 3–12 months (by trend) and more than 12 months to the last ON.¹⁷ Our study is—in principle—in line with these findings, whereas we could detect SVC loss already 14 and 28 days after ON, which might be due

Figure 3 Association of the Retinal Vasculature With Visual Function and Retinal Atrophy



(A) Association of changes of the superficial vascular complex (SVC) and changes of the common ganglion cell and inner plexiform layer (GCIP) between baseline and day 180 in 19 eyes of 19 patients having acute optic neuritis (ON). (B) Association of changes of the SVC between baseline and day 180 and impairment of the low-contrast visual acuity (LCVA) compared with the fellow eye at day 180 in 19 eyes of 19 patients having ON. (C) Association of foveal avascular zone (FAZ) enlargement and changes of the GCIP between baseline and day 180 in 19 eyes of 19 patients having acute ON. (D) Association of FAZ enlargement between baseline and day 180 and impairment of the high-contrast visual acuity (HCVA) compared with the fellow eye at day 180 in 19 eyes of 19 patients having ON. (E) Relative change compared with baseline measures of SVC and GCIP measures in eyes having ON (ON eye, n = 19) and the respective healthy fellow eye (fellow eye, n = 19). (A–D) Multiple linear regression models adjusted for age, sex, relapse duration, glucocorticoid therapy, and time to glucocorticoid therapy. (E) Fixed-effects model.

to an increased sensitivity of a prospective longitudinal study design.

Data on alterations of the DVC in eyes with an ON history are conflicting. Both DVC loss,^{7,20} DVC thickening,¹⁹ and comparable DVC measures to non-ON eyes^{6,18} have been described by different groups using different OCT-A devices. Here, vessel measures may vary greatly and cannot be transferred interchangeably between OCT-A devices.²¹ In the present study, we did not see any clear longitudinal alteration of the DVC in eyes with or without past ON, suggesting that

deep retinal vessels might be rather not affected during and after ON.

Enlargement of the FAZ is evident in the eyes of patients with MS irrespective of an ON history compared with healthy people, whereas on the group level, no differences have been recognized in ON and fellow eyes in recently published cross-sectional analyses.^{15,22} With the same result on cross-sectional comparison, we could detect an intraindividual longitudinal growth of the FAZ following acute ON. Here, given the large variability of individual FAZ measures,¹⁶ the sensitivity of

cross-sectional studies might be too low to detect discrete intraindividual alterations of the FAZ. The significance of FAZ enlargement during RRMS is unclear. In patients with neuromyelitis optica spectrum disorders, growths of the FAZ might go along with damage of astrocytes and might indicate subclinical and relapse-independent inflammatory disease activity.¹⁵ In patients with RRMS and acute ON, FAZ enlargement might reflect worsening of the visual function, whereas its integration into the pathophysiologic concept of MS remains to be determined.

As already shown in other OCT studies,^{6,17} visual function recovered during the first month after ON. In our study, HCVA improved within the first weeks, whereas LCVA recovery took several months and still remained incomplete 6 months after ON in the majority of patients. Superficial retinal vessel loss and enlargement of the FAZ were associated with impairment of the visual function 6 months after ON. These findings suggest that OCT-A might be a diagnostic tool to evaluate retinal injury, recovery, and visual impairment after acute ON.

So far, the underlying mechanisms of SVC loss after ON are unclear. We recognized a loss of ganglion cells and optic nerve axons following acute ON. In line with the literature,^{3,23,24} both ganglion cell and axonal loss occurred within the first 3 months after ON reaching a plateau afterward. ON-related axonal loss was partly masked by axonal swelling during the first 3 months. As shown above, the decline of superficial retinal vessels occurred simultaneously to the atrophy of ganglion cells and their axons, suggesting that both processes might be closely pathophysiologically linked. In the current anatomical concept and supported by OCT-A based studies,²⁵ the approximately 80- μ m-thick SVC is supplied by the central retinal artery and encompasses the whole RNFL and GCIP. It appears possible that an atrophy of both neuronal and axonal structures after ON results in a reduced metabolic activity and lower oxygen demand within the RNFL and GCIP. As an immediate result, a lower local layer perfusion as detected by OCT-A and subsequent regression of vessels surrounding these impaired layers, namely the SVC but not the DVC, might evolve.

On the contrary, a primary pathology of retinal vessels inducing secondary atrophy of inner retinal layers appears less likely. Given the fact that up to 11% of patients with MS show signs of retinal periphlebitis at autopsy,⁸ it was speculated that ON-related rarefaction of the superficial retinal vessels might be due to a primary inflammatory process affecting retinal vessels. The current study argues against this hypothesis. It is known that disturbance of the retinal perfusion and reduced oxygen supply leads to a subsequent but delayed atrophy of inner retinal layers. OCT-based longitudinal studies on patients having acute retinal artery branch occlusion revealed loss of both RNFL and GCIP between 3 and 12 months after the initial event.²⁶ In the current study, we did not see any time gap between SVC perfusion decline and ganglion cell

atrophy, and both measures reached a plateau phase after 3 months, which would be unusual for a primary vascular event. In addition, inflammatory diseases affecting the retinal vasculature like Behçet disease²⁷ or retinal vasculitis²⁸ mostly reveal thinning of both the SVC and DVC and might go along with thickening of all inner retinal layers in the acute phase. Here, we did neither recognize thinning of the DVC nor thickening of the inner retinal layers except the pRNFL.

Based on the simultaneous occurrence of GCIP reduction and vessel loss, however, it cannot be excluded that both features are secondary phenomena to the same inflammatory detrimental trigger or appear both gradually after an acute inflammatory injury of both retinal vessels and tissue. In this scenario, however, sparing of the DVC would be unusual. The DVC is fed by anastomoses of the SVC and supplies the inner nuclear and outer plexiform layer.²⁵ Therefore, it appears unplausible that an inflammatory process affecting both the GCIP and SVC would not impair the integrity and change the size of the DVC.

Our study has several limitations. First, we had a rather high portion of patients that were excluded due to OCT-A quality reasons (26% of patients). OCT-A is a novel technique, and examinations are technically challenging compared with conventional OCT, particularly in eyes with visual impairment. All examinations were conducted by 2 experienced and well-trained technicians, and we applied a strict and rigorous approach for OCT-A quality control to ensure reliable OCT-A follow-up measures. Here, widely accepted OCT-A quality criteria are missing to date. Second, OCT-A measures are device specific and cannot be transferred interchangeably.²¹ We cannot exclude a device-specific effect on our results and conclusions, and further studies using different OCT-A machines are needed to reproduce our findings. However, all patients were measured with the same device, and moreover, the data of the current study reproducing known aspects of transformation after ON are in line with findings from other groups and devices. Third, there are methodological issues of the used technique that confine the interpretability of the presented findings. Although OCT-A is an accepted tool to analyze the retinal vasculature and retinal vessel pathology, it only provides information about retinal perfusion patterns, but not on vessel morphology and vessel integrity. For example, an automatic and robust differentiation of retinal vessel structures into veins and arteries is not possible at the moment. The vessel density measures generated by OCT-A in this study cannot ensure irreversibility. Moreover, the currently used OCT-A technique makes it difficult to clearly distinguish whether a decrease in retinal vessel density is a matter of true loss of vessel branches, a constriction, or shrinking of vessel structures. This is also due to the fact that 3-dimensional OCT-A raw data are consolidated into a 2-dimensional OCT-A picture. However, animal studies have addressed this question in the past and suggest that mainly the size of capillaries decreases after optic nerve injury, whereas their number remains unaltered.²⁹ Here, advances in both

hardware and software solutions are needed to address this feature in the future.

In conclusion, this study shows that rarefaction of the superficial retinal vasculature occurs within the first 90 days after acute ON and evolves simultaneously to the atrophy of ganglion cells. This process is possibly caused by an altered metabolic activity within the inner retinal layer, suggesting that ON-related SVC thinning might be an immediate secondary phenomenon after GCIP atrophy. Further studies are needed to integrate retinal vessel pathology into the pathophysiologic concept of MS.

Acknowledgment

The authors thank Mira Radic and Andrea Hennemann for expert assistance during OCT-A acquisition and analysis.

Study Funding

This study was funded by the Gemeinnützige Hertie Foundation (medMS program to C. Noll and B. Knier; Hertie Network of Clinical Neuroscience to T. Korn), the European Union's Horizon 2020 (H2020) Research and Innovation Program (grant MultipleMS EU RIA 733161 to B. Hemmer), the Deutsche Forschungsgemeinschaft (Munich Cluster for Systems Neurology EXC 2145 SyNergy: ID 390857198) to B. Hemmer and T. Korn; SFB1054-B06, TRR128-A07, TRR128-A12, TRR274-A01 to T. Korn), the Else Kröner-Fresenius-Stiftung (Else Kröner-Fresenius Exzellenzstipendium to B. Knier) and Novartis Pharma GmbH Deutschland (Oppenheim research award 2020 to B. Knier).

Disclosure

L. Aly received travel support from Novartis Pharma GmbH Deutschland. C. Noll, R. Wicklein, E. Wolf, E. F. Romahn, J. Wauschkuhn, and S. Hosari have nothing to report. C. Mardin served as medical advisor at Heidelberg Engineering, Heidelberg. A. Berthele received reimbursements for the participation in randomized controlled trials from Alexion, Biogen, Merck, Novartis, and Roche and received compensations for participation in advisory boards from Alexion, Biogen, Celgene, Hexal/Novartis, and Roche; all conflicts are not relevant to the topic of the study. B. Hemmer has served on scientific advisory boards for Novartis and Sandoz; he has served as DMSC member for AllergyCare, Polpharma, and TG Therapeutics; he or his institution has received speaker honoraria from Desitin; his institution received research grants from Regeneron for multiple sclerosis research. He holds part of 2 patents; 1 for the detection of antibodies against KIR4.1 in a subpopulation of patients with multiple sclerosis and 1 for genetic determinants of neutralizing antibodies to interferon; all conflicts are not relevant to the topic of the study. T. Korn received reimbursements for the participation in think tanks of Janssen, Novartis, and Sanofi-Genzyme. B. Knier received travel support and a research grant from Novartis Pharma GmbH Deutschland. Go to [Neurology.org/NN](https://www.neurology.org/NN) for full disclosures.

Publication History

Received by *Neurology: Neuroimmunology & Neuroinflammation* October 23, 2021. Accepted in final form January 3, 2022. Submitted and externally peer reviewed. The handling editor was Friedemann Paul, MD.

Appendix Authors

| Name | Location | Contribution |
|-----------------------------|--|--|
| Lilian Aly, MD | Department of Neurology, Klinikum rechts der Isar, and Institute for Experimental Neuroimmunology, Technical University of Munich, Germany | Drafting/revision of the manuscript for content, including medical writing for content; major role in the acquisition of data; study concept or design; and analysis or interpretation of data |
| Christina Noll | Department of Neurology, Klinikum rechts der Isar, Technical University of Munich, Germany | Major role in the acquisition of data and analysis or interpretation of data |
| Rebecca Wicklein | Department of Neurology, Klinikum rechts der Isar, Technical University of Munich, Germany | Drafting/revision of the manuscript for content, including medical writing for content, and major role in the acquisition of data |
| Elisabeth Wolf | Department of Neurology, Klinikum rechts der Isar, Technical University of Munich, Germany | Major role in the acquisition of data and analysis or interpretation of data |
| Eva Feodora Romahn | Department of Neurology, Klinikum rechts der Isar, Technical University of Munich, Germany | Major role in the acquisition of data and analysis or interpretation of data |
| Josphine Wauschkuhn | Department of Neurology, Klinikum rechts der Isar, Technical University of Munich, Germany | Major role in the acquisition of data and analysis or interpretation of data |
| Sami Hosari, MD | Department of Ophthalmology, University Hospital of Erlangen-Nuremberg, Germany | Analysis or interpretation of data |
| Christian Mardin, MD | Department of Ophthalmology, University Hospital of Erlangen-Nuremberg, Germany | Drafting/revision of the manuscript for content, including medical writing for content, and analysis or interpretation of data |
| Achim Berthele, MD | Department of Neurology, Klinikum rechts der Isar, Technical University of Munich, Germany | Drafting/revision of the manuscript for content, including medical writing for content, and study concept or design |
| Bernhard Hemmer, MD | Department of Neurology, Klinikum rechts der Isar, Technical University of Munich; Munich Cluster for Systems Neurology (SyNergy), Germany | Drafting/revision of the manuscript for content, including medical writing for content, and study concept or design |
| Thomas Korn, MD | Department of Neurology, Klinikum rechts der Isar, and Institute for Experimental Neuroimmunology, Technical University of Munich; Munich Cluster for Systems Neurology (SyNergy), Germany | Drafting/revision of the manuscript for content, including medical writing for content, and study concept or design |
| Benjamin Knier, MD | Department of Neurology, Klinikum rechts der Isar, and Institute for Experimental Neuroimmunology, Technical University of Munich, Germany | Drafting/revision of the manuscript for content, including medical writing for content; major role in the acquisition of data; study concept or design; and analysis or interpretation of data |

References

1. Petzold A, Balcer LJ, Calabresi PA, et al. Retinal layer segmentation in multiple sclerosis: a systematic review and meta-analysis. *Lancet Neurol*. 2017;16(10):797-812.
2. Saidha S, Al-Louzi O, Ratchford JN, et al. Optical coherence tomography reflects brain atrophy in multiple sclerosis: a four-year study. *Ann Neurol*. 2015;78(5):801-813.
3. Gabilondo I, Martinez-Lapiscina EH, Fraga-Pumar E, et al. Dynamics of retinal injury after acute optic neuritis. *Ann Neurol*. 2015;77(3):517-528.
4. Outterryck O, Lopes R, Drumez E, et al. Optical coherence tomography for detection of asymptomatic optic nerve lesions in clinically isolated syndrome. *Neurology*. 2020;95(6):e733-e744.
5. Chalam KV, Sambhav K. Optical coherence tomography angiography in retinal diseases. *J Ophthalmic Vis Res*. 2016;11(1):84-92.
6. Murphy OC, Kwakyi O, Iftikhar M, et al. Alterations in the retinal vasculature occur in multiple sclerosis and exhibit novel correlations with disability and visual function measures. *Mult Scler*. 2020;26(7):815-828.
7. Feucht N, Maier M, Lepennetier G, et al. Optical coherence tomography angiography indicates associations of the retinal vascular network and disease activity in multiple sclerosis. *Mult Scler*. 2019;25(2):224-234.
8. Green AJ, McQuaid S, Hauser SL, Allen IV, Lyness R. Ocular pathology in multiple sclerosis: retinal atrophy and inflammation irrespective of disease duration. *Brain*. 2010;133(pt 6):1591-1601.
9. Thompson AJ, Banwell BL, Barkhof F, et al. Diagnosis of multiple sclerosis: 2017 revisions of the McDonald criteria. *Lancet Neurol*. 2018;17(2):162-173.
10. Nolan-Kenney RC, Liu M, Akhand O, et al. Optimal intereye difference thresholds by optical coherence tomography in multiple sclerosis: an international study. *Ann Neurol*. 2019;85(5):618-629.
11. Knier B, Lepennetier G, Wetzlmair C, et al. Association of retinal architecture, intrathecal immunity, and clinical course in multiple sclerosis. *JAMA Neurol*. 2017;74(7):847-856.
12. Schippling S, Balk LJ, Costello F, et al. Quality control for retinal OCT in multiple sclerosis: validation of the OSCAR-IB criteria. *Mult Scler*. 2015;21(2):163-170.
13. Hosari S, Hohberger B, Theelke L, Sari H, Lucio M, Mardin CY. OCT angiography: measurement of retinal macular microvasculature with Spectralis II OCT angiography—reliability and reproducibility. *Ophthalmologica*. 2020;243(1):75-84.
14. Lauer mann JL, Treder M, Heiduschka P, Clemens CR, Eter N, Alten F. Impact of eye-tracking technology on OCT-angiography imaging quality in age-related macular degeneration. *Graefes Arch Clin Exp Ophthalmol*. 2017;255(8):1535-1542.
15. Aly L, Strauss EM, Feucht N, et al. Optical coherence tomography angiography indicates subclinical retinal disease in neuromyelitis optica spectrum disorders. *Mult Scler*. 2021;2021:13524585211028831.
16. Anvari P, Najafi A, Mirshahi R, et al. Superficial and deep foveal avascular zone area measurement in healthy subjects using two different spectral domain optical coherence tomography angiography devices. *J Ophthalmic Vis Res*. 2020;15(4):517-523.
17. Murphy OC, Kalaitzidis G, Vasileiou E, et al. Optical coherence tomography and optical coherence tomography angiography findings after optic neuritis in multiple sclerosis. *Front Neurol*. 2020;11:618879.
18. Ulusoy MO, Horasanli B, Isik-Ulusoy S. Optical coherence tomography angiography findings of multiple sclerosis with or without optic neuritis. *Neurol Res*. 2020;42(4):319-326.
19. Rogaczewska M, Michalak S, Stopa M. Macular vessel density differs in multiple sclerosis and neuromyelitis optica spectrum disorder: an optical coherence tomography angiography study. *PLoS One*. 2021;16(6):e0253417.
20. Lanzillo R, Cennamo G, Criscuolo C, et al. Optical coherence tomography angiography retinal vascular network assessment in multiple sclerosis. *Mult Scler*. 2018;24(13):1706-1714.
21. Trachsler S, Baston AE, Menke M. Intra- and interdevice deviation of optical coherence tomography angiography. *Klin Monbl Augenheilkd*. 2019;236(4):551-554.
22. Yilmaz H, Ersoy A, Icel E. Assessments of vessel density and foveal avascular zone metrics in multiple sclerosis: an optical coherence tomography angiography study. *Eye (Lond)*. 2020;34(4):771-778.
23. Yau GS, Lee JW, Lau PP, Tam VT, Wong WW, Yuen CY. Longitudinal changes in retinal nerve fibre layer thickness after an isolated unilateral retrobulbar optic neuritis: 1-year results. *Neuroophthalmology*. 2015;39(1):22-25.
24. Soelberg K, Specovius S, Zimmermann HG, et al. Optical coherence tomography in acute optic neuritis: a population-based study. *Acta Neurol Scand*. 2018;138(6):566-573.
25. Campbell JP, Zhang M, Hwang TS, et al. Detailed vascular anatomy of the human retina by projection-resolved optical coherence tomography angiography. *Sci Rep*. 2017;7:42201.
26. Kim MS, Kim KM, Lim HB, Jo YJ, Kim JY. Longitudinal changes of retinal thicknesses in branch retinal artery occlusion: spectral-domain optical coherence tomography study. *Invest Ophthalmol Vis Sci*. 2018;59(11):4731-4737.
27. Yan C, Li F, Hou M, et al. Vascular abnormalities in peripapillary and macular regions of Behcet's uveitis patients evaluated by optical coherence tomography angiography. *Front Med (Lausanne)*. 2021;8:727151.
28. Tian M, Tappeiner C, Zinkernagel MS, Huf W, Wolf S, Munk MR. Evaluation of vascular changes in intermediate uveitis and retinal vasculitis using swept-source wide-field optical coherence tomography angiography. *Br J Ophthalmol*. 2019;103(9):1289-1295.
29. Quigley HA, Hohman RM, Addicks EM. Quantitative study of optic nerve head capillaries in experimental optic disk pallor. *Am J Ophthalmol*. 1982;93(6):689-699.