

## Research Paper

# Realistic three-dimensional imaging of injuries in forensic medicine - Survey-based method comparison of CRT and VRT

G.M. Bruch<sup>a,\*</sup>, K. Engel<sup>b</sup>, J. Schropp<sup>c</sup>, S. Grabherr<sup>d,e</sup>

<sup>a</sup> Institut für Rechtsmedizin, Ludwig-Maximilians-Universität, Munich, Germany

<sup>b</sup> Medical Imaging Technologies, Siemens Healthcare Technology Center, Erlangen, Germany

<sup>c</sup> Jonas Schropp Consulting, Switzerland

<sup>d</sup> Centre Universitaire Romand de Médecine Légale, Hôpitaux Universitaires de Genève, Université de Genève, Switzerland

<sup>e</sup> Centre Universitaire Romand de Médecine Légale, Centre Hospitalier Universitaire Vaudois, Université de Lausanne, Switzerland

## ARTICLE INFO

Handling Editor: Wilma Duijst

## Keywords:

3D imaging

Cinematic rendering technique

CRT

PMCT

Postmortem CT angiography

Volumen rendering technique

VRT

## ABSTRACT

**Objective:** A comparison between Cinematic Rendering Technique (CRT) and Volume Rendering Technique (VRT) in cases with postmortem CT-angiography (PMCTA) was carried out.

**Methods:** For different injuries seen in PMCTA, a VRT and a CRT image of exactly the same pathological section was generated. Two questionnaires were created, one with CRT and one with VRT reconstructions, with the same questions per 3D-image. The questionnaires were sent to forensic pathologists, lawyers and police officers. In total eleven different injuries had to be analyzed.

**Results:** In total 109 questionnaires were answered fully. Of these returnees, 36 stated that they were forensic pathologists. Seventy-three people were assigned to the group of medical laypersons, in the study this group consists mainly of police officers, judges and lawyers. Between the two software programs CRT and VRT that were compared, no significant difference could be identified in any of the participating groups with regard to the assessment of the life-threatening nature of the injury images shown. When asked about the comprehensibility of pathology, there was a significant difference in favour of CRT. This advantage was apparent to named medical laypersons and to forensic pathologists.

**Conclusions:** The study showed a positive trend that CRT may be more understandable than VRT. Not only the medical laypersons, but also the forensic physicians found CRT to be beneficial.

## 1. Introduction

In recent years post-mortem imaging has increasingly come to the fore.<sup>1,2</sup> In particular, post-mortem computed tomography (PMCT) is now often performed as standard.<sup>3-6</sup> Post-mortem computed tomography angiography (PMCTA) has also shown to be superior to conventional autopsy in the search for vascular occlusions or bleeding sources.<sup>7,8</sup> In the context of technical progress, not only 2D but also 3D visualisation of PMCT and PMCTA datasets are often produced. The 3D visualisation is not used for data evaluation, but for better presentation in expert reports.

Forensic medical reports are mainly written for lawyers, police officers or private persons. This group of clients are medical laypersons. It is therefore necessary that such expert opinions are understandable for the client. Currently, when 3D representations are used, they are mainly

generated with the Volume Rendering Technique (VRT) software, which has been known and tested for many years. Due to technical developments in radiology, Siemens Healthineers GmbH (Erlangen, Germany) has developed the so-called Cinematic Rendering Technique (CRT) software for the three-dimensional representation of the human body, mainly used in the clinical context.<sup>9-11</sup>

The CRT software is based on new animation techniques and, in particular, can create more photorealistic light and shadow effects. CRT generates more than a hundred times the number of photon paths per pixel than conventional VR technology. To achieve this more photorealistic visualisation, a complex model calculates the light paths that reach the eye and prioritises the photon paths required. This can result in a more understandable 3D model of the human body.<sup>12</sup>

The new method can also be a useful addition to the 3D representation of PMCTA data.<sup>13,14</sup>

\* Corresponding author. Nussbaumstr. 26, 80336, Munich, Germany.

E-mail address: [gina.bruch@med.uni-muenchen.de](mailto:gina.bruch@med.uni-muenchen.de) (G.M. Bruch).

<https://doi.org/10.1016/j.jflm.2024.102681>

Received 9 February 2024; Received in revised form 14 March 2024; Accepted 23 March 2024

Available online 4 April 2024

1752-928X/© 2024 The Authors. Published by Elsevier Ltd. This is an open access article under the CC BY-NC-ND license (<http://creativecommons.org/licenses/by-nc-nd/4.0/>).

Due to the altered, more photorealistic representation of light incidence, the 3D images produced by CRT could provide a better understanding of expert reports for medical laypersons. It is important for the court to be able to follow the expert's explanation of, for example, the number and the locations of fractures, bleeding or other injuries. As a next step, the forensic expert can use these 3D images to explain the nature and direction of the force used.

The purpose of this analysis is to explore whether the described technological advances in forensic medicine help to reconstruct cases in a more comprehensible way and to better understand the severity of injuries after violent crimes for the professional groups involved. This could be the case through more accurate three-dimensional visualisation using CRT.

## 2. Material and methods

The retrospective evaluation and further processing of the data collected in routine was approved by the responsible ethics committee (Cantone Vaud CER-VD No. 2022-00075).

### 2.1. Selection of the MPMCTA data

First, the forensic medical reports of legally closed cases investigated by the MPMCTA ordered by the public prosecutor in the years 2015–2019 were searched in our local database at the Institute of Forensic Medicine (Lausanne, Switzerland) using the keywords “haemorrhage” and “vascular injury”. The radiological reports found were then categorised as either “traumatic injury”, e.g. following sharp force or gunshot, or “other”. After this selection, 31 post-mortem radiology reports with routinely performed PMCT angiographies after “traumatic injury” were found.

The MPMCTA datasets of these cases were then reviewed by a forensic expert and a radiology expert to determine whether a source of bleeding, vascular injury or other traumatic injury could be clearly identified in the angiography. From the 31 data sets found, the ten cases that seemed most relevant to the research question of this study were finally selected and processed into 3D images.

The selected cases showed (multiple) gunshot wounds (with bone fractures, intrathoracic bleeding) or sharp force to the neck (with severing of a carotid artery), thorax (knife blade remnants, haemopneumothoraces), head and extremities.

The settings of the earlier performed MPMCTA were the following: section thickness 1.25 mm, field of view 500 mm, tub voltage 120 kV, tube current 200 mA and the postmortem angiography was carried out as described by Grabherr et al.<sup>4</sup> (Devices: GE LightSpeed VCT 64 Slice CT Scanner, GE Healthcare, Milwaukee, USA and Virtangio-Pump, Fumedica AG, Luzernerstr. 91, Muri, Switzerland).

### 2.2. Creation of 3D images with Cinematic Rendering Technique (CRT) and Volume Rendering Technique (VRT) software

For each pathology, a VRT and a CRT of exactly the same image section with the same information content were generated. Image sections from ten different cases were selected from the datasets based on the clarity of the pathology seen. Due to the technical equipment, the reconstructed image section could be created in directly consecutive steps with both software programs, without moving the image section or readjusting the pathology shown. This ensured that the viewing angle and section depth, as well as other settings such as the optical distance of bleeding or bone, were exactly the same in the images (Figs. 1–3). The datasets were generated using the Siemens Healthineers Cinematic Anatomy application, version VA40A (Siemens Healthineers, Erlangen, Germany).

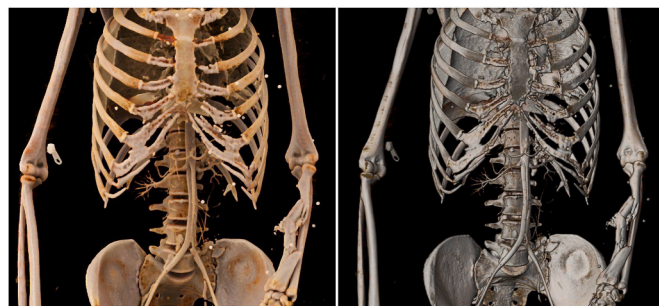

Fig. 1. Image example questionnaire group “number of bone injuries”: Left: CRT - Right: VRT.

### 2.3. Establishment of the online questionnaires

The reconstructions were divided into three categories:

In the ‘number of bone injuries’ question group (two questions; Fig. 1), participants were shown a picture of a skeleton embedded in two questions in which they were asked to indicate the number of bone injuries they had seen in whole numbers.

For the ‘Imagining the location of the pathology’ questions (six questions; Fig. 2), participants were asked to rate the pathology shown between ‘not imaginable/understandable’ and ‘very imaginable/understandable’ on a 5-point Likert scale.

In the final set of questions, ‘life-threatening assessment’ (three questions; Fig. 3), participants were asked to rate the life-threateningness of the pathology seen in the images. They were given a 4-point Likert score-like scale with ‘not life-threatening’, ‘abstract life-threatening’, ‘concrete life-threatening’ and ‘probable cause of death in this case’ (see full questionnaire in Appendix 1).

The questionnaires were then constructed using the online tool [www.limesurvey.org](http://www.limesurvey.org). Two questionnaires were created, one with the CRT images and one with the VRT reconstructions, with the same questions per image. To be able to evaluate the images separately by software, only images from the VRT software were used in one of the questionnaires. The second questionnaire contained only images created by the cinematic rendering technique. This allowed an evaluation without the participants being biased by the direct software comparison. The questionnaires were then sent to forensic pathologists, lawyers and police officers from the “law enforcement” or “criminal investigation” departments. The minimum number of participants per professional group was set at 15. The survey was randomised between VRT and CRT reconstructions. The questionnaires were available in three languages

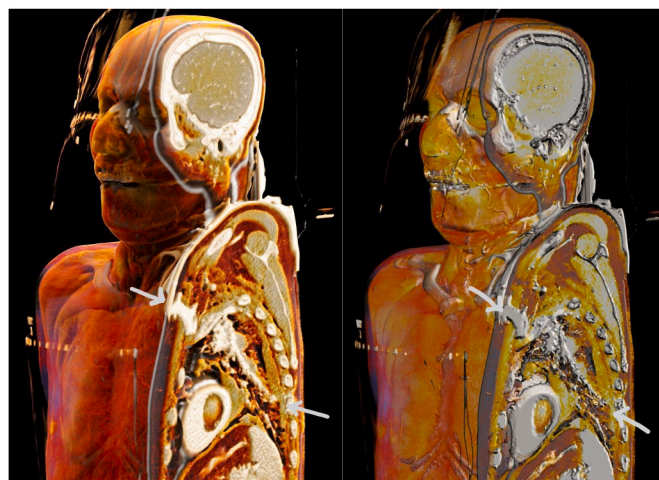


Fig. 2. Image example questionnaire group “imagination of the location of the pathology”; Left: CRT - Right: VRT.

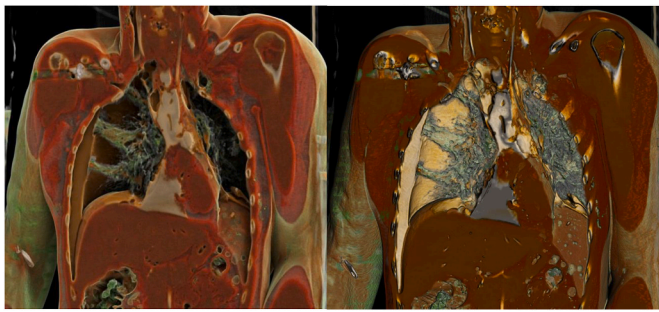


Fig. 3. Image example questionnaire group “life-threatening assessment”; Left: CRT - Right: VRT.

(English, French, German).

The survey was carried out between March 2021 and July 2021.

All questions and the structure of the questionnaire sent out can be found in [Appendix 1](#).

### 2.4. Statistical evaluation of the questionnaires

Only completed questionnaires were included in the analysis. These were divided into the two main groups (CRT and VRT) and two subgroups per software regarding the participating profession (physicians = “MD” and non-physicians = “nonMD”). The metric scale for the number of bone injuries question was estimated with a Poisson mixed effects model with ID and item as crossed random effects. The Likert scales for the questions on “imagining the location of a pathology” and “assessment of life-threatening” were estimated with a cumulative link mixed effects model with ID and item as crossed random effects.

In addition, the descriptive evaluation of the participants’ personal data (age, gender, professional group and professional experience) was carried out.

The data were also analyzed according to the item ‘professional experience’ regarding the topic of postmortem imaging.

“R” (version 4.1) was used to analyse the data. The figures were created with the “R” add-on package “ggplot2”.

### 3. Results

As the questionnaires were not sent personally, but were often passed on through secretariats, e.g. in the Crown Prosecution Service, a reliable

return rate cannot be given.

A total of n = 109 fully completed questionnaires were returned, of which almost half (51%, n = 56) showed the images produced by the CRT software, the others (49%, n = 53) were produced by the VRT software (see [Table 1](#)).

There was an imbalance between the professional groups. Only 32% (n = 18) of the CRT and 34% (n = 18) of the VRT questionnaires were completed by physicians (group “MD”; see [Table 1](#)). In the group of the medical laypersons most responses were from police officers (n = 26), judges (n = 23) and lawyers (n = 10). One person identified as a prosecutor. N = 14 stated that they belong to another non-medical profession.

#### 3.1. Item “experience with forensic radiology”

The question of whether there was a statistically significant difference between the responses of participants who answered ‘yes’ to the question of having had experience of forensic imaging could not be conclusively assessed due to the small number of positive responses. In total, only n = 20 (18%) of all participants indicated that they’d had experience with forensic imaging, which created a too important imbalance for statistical analysis.

#### 3.2. Item “professional group: MD vs. nonMD”

With regard to the four subgroups according to software tool and professional group (“CRT-MD”, “CRT-nonMD”, “VRT-MD”, “VRT-nonMD”), the results were rather heterogeneous depending on the question group.

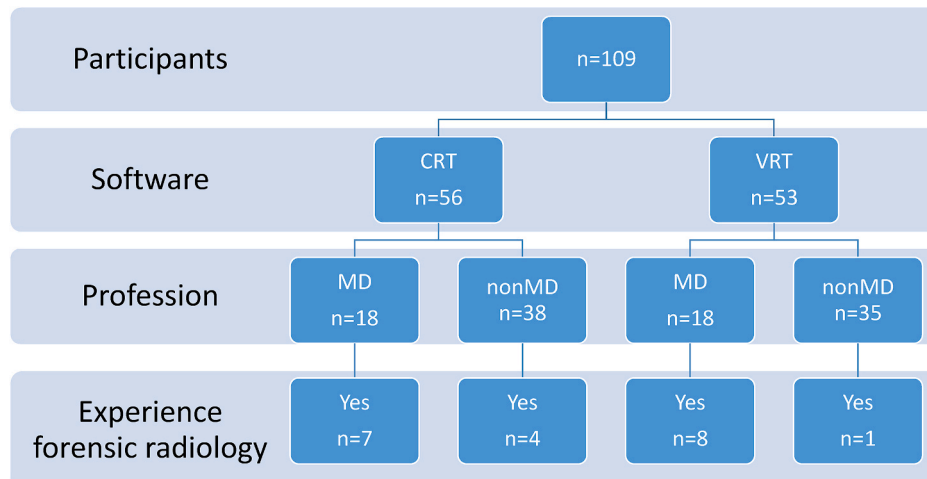
##### 3.2.1. Questionnaire group “number of bone injuries”

Here, only the “VRT-MD” group stood out significantly from the other participants (see [Fig. 4](#)). This group counted significantly (p = 0.004) fewer bone injuries (VRT-MD: mean = 2.65) than the other three groups (CRT-MD: mean = 3.54, CRT-nonMD: mean = 3.59, VRT-nonMD: mean = 3.99).

##### 3.2.2. Questionnaire group “imagining the location of the pathology”

In this question group, no differences were found between the subgroups of each software, but a significant difference (P < 0.001) was found between the two main groups regarding the software tools “CRT” and “VRT”. The images produced by the CRT software were rated as more imaginable and understandable than the VRT images, regardless of

**Table 1**  
Flow-chart of the evaluation of the participants.





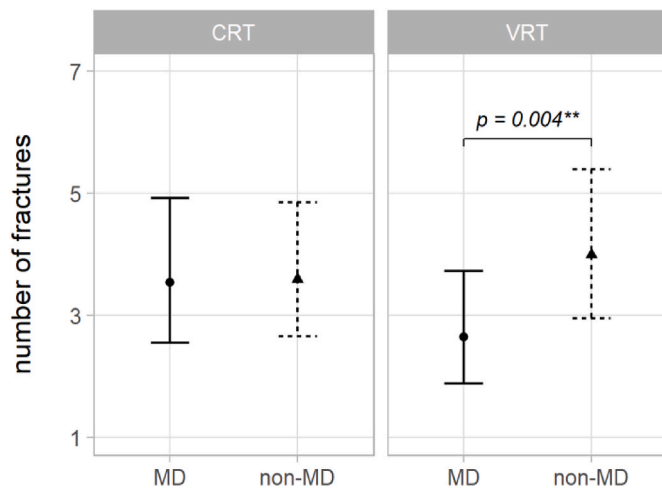


Fig. 4. Significant difference between MD and non-MD groups at the VRT software regarding the number of fractures.

profession (see Fig. 5).

### 3.2.3. Questionnaire group “life-threatening assessment”

For these questions, the differences between the “VRT-MD” and “VRT-non-MD” subgroups were significantly different (see Fig. 6). The images generated by the VRT software and assessed by the physicians were significantly ( $P = 0.001$ ) less life-threatening compared to the “VRT-nonMD” group. The differences between the other two subgroups (“CRT-MD” and “CRT-nonMD”) were not significant. There were also no differences between the main groups of the two software programs.

## 4. Discussion

CRT software is already more widely used in clinical radiology than in post-mortem imaging.<sup>15–18</sup>

A large number of positive case reports have already been published on various diseases and pathologies. In particular, surgeons with complex anatomical conditions could benefit from preoperative guidance images generated by Cinematic software.<sup>19</sup> Similarly, certain pathologies shown during interdisciplinary case discussions may be better understood by all participants if CRT is used to present the case.

Medical students in anatomy courses also appear to benefit from the visualisation of the human body using the more realistic light and shadow modalities.<sup>20</sup>

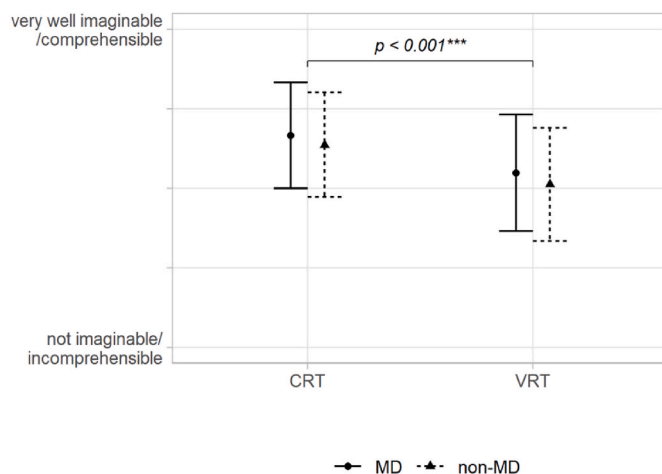


Fig. 5. Significant difference between the CRT and the VRT software regarding the imaginability/comprehensibility of the shown pathologies.

In post-mortem imaging, there are few publications to date that address the potential advantage of technological advances in imaging applications for PMCT and PMCTA. The published study by Böven et al., 2020<sup>21</sup> compared 2D-CT with three-dimensional imaging using CRT and VRT. They concluded that the CRT software was significantly more informative than the VRT software and 2D CT images. To reach this result, two forensic doctors examined the images and rated them on a 5-point Likert scale. In addition, the detectability of injuries in the different modalities was assessed by two radiologists. Due to the very small number of evaluators (two per question), this study may be a good indication of the superiority of CRT over VRT. These results need to be checked to see if they can be applied to lay persons.

Evaluation of the survey for an advantage of CRT software due to newer technical elements showed an overall slight advantage for the questions asked.

For the questions on the number of bone injuries seen, no explicit advantage of the cinematic rendering technique could be demonstrated. There was a wide range of answers, especially among the medical laypersons, and despite the more favourable light and shadow conditions, no significant difference in the number of injuries were found compared to the VR technique.

It is certainly not the responsibility of a prosecutor, for example, to find all the fractures in an anatomical context. But understanding these injuries and the images presented by experts in court is the basis for the forensic expert’s explanation of (in this case) the trajectory of the shots. With this knowledge and understanding, combined with 3D imaging, the court’s ability to make a correct legal interpretation of the nature of the violence is strengthened.

When asked to assess the life-threatening nature of an injury, there was also no statistically significant difference in the perceived pathology between the two software programs. When comparing the subgroups within the VRT software, there was an effect in the “non-MD” group, who rated the pathologies as significantly more dangerous. The higher resolution of CRT did not make the injuries appear more ‘dangerous’ to doctors, lawyers or police officers. Surprisingly, the well-known VRT software seems to have this effect. This may be due to the more realistic presentation using cinematic rendering technology. Doctors and medical laypeople can therefore perceive the danger of an injury on the same level, whereas this was not possible for the “non-MD” group using the VRT software. The consequence of a different perception of a traumatic injury can also affect the verdict in a court case.

When asked about the comprehensibility of pathology in Cinematic images, there was a significant difference in favour of CRT. This advantage was apparent not only to medical laypersons such as police officers, prosecutors, lawyers and judges, but also to the participating doctors themselves. As a result, judges, lawyers and prosecutors may be better able to follow the medical experts’ explanations when reviewing the injuries relevant to the case together.

Previous clinical and, in particular, forensic studies on the visualisation of pathology have consistently shown a certain advantage for CRT due to the technically more sophisticated representation of light and shadow in three-dimensional images. However, the advantage in post-mortem imaging is not as great as perhaps hoped for in the few pm-imaging studies discussed. The increased representation of shadows may obscure injuries that are not visible in the anterior part of the image, making them less visible than with the VRT software that has been used regularly to date. This is because VRT allows more posterior pathologies, such as fractures, to be seen in the same colour as injuries in the frontal part of the image.

Our study showed that, overall, forensic reports can be improved for medical laypersons by using CRT images.

Concerning the results, the significant difference between the CRT and VRT software in terms of the imaginability/comprehensibility of the pathologies shown in a postmortem CT-based angiography seems to be the greatest advantage of this new imaging technology. The benefits of Cinematic Rendering Technology are not limited to forensic physicians,

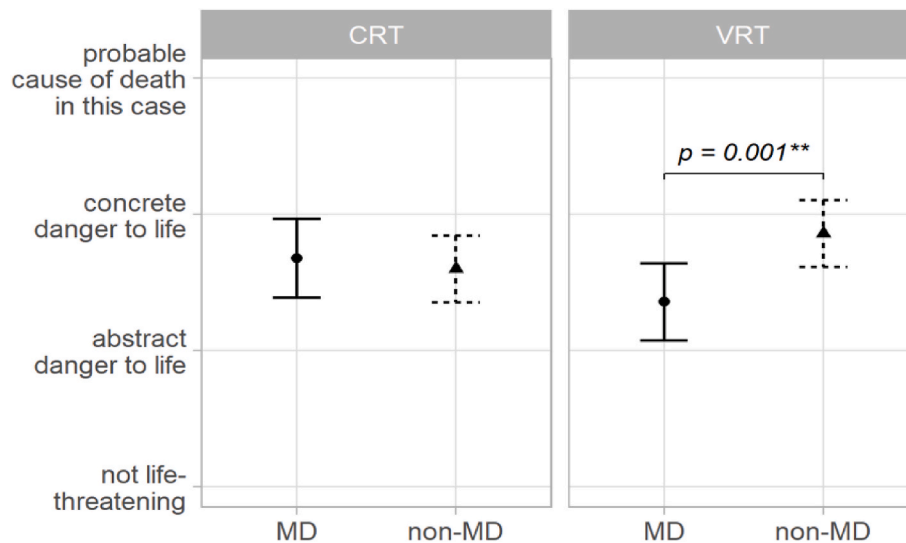


Fig. 6. Significant difference between the MD and non-MD group by rating the life threateningness.

but also to medical laypersons.

This software can help to reconstruct cases in a more comprehensible way and to better understand the severity of injuries after violent crimes for all professionals involved in a case.

Limitations of this study are the small study group with an uneven distribution of participants and the limited range of forensic cases presented. In addition, the small number of studies conducted to date, with a mainly clinical rather than forensic focus, results in less meaningful forensic experience with the new CRT software.

It is also important to consider that these visually impressive images may also mislead forensic and lay witnesses in court, as the focus may be lost on the important forensic question of the impact of violence.

Further research is needed to investigate the impact of the new technology, not only on the comprehension of forensic pathology, but also on the people involved in the legal process and their decision-making in a trial. In addition, research should be conducted to determine whether there are injuries to specific organs, soft tissues or bones that may particularly benefit from CRT software. Further research is also needed to determine whether there is a positive benefit from this 3D technology compared to conventional cross-sectional imaging and multi-planar reconstruction (MPR).

## 5. Conclusion

In this study, we found a slight advantage of the new Cinematic Rendering Technique (CRT) over the well-known Volume Rendering Technique (VRT) in our study population. The study showed a positive trend that CRT may be more understandable than VRT. Surprisingly, not only the medical laypersons participating in the study, but also the forensic physicians themselves found CRT to be beneficial. The use of Cinematic Rendering Technique could be beneficial in understanding forensically relevant injuries in court.

## Funding

No Fundings or grants.

## Data availability

The data records can be viewed on request by contacting the authors.

## Ethics approval

The responsible ethics committee (Cantone Vaud CER-VD No. 2022-00075) approved the retrospective evaluation and further processing of the data collected in routine.

## Declaration of competing interest

N/A.

## Appendix A. Supplementary data

Supplementary data to this article can be found online at <https://doi.org/10.1016/j.jflm.2024.102681>.

## References

- Grabherr S, Baumann P, Minoiu C, Fahrni S, Mangin P, eds. *Post-Mortem Imaging in Forensic Investigations: Current Utility, Limitations, and Ongoing Developments*. 2016.
- Guareschi E. *Postmortem Imaging in Forensic Cases*. 2021:79–93.
- Bornik A, Heinze S, Campana L, et al. Theoretische Grundlagen der forensischen Bildgebung. *Rechtsmedizin*. 2019;29(1):1–12.
- Grabherr S, Doenz F, Steger B, et al. Multi-phase post-mortem CT angiography: development of a standardized protocol. *Int J Leg Med*. 2011;125(6):791–802.
- Flach PM, Gascho D, Schweitzer W, et al. Imaging in forensic radiology: an illustrated guide for postmortem computed tomography technique and protocols. *Forensic Sci Med Pathol*. 2014;10(4):583–606.
- Norbetti N, Tonelli P, Giacconi C, et al. State of the art in post-mortem computed tomography: a review of current literature. *Virchows Arch*. 2019;475(2):139–150.
- Grabherr S, Heinemann A, Vogel H, et al. Postmortem CT angiography compared with autopsy: a forensic multicenter study. *Radiology*. 2018;288(1):270–276.
- Shokry DA, Hussein MN, Hassan FM, Heinemann A, Vogel H, Püschel K. Diagnostic value of multiphase postmortem computed tomography angiography in selected cases of blunt traumatic deaths. *Leg Med*. 2018;34:1–6.
- Eid M, De Cecco CN, Nance Jr JW, et al. Cinematic rendering in CT: a novel, lifelike 3D visualization technique. *AJR Am J Roentgenol*. 2017;209(2):370–379.
- Glemser PA, Engel K, Simons D, Steffens J, Schlemmer HP, Orakcioglu B. A new approach for photorealistic visualization of rendered computed tomography images. *World Neurosurg*. 2018;114:e283–e292.
- Soyer P. Cinematic rendering: when virtuality comes true. *Diagn Interv Imaging*. 2019;100(9):465–466.
- Cinematic rendering for medical imaging [press release] <https://www.siemens-healthineers.com/medical-imaging-it/advanced-visualization-solutions/syngovia-cinematic2017>.
- Shelmerdine SC, Sebire NJ, Calder AD, Arthurs OJ. 3D cinematic rendering of fetal skeletal dysplasias using postmortem computed tomography. *Ultrasound Obstet Gynecol*. 2020.
- de Spiegeleire X, Vanhaebost J, Coche E. Post-mortem CT angiography of mesenteric vessels using cinematic rendering vision. *Diagn Interv Imaging*. 2019;100(9):533–534.
- Chu LC, Rowe SP, Fishman EK. Cinematic rendering of focal liver masses. *Diagn Interv Imaging*. 2019;100(9):467–476.

16. Chu LC, Rowe SP, Fishman EK. Cinematic rendering of skin and subcutaneous soft tissues: potential applications in acute trauma. *Emerg Radiol.* 2019;26(5):573–580.
17. Rowe SP, Chu LC, Zimmerman SL, Fishman EK. 3D CT cinematic rendering of mycotic aneurysms. *Emerg Radiol.* 2018;25(6):723–728.
18. Hakim A, Mosimann PJ. Intracranial arteriovenous malformation: cinematic rendering with digital subtraction angiography. *Radiology.* 2020;294(3):506.
19. Wollschlaeger LM, Boos J, Jungbluth P, et al. Is CT-based cinematic rendering superior to volume rendering technique in the preoperative evaluation of multifragmentary intraarticular lower extremity fractures? *Eur J Radiol.* 2020;126, 108911.
20. Binder JS, Scholz M, Ellmann S, et al. Cinematic rendering in anatomy: a crossover study comparing a novel 3D reconstruction technique to conventional computed tomography. *Anat Sci Educ.* 2021;14(1):22–31.
21. Böven J, Boos J, Steuwe A, et al. Diagnostic value and forensic relevance of a novel photorealistic 3D reconstruction technique in post-mortem CT. *Br J Radiol.* 2020;93(1112), 20200204.