



Unilateral patient specific total temporomandibular joint reconstruction plus contralateral mandibular sagittal split osteotomy - indications and functional outcomes in comparison to total temporomandibular joint reconstruction alone

Wenko Smolka^{*}, Ina Dewenter[✉], Paris Liokatis[✉], Carl-Peter Cornelius[✉], Katharina Obermeier[✉]

Department of Oral & Maxillofacial Surgery and Facial Plastic Surgery, University of Munich, LMU, Germany

ARTICLE INFO

Keywords:

Unilateral total temporomandibular joint replacement
Contralateral mandibular sagittal split osteotomy
TMJ

ABSTRACT

The purpose of this retrospective cohort study is to assess the indications for combining a unilateral total temporomandibular joint replacement (TTJR) with a contralateral mandibular sagittal split osteotomy (SSO) and to compare the functional outcomes with unilateral TTJR alone. Fourteen patients who received TTJR were divided into 2 groups according to whether an additional sagittal split osteotomy (and further ostotomies) had been performed. The indications for the SSO (and further bone corrections) were acquired or congenital mandibular asymmetry, dysgnathic skeletal deformities and malocclusion. Postoperative results (average follow up time = 25 months) of the entire patient cohort were as follows: jaw opening (maximal interincisal distance) ranged from 28 mm to 45 mm (mean 35 mm). Laterotrusion to the non-reconstructed side varied between 2 mm and 7 mm (mean 4.3 mm). Laterotrusion to the reconstructed side reached from 5 mm to 15 mm. Protrusion extended between 2 mm and 8 mm; The separate analysis for the two patient groups did not reveal significant functional differences. Our patient series confirmed that a combination of TTJR and contralateral SSO does not lead to any functional disadvantages. In patients with stable occlusion where unilateral TTJR is used as a kind of reconstruction after condylar resection contralateral SSO is usually not necessary.

1. Introduction

Patient-specific alloplastic total temporomandibular joint reconstruction (TTJR) is acknowledged as a promising treatment option to manage end-stage disease of the temporomandibular joint (TMJ). Consequently, there is a broad variety of indications for TTJR depending on the underlying disease. Common indications for TJR are degenerative disease, ankylosis, post-traumatic deformities, idiopathic condylar resorption, craniofacial deformities such as hemifacial microsomia, benign and malignant tumors as well as rheumatoid and juvenile idiopathic arthritis (Westermarck et al., 2011; Sidebottom and Gruber, 2013; Pruszyńska et al., 2024; Brown et al., 2020).

TTJR can be performed unilaterally or bilaterally depending on the involvement of one or both TMJs by the pathologic process. Irregularities in biomechanical loading and movement paths of unilateral TTJR

have been suspected of having adverse effects on the opposite side, since the TMJs are mutually interacting bicondylar diarthrodial joints due linked by the mandibular arch.

(Trento et al., 2025). In a ten-years prospective study Linsen et al. reported on the functional impact of a unilateral TTJR on the non-treated side employing an ultrasound tracking system. They found that 2 (5.1%) of 39 patients required a contralateral TTJR after 5 and 7 years, respectively, due to pain, impaired function and arthrosis (Linsen et al., 2021). Based on their results, bilateral TTJR is not required when the contralateral TMJ is healthy, since the contralateral TMJ seems to adapt to the TTJR kinematics.

Motion analysis of the jaw in six patients by Woodford et al. (2023) showed that unilateral TTJR was associated with jaw opening capacity within normal limits relative to healthy controls, but with reduced anterior movement, restricted protrusion and lateral excursions of the

^{*} Corresponding author. Department of Oral & Maxillofacial Surgery and Facial Plastic Surgery, University of Munich, Lindwurmstr. 2a, Munich, D-80337, Germany.

E-mail address: wenko.smolka@med.uni-muenchen.de (W. Smolka).

<https://doi.org/10.1016/j.jcms.2026.104539>

Received 23 December 2025; Received in revised form 16 February 2026; Accepted 9 March 2026

Available online 26 March 2026

1010-5182/© 2026 The Authors. Published by Elsevier Ltd on behalf of European Association for Cranio-Maxillo-Facial Surgery. This is an open access article under the CC BY license (<http://creativecommons.org/licenses/by/4.0/>).

artificial condyle.

A further kinematic study of the mandible by Zumbunn Wojczyńska et al. by means of a dynamic stereometric technique described clinically inapparent changes of the condylar motion and excursions. The clinical assessment however demonstrated that the movement of the unaffected contralateral joints in 7 patients with unilateral TTJR did not differ from the joints of a healthy control group (Zumbunn Wojczyńska et al., 2021).

Our study aimed to go a step further in addressing the question of the impact of SSO and additional osteotomies on the functional clinical outcomes regarding the mobility of the mandible in a group of complex conditions with mandibular/dentofacial deformities. A patient group undergoing a unilateral TTJR alone served as the control.

2. Patients and method

This study was approved by the institutional review board of the University Hospital of Munich (LMU Munich, Germany; No. 22-0306).

Between 2015 and 2025 14 patients (female $n = 9$; male $n = 5$) underwent unilateral TTJR with ($n = 6$) or without ($n = 8$) contralateral mandibular sagittal split osteotomy. The indications for TTJR were the following.

- posttraumatic condylar deformity $n = 5$,
- posttraumatic ankylosis $n = 1$,
- degenerative joint disease $n = 2$,
- inflammatory ankylosis $n = 1$,
- odontogenic keratocyst $n = 1$,
- hemifacial microsomia $n = 1$,
- osteosarcoma $n = 1$,
- idiopathic condylar resorption $n = 1$ and
- juvenile idiopathic arthritis $n = 1$.

The age ranged from 18 to 64 years with a mean of 37 years. The mean follow-up was 25 months (range: 7 months – 92 months). Demographic data of patients are shown in Table 1.

Data including all available pre- and postoperative documents and radiographs were analyzed retrospectively. During follow up data on peri- and postoperative complications such as screw loosening, wound infection, wound dehiscence, malocclusion, sagging of the alloplastic component, allergic reaction or loss of prosthesis were evaluated with a focus on the mandibular movements.

Eight patients were reconstructed using a TTJR on the left side and 6 on the right side. The majority of the prostheses were TMJ concepts®/Stryker® ($n = 11$). In the remaining 3 cases one Materialise® prosthesis, one ZimmerBiomet® prosthesis ($n = 1$) and one KLS Martin prosthesis® were used. Six patients underwent simultaneous contralateral mandibular SSO. Miniplate fixation for osteosynthesis of the SSO was used in one case, lag screw fixation in 2 cases and patient-specific plates in 3

cases.

For virtual planning and CAD/CAM production of the TTJR, each patient received a high-resolution (0.625 mm slice) computed tomography (CT) of the facial skeleton, and plaster models and occlusal scans of the dental arch were produced.

The resulting DICOM data from the CT scans and the stereolithography (STL) data from the occlusal scans were sent to industrial partners for subsequent virtual surgical planning.

The first planning step was to determine the natural head position according to the Frankfurt horizontal line in the sagittal plane and to both infraorbital rims in the frontal plane. In a second step the facial skeleton was examined for skeletal asymmetry by cephalometric analysis, occlusal plane analysis, analysis of maxillary and mandibular pitch, role and yaw as well as measurement of maxillary and mandibular width. In case of a skeletal deformity virtual orthognathic surgery - including contralateral SSO and Le Fort I osteotomy if required - was performed prior to the virtual planning of the TTJR.

According to this decision-making process 6 patients were identified for the need of contralateral SSO including 3 patients with additional Le Fort I osteotomy for correction of occlusal plane canting. In the remaining 8 patients virtual planning of TTJR was performed without previous virtual planed orthognathic surgery.

In the group of 6 patients with TTJR plus contralateral SSO, laterognathia was present in 5 cases with a mean midline deviation of the mandible of 7 mm (3 - 18 mm) (Table 2). Severe class II deformity was found in 3 patients with an ANB angle of 9°, 12° and 13° and an occlusal plane canting of 5°, 10° and 17°, respectively. Increased mandibular width of 8 mm in the region of the first molars was present in one patient with posttraumatic deformity and an open bite of 8 mm was found in a patient with an idiopathic condylar resorption. In group 2 no skeletal deformities were detected.

The cohort of 14 patients was divided into two groups. Group 1 consisted of patients with TTJR plus simultaneous contralateral mandibular SSO. Group 2 served as a control including patients with TTJR without contralateral mandibular SSO.

Patients of group 1 (TTJR plus contralateral SSO) were compared to those of group 2 (TTJR alone) in terms of indication, maximum jaw opening, laterotrusion to non-reconstructed and reconstructed side as well as maximum protrusion.

Because of the small number of patients in this cohort no statistical tests were performed.

3. Results

Group 1 consisted of 6 patients. Three patients had a posttraumatic joint deformity. The other 3 patients suffered from hemifacial microsomia, idiopathic condylar resorption and inflammatory ankylosis. All six patients presented with a malocclusion and dysgnathia as described before.

Table 1
Demographic data.

Patient No	age	diagnosis	follow up	malocclusion	contralateral SSO	le fort osteotomy	sex	TJR
1	64	idiopathic resorption	26	yes	yes	no	f	Stryker
2	18	hemifacial microsomia	51	yes	yes	yes	f	TMJ concepts
3	41	inflammatory ancylosis	25	yes	yes	yes	m	TMJ concepts
4	30	posttraumatic deformaty	12	yes	yes	no	f	TMJ concepts
5	38	posttraumatic deformaty	12	yes	yes	yes	f	TMJ concepts
6	23	posttraumatic deformaty	10	yes	yes	no	m	TMJ concepts
7	40	posttraumatic deformaty	92	no	no	no	m	TMJ concepts
8	24	posttraumatic deformaty	24	no	no	no	f	Stryker
9	50	posttraumatic ancylosis	31	no	no	no	m	ZimmerBiomed
10	30	degenerative joint disease	16	no	no	no	f	ZimmerBiomed
11	48	degenerative joint disease	22	no	no	no	f	Stryker
12	55	benign lesion (keratocyst)	12	no	no	no	m	TMJ concepts
13	18	malignant lesion (osteosarcoma)	16	no	no	no	f	TMJ concepts
14	51	juvenile idiopathic arthritis	7	no	no	no	f	KLS Martin

Table 2
Preoperative dysgnathic findings of patients of group 1.

Patient No.	laterognathia (midline deviation of mandible)	skelatal class II deformaty	occlusal plane canting	open bite (interincisal distance)	increased Mandibular width (first molar region)
1	3 mm	non	non	8 mm	non
2	18 mm	ANB 13	10°	non	non
3	3 mm	non	17°	non	non
4	5 mm	ANB 9	non	non	non
5	non	non	5°	non	non
6	6 mm	ANB 12	non	non	8 mm

Group 2 consisted of 8 patients. In this group, 2 patients had post-traumatic joint deformities and further 2 degenerative joint disease. One patient suffered from juvenile idiopathic arthritis and one from post-traumatic ankylosis. In the 2 remaining cases the condylar process needed to be resected due to benign (keratocyst) and malignant tumor-related lesions (osteosarcoma). The main reason for treatment in patients with posttraumatic joint deformities, degenerative joint disease and juvenile idiopathic arthritis was severe joint pain and restricted jaw opening. In the case of posttraumatic ankylosis severely limited jaw movements and interincisal opening were the main indication for TTJR. None of the patients presented with a malocclusion or dysgnathia.

Complications such as screw loosening, wound infection, wound dehiscence or malocclusion were not observed. One patient of the control group with an odontogenic keratocyst who underwent reconstruction of the resected ramus and condylar process with TTJR, developed sagging of the mandibular component, which could be resolved by resuspending using a facia lata graft. In another patient of group 2 with degenerative joint disease allergic reaction to the cobalt-chromium-molybdenum alloy of the head component of the TTJR (Materialise) caused severe preauricular swelling and pain. The device was removed and replaced by a TTJR of pure titanium (ZimmerBiomet). Subsequently the symptoms subsided.

For functional assessment mandibular movements were evaluated 6 months postoperatively.

Box plots were generated to visualize and directly compare the distribution of the measurements in both groups (Fig. 1).

Jaw opening in all patients (n = 14) ranged from 28 mm to 45 mm

with a mean of 35 mm. No pronounced differences were observed between the groups: in group 1 (n = 6) values fell within a range of 28 mm to 45 mm (mean 36 mm), while in group 2 (n = 8) between 34 mm and 45 mm (mean 38 mm).

Laterotrusion to the non-TTJR side in all patients (n = 14) ranged from 2 mm to 7 mm with a mean of 4.3 mm. Laterotrusion to the reconstructed side ranged from 5 mm to 15 mm with a mean of 7.9 mm. Hence, the range of mandibular movement toward the reconstructed side was within the range of healthy individuals (Buschang, 2001) whereas, the range of mandibular movement toward the non-reconstructed side was limited compared to healthy individuals.

Laterotrusion per group:

Laterotrusion toward the non-reconstructed side in group 1 (n = 6) ranged from 2 mm to 6 mm with a mean of 4 mm. Laterotrusion toward the non-reconstructed side in group 2 (n = 8) ranged from 3 mm to 7 mm with a mean of 4.5 mm. Laterotrusion toward the reconstructed side in group 1 (n = 6) ranged from 6 mm to 15 mm with a mean of 7.7 mm. Laterotrusion toward the reconstructed side in group 2 (n = 8) ranged from 5 mm to 12 mm with a mean of 8 mm. Comparing the box plots, there was no marked differences in the extent of laterotrusive movements in both groups.

Protrusion of all patients (n = 14) ranged from 2 mm to 8 mm with a mean of 4.2 mm. Hence, protrusion of patients with unilateral TTJR was reduced compared to healthy individuals (Buschang et al., 2001). In group 1 (n = 6), protrusion ranged from 3 mm to 8 mm with a mean of 4 mm. In group 2 (n = 8), protrusion rom 2 mm to 6 mm with a mean of 4.4 mm. Comparing box plots of both groups, no difference in the range

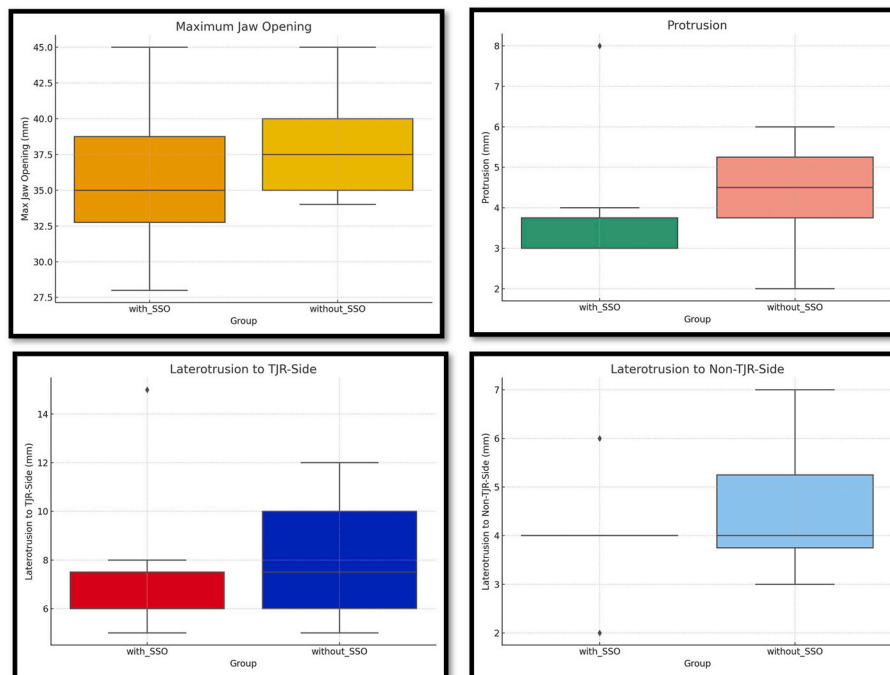


Fig. 1. Box plots of mandibular movements in both groups.

of protrusion was found.

In group 1 midline deviation of the mandible in patients with laterognathia could be successfully corrected by TTJR plus contralateral SSO in all cases. Open bite and increased mandibular width in two cases of the same group were also completely corrected by the surgical procedure. Correction of severe class II deformity in 3 patients of group 1 was also fully treated by TTJR plus contralateral SSO. Presurgical ANB angle of 9°, 12° and 13° could be reduced by surgery to 5°, 4° and 3°, respectively. Occlusal plane canting in 3 patients of group 1 was also successfully eliminated by the same surgical procedure.

4. Discussion

What happens biomechanically to the contralateral temporomandibular joint in patients with unilateral TTJR has been evaluated by Linsen et al. in a prospective cohort study of 39 patients (Linsen et al., 2017). They found that contralateral condylar motion, laterotrusion and protrusion decreased while jaw opening increased. Interestingly 2 (5.1%) of the patients required contralateral TTJR after a minimum follow-up of 5 and 7 years. The authors concluded that bilateral TTJR is not required when the contralateral TMJ is healthy. The contralateral TMJ seems to adapt to the TTJR kinematics. The authors assume further studies to be necessary to confirm that overload of the contralateral TMJ is not caused by unilateral TTJR. If contralateral mandibular SSO has an influence on the kinematics of the healthy contralateral TMJ has not been evaluated. Hence, there is a need for further investigations.

Kinematics were assessed in patients with unilateral TTJR using optoelectronic systems and dynamic stereometry techniques (Zumbrunn Wojczyńska et al., 2021; Woodford et al., 2023). Reduction in anterior movement of the prosthetic condyle and, therefore, reduced protrusion and lateral excursions were found, while the range of movement of the healthy joint did not differ from that of the healthy control group. Jaw opening of patients with unilateral TTJR was within the range of healthy individuals. Hence, patients with unilateral TTJR have a good jaw opening and good laterotrusion toward the side of the TTJR because this movement is mainly dependent on the movement of the healthy joint. Whereas protrusion and laterotrusion to the non-reconstructed joint is reduced due to the restrictions of movement of the prosthetic joint. Similar results were found in the present study. Furthermore, in the present study there were no differences in the range of mandibular movements in patients without SSO of the non-reconstructed side compared to those patients with SSO of the non-reconstructed side.

In the present study, the indication for performing a contralateral SSO was determined on the presence of malocclusion and dysgnathia. The degree/extent of these deformities was assessed through preoperative virtual surgical planning and patients were managed according to the severity of these findings, i.e. allocated to one of the two groups.

The skeletal deformities indicating a TTJR plus contralateral SSO were mandibular midline deviation, severe class II deformity distinct occlusal plane canting, increased transversal mandibular width and circular open bite. In general, all patients of group 1 had a major dysgnathia in addition to the end stage disease of the TMJ. From the outset, it was clear that the deformities requiring a TTJR in combination with contralateral SSO could be attributed to specific disorders.

The characteristics associated with each of the disorders occurring in this study are discussed in detail below.

Sidebottom and Gruber reported on 35 patients with degenerative temporomandibular joint disease who underwent unilateral TTJR (Sidebottom and Gruber, 2013). In 2 of them, orthognathic surgeries including contralateral SSO were performed to correct the skeletal Class II deformity. The majority of patients were successfully treated with TTJR without contralateral SSO.

In our study, both patients with degenerative temporomandibular joint disease underwent TTJR without contralateral SSO with satisfying results in terms of jaw opening and pain. It may be concluded that patients with degenerative temporomandibular joint disease usually do not

require a contralateral SSO unless there is a need to correct accompanying skeletal deformities.

The term posttraumatic TMJ deformities encompasses various disorders occurring at different sites, limited either to the joint area/condylar process or extending to the non-condylar (single or plural) regions of the mandible as well as the maxillae.

In 2 of the 5 patients in our study, the posttraumatic TMJ deformity was locally confined concurrent with a stable occlusion and thus a unilateral TTJR without additional osteotomies was considered sufficient in accordance with Pruszyńska et al. (Pruszyńska et al., 2024). Three of the study patients presented with more extensive mandibular deformities. These dysgnathic deformities required a mandibular advancement by means of a bilateral approach – unilateral TTJR with a personalized/custom designed prosthetic component in combination with a contralateral SSO (Keyser et al., 2020).

Primary treatment for patients with juvenile idiopathic arthritis is systemic medication (antirheumatic drugs, immunosuppression) (Brown et al., 2020). In select cases developing chronic TMJ changes, prosthetic joint replacement may represent a reasonable surgical option in end-stage conditions. Avoidance of surgical relapse makes alloplastic TTJR a considerable alternative compared to autogenous graft reconstruction (Brown et al., 2020; Lypka et al., 2020). In their respective series with a majority of bilateral cases Brown et al. and Lypka et al. each reported only of 1 patient with a unilateral TTJR. Presumably Brown et al. left the contralateral joint untreated, while Lypka et al. performed a TTJR in combination with a contralateral SSO due to malocclusion and mandibular asymmetry in his patient. Our patient (group 2) had localized joint destruction but neither malocclusion nor mandibular asymmetry. The main symptoms were pain and limited jaw movements. In line with these findings, only the affected condyle was resected and replaced with TTJR.

Treatment with TTJR after resection of pathologies confined to one mandibular condyle was reported by Schlabe et al. (2023). Among the 12 patients prevailed benign tumors: ameloblastoma $n = 6$, keratocyst ($n = 1$), odontogenic myxoma ($n = 1$), osteochondroma ($n = 1$). Given the strictly unilateral involvement of the condylar/process ramus region with preserved dental occlusion, unilateral TTJR was performed and no procedure at the opposite side.

Our case with an odontogenic keratocyst principally corresponded to the described technique, while the TTJR was inserted immediately after the tumor resection.

Temporomandibular joint ankylosis is a severe joint disease that is mainly caused by trauma or infection. When it occurs in childhood, skeletal deformities may develop (Huang et al., 2024).

The only treatment modality for temporomandibular joint ankylosis is surgery with TTJR being a promising option. In concurrent jaw deformities (asymmetry, hemimandibular hypoplasia, occlusal canting) simultaneous contralateral SSO is usually required.

Seven patients in a recent study diagnosed with unilateral temporomandibular joint ankylosis and jaw deformity were successfully treated by simultaneous orthognathic surgery in a mandible first sequence with ankylosis release, TTJR and a contralateral SSO followed by a Le Fort I osteotomy (Huang et al., 2024).

The present study examined one patient with temporomandibular joint ankylosis caused by infection during childhood, who had developed a severe facial deformity and was therefore treated according to the concept described above – TTJR, contralateral SSO and Le Fort I osteotomy.

If a temporomandibular joint ankylosis occurs in adult life, it usually does not lead to a deformity. Thus, no additional orthognathic surgery is necessary (Mani et al., 2020). One patient with traumatic temporomandibular joint ankylosis after an injury sustained in adulthood in our cohort showed no associated jaw deformity. The treatment in his case was limited to the affected joint, consistent with the aforementioned authors.

TTJRs have been described in the restoration of major TMJ

deformities and associated mandibular defects in patients with congenital mandibular hypoplasia, in cases where the autogenous grafts or revascularized transplants were considered unsuitable (Westermark et al., 2011; Zimmerer et al., 2023; Pinto et al., 2023).

Zimmerer and co-authors presented 2 hemifacial microsomia (HFM) cases. Both patients were treated with TTJR and simultaneous orthognathic surgery such as contralateral SSO and Le Fort I osteotomy, to achieve facial symmetry and normal occlusion (Zimmerer et al., 2023). Pinto et al. reported on a case of HFM using the same treatment protocol (Pinto et al., 2023).

In addition to the TTJRs, HFM cases required simultaneous orthognathic surgery, such as SSO or mandibular body osteotomies, and Le Fort I osteotomy, for achieving facial symmetry and functional occlusion. (Westermark et al., 2011).

In the HFM case in the present study, the contralateral SSO was part of the treatment, as revealed already during the preoperative virtual planning and successively implemented thereafter.

Limitations of the study are the small number of patients due to the monocentric study design as well as the heterogeneity of the cohort, which is related to the fact that various kinds of TMJ end-stage disease require TTJR.

5. Conclusion

There are no differences in mandibular movements and function of patients who received unilateral TTJR without contralateral SSO and patients that underwent unilateral TTJR with contralateral SSO. Our series confirms that a combination of TTJR and contralateral SSO does not lead to any obvious functional limitations. In patients with a stable occlusion where a unilateral TTJR is used as a kind of reconstruction after condylar resection, contralateral SSO is usually not necessary.

Patient consent

Not required.

Ethical approval

This study adhered to the principles of the Declaration of Helsinki in terms of medical protocols and ethics.

Funding

This study was not funded.

Competing interests

The authors have no conflicting interests to disclose.

References

- Brown, Z., Rushing, D.C., Perez, D.E., 2020. Alloplastic temporomandibular joint reconstruction for patients with juvenile idiopathic arthritis. *J. Oral Maxillofac. Surg.* 78 (9), 1492–1498. <https://doi.org/10.1016/j.joms.2020.05.006>.
- Huang, D., Zou, L., Lu, C., Zhao, J., He, D., Yang, C., 2024. Simultaneous standard total joint prosthesis reconstruction with SSRO and Le Fort I osteotomy in the treatment of unilateral temporomandibular joint ankylosis with jaw deformity: a case cohort study. *Clin. Oral Invest.* 28 (3), 163.
- Keyser, B.R., Banda, A.K., Mercuri, L.G., Warburton, G., Sullivan, S.M., 2020. Alloplastic total temporomandibular joint replacement in skeletally immature patients: a pilot survey. *Int. J. Oral Maxillofac. Surg.* 49 (9), 1202–1209. <https://doi.org/10.1016/j.ijom.2020.02.001>.
- Linsen, S.S., Schön, A., Mercuri, L.G., Unilateral, Teschke M., 2021. Alloplastic temporomandibular joint reconstruction, biomechanically what happens to the contralateral temporomandibular Joint?—A prospective cohort study. *J. Oral Maxillofac. Surg.* 79 (10), 2016–2029. <https://doi.org/10.1016/j.joms.2021.01.025>.
- Lypka, M., Shah, K., Jones, J., 2020. Prosthetic temporomandibular joint reconstruction in a cohort of adolescent females with juvenile idiopathic arthritis. *Pediatr Rheumatol Online J* 18 (1), 68. <https://doi.org/10.1186/s12969-020-00453-6>.
- Mani, B., Balasubramaniam, S., Balasubramanian, S., Jayaraman, B., Thirunavukkarasu, R., 2020. Role of custom-made prosthesis for temporomandibular joint replacement in unilateral ankylosis - an evaluative study. *Ann Maxillofac Surg* 10 (2), 344–352. <https://doi.org/10.4103/ams.ams.132.20>.
- Pinto, L.A.P.F., Lima, B.C., Coutinho, M.A., Ramos, V.F., 2023. Temporomandibular joint patient specific implant as treatment for hemifacial microsomia. *Natl. J. Maxillofac. Surg.* 14 (3), 515–518. <https://doi.org/10.4103/njms.njms.14.22>.
- Pruszyńska, P., Kozakiewicz, M., Szymor, P., Wach, T., 2024. Personalized temporomandibular joint total alloplastic replacement as a solution to help patients with non-osteosynthesizable comminuted mandibular head fractures. *J. Clin. Med.* 13 (17), 5257. <https://doi.org/10.3390/jcm13175257>.
- Schlabe, J., Davies, R.O.H.L., Aagaard, E., Cousin, G., Edwards, A.I., McAlister, K., Cascarini, L., 2023. Extended total temporomandibular joint replacement - a feasible option for functional and aesthetic reconstruction of mandibular defects involving the temporomandibular joint. *Craniofacial Trauma Reconstr.* 16 (3), 180–194. <https://doi.org/10.1177/19433875221094971>.
- Sidebottom, A.J., Gruber, E., 2013. One-year prospective outcome analysis and complications following total replacement of the temporomandibular joint with the TMJ concepts system. *Br. J. Oral Maxillofac. Surg.* 51 (7), 620–624. <https://doi.org/10.1016/j.bjoms.2013.03.012>.
- Trento, G., Parize, H., Bohner, L., Oelerich, O., Jung, S., Kleinheinz, J., 2025. Can a unilateral total temporomandibular joint prosthesis affect the healthy contralateral temporomandibular joint? A systematic review. *Int. J. Oral Maxillofac. Surg.* 54 (1), 65–73. <https://doi.org/10.1016/j.ijom.2024.10.001>. Epub 2024 Oct 11.
- Westermark, A., Hedén, P., Aagaard, E., Cornelius, C.P., 2011. The use of TMJ concepts prostheses to reconstruct patients with major temporomandibular joint and mandibular defects. *Int. J. Oral Maxillofac. Surg.* 40 (5), 487–496. <https://doi.org/10.1016/j.ijom.2010.12.007>.
- Woodford, S.C., Robinson, D.L., Abduo, J., Lee, P.V.S., Ackland, D.C., 2023. Kinematics of the jaw following total temporomandibular joint replacement surgery. *J. Biomech.* 159, 111741. <https://doi.org/10.1016/j.jbiomech.2023.111741>.
- Zimmerer, R.M., Sander, A.K., Schönfeld, A., Lethaus, B., Gellrich, N.C., Neuhaus, M.T., 2023. Congenital mandibular hypoplasia: patient-specific total joint replacement as a line extension in the treatment of complex craniofacial anomalies. *J. Maxillofac. Oral Surg.* 22 (2), 410–418. <https://doi.org/10.1007/s12663-022-01780-9>.
- Zumbrunn Wojczyńska, A., Markova, M., Ettlin, D.A., Gallo, L.M., Colombo, V., 2021. In-vivo kinematic assessment of alloplastic temporomandibular joint replacements by means of helical axis: a cohort study with historical control. *J. Biomech.* 122, 110494. <https://doi.org/10.1016/j.jbiomech.2021.110494>.