

K.C. Huth^{1*}, E. Paschos¹,
N. Hajek-Al-Khatat¹, R. Hollweck²,
A. Crispin³, R. Hickel¹, and M. Folwaczny¹

¹Department of Restorative Dentistry & Periodontology, Dental School, Ludwig-Maximilians-University, Goethestrasse 70, 80336 Munich, Germany; ²Institute for Medical Statistics & Epidemiology, Klinikum rechts der Isar, Technical University, Munich, Germany; and ³Department of Medical Informatics, Biometry & Epidemiology, Ludwig-Maximilians-University, Munich, Germany; *corresponding author, khuth@dent.med.uni-muenchen.de

J Dent Res 84(12):1144-1148, 2005

ABSTRACT

Pulpotomy is the accepted therapy for the management of cariously exposed pulps in symptom-free primary molars; however, evidence is lacking about the most appropriate technique. The aim of this study was to compare the relative effectiveness of the Er:YAG laser, calcium hydroxide, and ferric sulfate techniques with that of dilute formocresol in retaining such molars symptom-free. Two hundred primary molars in 107 healthy children were included and randomly allocated to one of the techniques. The treated teeth were blindly re-evaluated after 6, 12, 18, and 24 months. Descriptive data analysis and logistic regression analysis, accounting for each patient's effect by a generalized estimating equation (GEE), were used. After 24 months, the following total and clinical success rates were determined (%): formocresol 85 (96), laser 78 (93), calcium hydroxide 53 (87), and ferric sulfate 86 (100). Only calcium hydroxide performed significantly worse than formocresol ($p = 0.001$, odds ratio = 5.6, 95% confidence interval 2.0-15.5). In conclusion, calcium hydroxide is less appropriate for pulpotomies than is formocresol.

KEY WORDS: pulpotomy, primary molars, RCT.

Effectiveness of 4 Pulpotomy Techniques— Randomized Controlled Trial

INTRODUCTION

Pulpotomy is the common therapy for cariously exposed pulps in symptom-free primary molars, its aim being to preserve the radicular pulp, to avoid pain and swelling, and, ultimately, to retain the tooth (Fuks, 2002). Although many techniques have been suggested (Ranly and García-Godoy, 2000), a recent Cochrane Review found that evidence is lacking as to which is the most appropriate technique (Nadin *et al.*, 2003). Dilute formocresol is regarded as the "gold standard" (King *et al.*, 2002), but concerns about cytotoxicity and potential mutagenicity have been reported (Lewis, 1998). Calcium hydroxide has been reported to cause internal resorption (Schröder, 1978). Ferric sulfate has been used recently, due to its hemostatic effect (Fuks, 2002). The Er:YAG laser has also been suggested as an alternative, due to its hemostatic, antimicrobial, and cell-stimulating properties (Matsumoto, 2000; Schoop *et al.*, 2002; Kimura *et al.*, 2003), with only slight thermal alteration to the pulpal tissue (Jayawardena *et al.*, 2001). Currently, there are no controlled clinical studies where this technique is being used. Reported according to the CONSORT statement (Moher *et al.*, 2001), the present study aimed to determine the relative effectiveness of these three techniques in comparison with that of dilute formocresol.

MATERIALS & METHODS

Participants

Participants were healthy children (≤ 8 yrs old), with at least 1 symptom-free, restorable primary molar with a cariously exposed vital pulp. Clinical exclusion criteria were spontaneous pain, swelling, tenderness to percussion, pathological mobility, and initially unsuccessful hemorrhage control. We excluded teeth with pre-operative radiographic pathology such as resorption, periradicular or furcal radiolucency, a widened periodontal ligament space, or physiological root resorption of more than one-third. Between November, 1999, and September, 2002, all children attending the Pedodontic Section, Department of Restorative Dentistry & Periodontology, University of Munich, and meeting the criteria were enrolled. After ethical approval (No. 281/99) and informed parental consent, two pedodontists performed the pulpotomies while the subjects were under local anesthesia or general anesthesia, without the additional use of local anesthetics.

Interventions

Dilute formocresol (1:5 Buckley's solution), Erbium:Yttrium-Aluminum Garnet (Er:YAG) laser, calcium hydroxide, and ferric sulfate (15.5%) were used as parallel intervention methods. In all groups, after rubber dam isolation and caries removal, the pulp chamber was opened with a sterile high-speed diamond bur, and the coronal pulp was removed by a sterile slow-speed round bur (#830RL016, #H1SE.204021, Brasseler, Lemgo, Germany) under continuous water irrigation. Control of complete removal of the coronal pulp tissue down to

the canal orifices was done by visual control and a sterile hand excavator in undercut areas. We controlled hemorrhage by placing sterile, saline-wetted cotton wool pellets on the radicular pulp stumps under slight pressure (Thompson *et al.*, 2001), waiting 5 min for primary hemostasis (Mielke *et al.*, 1969), followed by removal of blood clot remnants and drying the cavity. At this stage, the achievement of complete hemostasis was an inclusion criterion, before any of the 4 techniques was applied. When bleeding recommenced afterward, during placement of the medication or laser irradiation, the tooth was excluded from further follow-up.

Within the control group, formocresol-moistened pellets were placed on the pulp stumps for 5 min. Er:YAG laser radiation (wavelength, 2.94 μm) was delivered to the canal orifices with a special handpiece (KEY Laser 1242; handpiece 2051, KaVo, Biberach, Germany), with parameters set at 2 Hz and 180 mJ/pulse without water cooling (Keller and Hibst, 1991). The mean number of laser pulses *per* tooth was 31.5 ± 5.9 , equally distributed to each pulp stump. In the calcium hydroxide group, the canal orifices were dressed with aqueous calcium hydroxide (Calxyl[®], OCO Präparate GmbH, Dirmstein, Germany), slightly dampened and covered with a calcium hydroxide cement (Kerr[®] Life, Kerr GmbH, Karlsruhe, Germany). Ferric-sulfate-wetted pellets (Astringent[®], Ultradent Products Inc., Salt Lake City, UT, USA) were placed on the pulp stumps for 15 sec.

A reinforced zinc oxide eugenol base (IRM[®], Dentsply DeTrey, Konstanz, Germany) was then applied to the cavity floor, followed by a glass-ionomer cement (Ketac[™] Bond, 3M ESPE, Seefeld, Germany) and a stainless steel crown (SSC, 3M ESPE) or a composite resin restoration (CRR, Tetric[®] Ceram, Ivoclar Vivadent, Schaan, Liechtenstein).

Follow-up

Clinical re-evaluations at 6, 12, 18, and 24 mos \pm 2 wks, with additional radiographic examinations at 12 and 24 mos, were performed independently by two experienced dentists (not the operators) blinded to the technique, with forced consensus in cases of disagreement. The inter- and intra-examiner reproducibility was calculated by Cohen's unweighted kappa statistic (Altman, 1991). The flow of participants and pulpotomies was followed from allocation to the final data analysis after 24 mos (Fig.).

Hypothesis and Outcomes

Since we hypothesized that no difference in effectiveness exists between dilute formocresol and the 3 other techniques, the primary

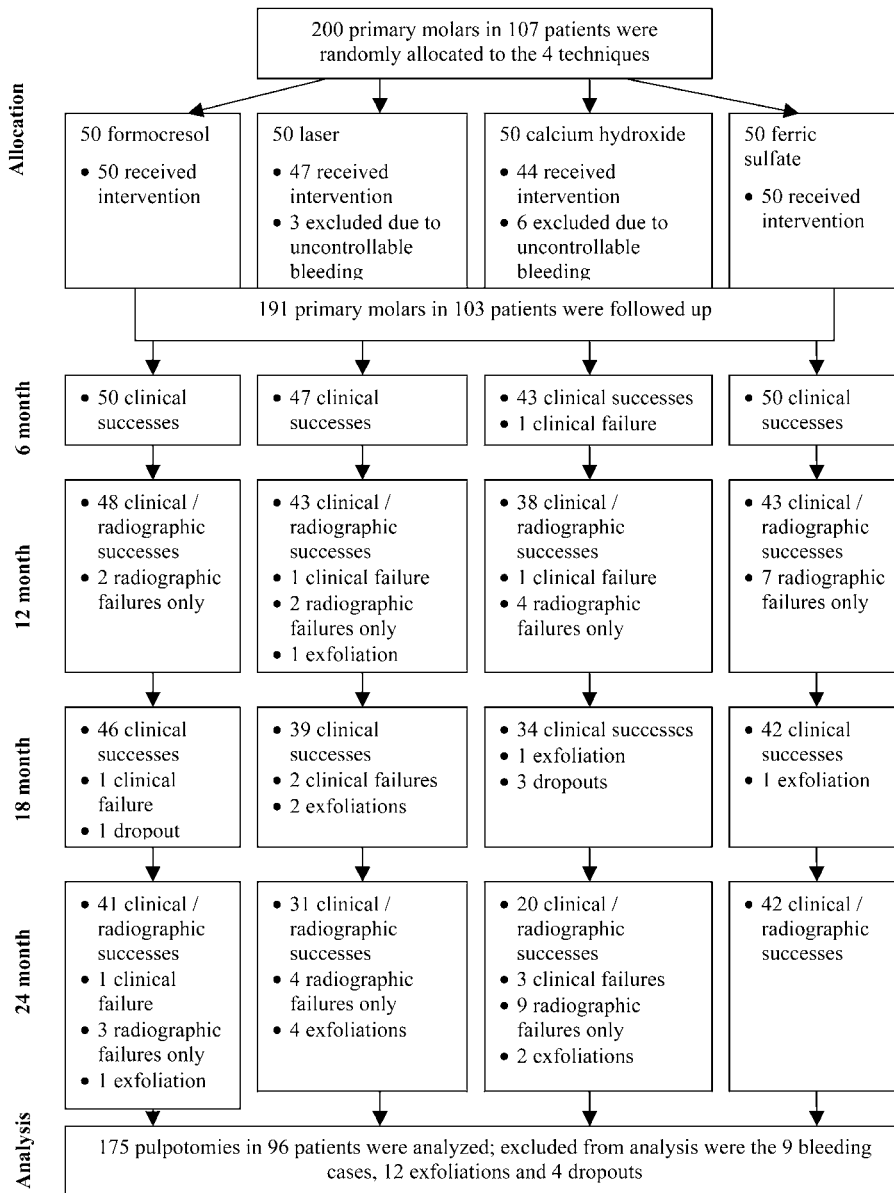


Figure. Flow of participants and pulpotomized teeth up to 24 mos.

endpoints were a clinically and radiographically symptom-free tooth at 12 and 24 mos \pm 2 wks. Clinical failure parameters were spontaneous pain, tenderness to percussion, fistula, soft-tissue swelling, and pathological tooth mobility. Radiographic failure parameters were periapical or furcal radiolucency, pathologic external or distinct internal root resorption, or widened periodontal ligament space. The restoration performance (partially or completely lost fillings, secondary caries at the margin, perforated or lost SSC crowns, severe gingival inflammation) was determined as a secondary outcome.

Sample Size and Power Calculation

The sample size calculation [PS Power and Sample Size Calculation Program, Version 2.1.31 (Dupont and Plummer, 1990)] was based on an internal pilot study comparing the success rates of calcium hydroxide (55.9%) and formocresol (90.1%)

(Benz *et al.*, 1998), and on a study comparing ferric sulfate (96.55%) and formocresol (77.78%) (Fei *et al.*, 1991). The first outcome difference led to a required sample size of 28 for the detection of a significant difference (80% power, two-sided 5% significance level), and the second to one of 50 *per* intervention group. For the Er:YAG laser group, no previous data for a sample size calculation were available. Therefore, a sample size of 50 in each intervention group was planned. Based on the results of the present study, a power analysis was performed (Dupont and Plummer, 1990).

Randomization and Blinding

Each tooth was randomly allocated to one of the 4 techniques by an assistant casting a concealed lot from a box containing 4 x 50 lots (block randomization) (Altman, 1991). All other contributors to the study were blinded to generation and implementation of the treatment assignment. The outcome assessment and data analysis were blinded, since the techniques were indistinguishable and coded.

Statistical Methods

During follow-up, a clinical failure was recorded if the pulpotomy failed due to clinical symptoms also showing radiographic pathology. Those with radiographic changes, but clinically symptom-free, were recorded separately. The total failure rate was comprised of the clinical and symptom-free radiographic failures.

The 12- and 24-month total and clinical success and failure rates of each pulpotomy technique were calculated according to the equation below (ADA, 2001). Additionally, the total success and failure rates for several parameters (type of anesthesia, two operators, tooth type, upper and lower jaw, final restoration) were calculated across all techniques:

$$\text{Failure Percentage} = 100\% \times \frac{(\text{previous failures} + \text{new failures})}{(\text{previous failures} + \text{currently recalled pulpotomies})}$$

We used a logistic regression model to analyze the differences in effectiveness between formocresol and each of the other procedures (α -level = 0.05) (Altman, 1991); odds ratios with 95% confidence interval (OR \pm 95% CI) were also given. Multiplicity and therefore dependence of more than one pulpotomy within a patient was accounted for within the statistical analysis by the

Table 1. Baseline Clinical Characteristics of the Study Sample

N*	Overall	FC	L	CH	FS
Pulpotomies	191	50	47	44	50
First molar	101	22	25	26	28
Second molar	90	28	22	18	22
Maxilla	78	21	17	20	20
Mandible	113	29	30	24	30
LA	97	26	23	21	27
GA	94	24	24	23	23
SSC	109	26	29	25	29
CRR	82	24	18	19	21
Operator 1	104	19	34	24	27
Operator 2	87	31	13	20	23

* N, number; LA, local anesthesia; GA, general anesthesia; SSC, stainless steel crown; CRR, composite resin restoration; FC, formocresol; L, laser; CH, calcium hydroxide; FS, ferric sulfate.

generalized estimating equation (GEE) (Liang and Zeger, 1986). Exchangeable correlation structure was used, since the correlation between any 2 pulpotomies was assumed to be the same across patients. We applied the Wald Chi-square test to test differences in overall effectiveness regarding the abovementioned parameters. All tests were performed two-tailed, with $p < 0.05$ indicating statistical significance. We used SAS version 9 (SAS Inc., Cary, NC, USA) to perform the analyses.

RESULTS

Allocated to the 4 techniques were 200 primary molars in 107 patients. Three teeth from the laser group and 6 from the calcium hydroxide group were excluded from follow-up and statistical analysis, due to uncontrollable bleeding during radiation or placement of calcium hydroxide, since a hyperemic, inflamed radicular pulp is considered a contraindication for vital pulpotomy (Fuks, 2002). Thus, 191 pulpotomized teeth (Table 1) in 103 patients (56 males, 47 females; mean age, 4.8 ± 1.6 yrs; range, 2-8 yrs) were re-evaluated. After 24 mos, 12 teeth had exfoliated physiologically, and 4 were lost to follow-up (drop-out of four patients who moved away), leaving 175 pulpotomies in 96 patients for the intention-to-treat statistical analysis (Fig.).

The clinical and radiographic inter-examiner reproducibility was optimal and good (Cohen's $\kappa = 1$, $\kappa = 0.80$), and the intra-examiner reproducibility was optimal for both the clinical and radiographical evaluations (Cohen's $\kappa = 1$).

The clinical and radiographic evaluation after 12 mos revealed the following total and clinical (placed parenthetically) success rates for the different methods (%): formocresol, 96 (100); laser, 93 (98); calcium hydroxide, 86 (95); and ferric sulfate, 86 (100). There was no significant difference in effectiveness between formocresol and any of the other techniques after 12 mos ($p > 0.05$) (Table 2).

After 24 mos, the differences in total and clinical success rates among the techniques became more distinct (%): formocresol, 85 (96); laser, 78 (93); calcium hydroxide, 53 (87); and ferric sulfate, 86 (100). However, compared with formocresol, only calcium hydroxide performed significantly worse ($p = 0.001$), the odds of failure being 5.6 (95% CI, 2.0-15.5) times higher than for the formocresol method. Although not significant, laser had an odds ratio of 1.7 compared with formocresol (95% CI, 0.6-5.2), and ferric sulfate an odds ratio of 1.0 compared with the gold standard (95% CI, 0.3-3.0) (Table 2).

Ten clinical failures and 31 radiographic failures without clinical symptoms were found within the 24-month evaluation period (Table 3).

Within the 24 mos, we found no differences in overall total success rates (%) between pulpotomies performed on subjects under either local or general anesthesia (83/70), by either operator 1 or operator 2 (78/75), in first or in second primary molars (74/80), in the maxilla or in the mandible (82/73), and with SSC or CRR as the final restoration (73/81) ($p > 0.05$).

Over 2 yrs, 3 out of 109 SSC were lost, but the cement base remained intact; there was 1 pulpotomy failure (formocresol). Of the 82 CRR, 13 fillings were unacceptable (3 totally lost, 3 partially lost, 7 with secondary caries), with 2 pulpotomy failures (laser, ferric sulfate).

No adverse events or side-effects were recognized during the study.

DISCUSSION

Only calcium hydroxide performed significantly worse than formocresol after 24 mos (rejection of the null hypothesis, power > 80%), but not due primarily to internal resorption (Table 3), as had been suggested (Schröder, 1978). The total failure rate of 47% was higher than rates reported for two previous studies (20% and 23%) (Gruythuysen and Weerheijm, 1997; Waterhouse *et al.*, 2000), but was comparable with reports from 2 studies showing failure rates of 41% and 43% (Schröder, 1978; Benz *et al.*, 1998).

The Er:YAG laser pulpotomies had a total success rate (78%) insignificantly lower than that of formocresol (85%) after 2 yrs. Since this laser type had not previously been used for pulpotomies in primary molars, its sample size had to be adapted from that calculated for ferric sulfate. From the data analysis, with a power of 15%, it became clear that the sample size was too small for us to answer this question: Does the non-significant result indicate that there is in fact no difference compared with formocresol?

A similar situation appeared when we compared the minimally different total success rate of ferric sulfate (86%) with that of formocresol (85%): No significance after 2 yrs was revealed (power 5%). Nevertheless, the success rate lies well between those previously reported: 61% after 2 yrs (Casas *et al.*, 2003) and 97% after 20 mos (Ibricevic and Al-Jame, 2000). The distinct difference between the clinical (100%) and total success rates (86%), observed not only here but also by others (Casas *et al.*, 2003), emphasizes the importance of regular radiographic control.

Dilute formocresol as the control technique in this study showed a total success rate (85%) that was comparable with those of previous studies reporting 84% after nearly 2 yrs (Fuks *et al.*, 1997; Waterhouse *et al.*, 2000).

Initial hemostasis was achieved in all 200 allocated teeth. However, 3 teeth allocated to the laser and 6 to the calcium hydroxide group were excluded from further follow-up, since uncontrollable bleeding recommenced during irradiation or placement of calcium hydroxide, indicating a hyperemic, inflamed radicular pulp. Aside from the use of non-medicated cotton pellets for primary hemostasis, the different mechanisms of bleeding control for the various applied techniques are interesting in this context: Formocresol fixes tissue in the coronal third of the radicular pulp and causes hemostasis by vessel thrombosis and impaired micro-circulation (Avram and Pulver, 1989; Ranly and García-Godoy, 2000; Thompson *et al.*, 2001). The pulp's microcirculation after irradiation with the Er:YAG laser, adjusted as here,

Table 2. Twelve- and 24-month Total and Clinical Success and Failure Rates and Results of the Statistical Analysis

	Formocresol	Laser	Calcium Hydroxide	Ferric Sulfate
Total success rate (%) ^a				
12 mos	96	93	86	86
24 mos	85	78	53	86
Total failure rate (%)				
12 mos	4	7	14	14
24 mos	15	22	47	14
Clinical success rate (%)				
12 mos	100	98	95	100
24 mos	96	93	87	100
Clinical failure rate (%)				
12 mos	0	2	5	0
24 mos	4	7	13	0
Relative effectiveness (logistic regression model with GEE, p)				
12 mos	reference	n.s.	n.s.	n.s.
24 mos	reference	n.s.	0.001 ^s	n.s.
Odds ratio ± 95% CI				
12 mos	reference	1.6 (0.3-9.0)	3.7 (0.8-16.6)	3.8 (0.8-18.6)
24 mos	reference	1.7 (0.6-5.2)	5.6 ^s (2.0-15.5)	1.0 (0.3-3.0)

^a %, percent; ^s, significant; n.s., not significant; CI, confidence interval.

showed an instant, reversible decrease of blood flow for 3 to 6 min, but with no signs of hyperemic reaction that might be caused by heat (Keller and Hibst, 1991). Calcium hydroxide has been reported to create a superficial coagulation necrosis, possibly inhibiting bleeding and fluid loss (Ranly and García-Godoy, 2000; Waterhouse *et al.*, 2000). Ferric sulfate precipitates protein plugs, resulting from the reaction of blood with both the ferric and sulfate ions that occlude the capillary orifices, causing hemostasis (Lemon *et al.*, 1993). Nevertheless, it might be assumed, from this and other studies, that the pulpal status is more crucial to a successful pulpotomy procedure

Table 3. Analysis^a of the Clinical Failures (CF) after 6, 12, 18, and 24 Mos (mos) and the Clinically Symptom-free Radiographic Failures (RF) after 12 and 24 Mos

	Formocresol				Laser				Calcium Hydroxide				Ferric Sulfate			
	6	12	18	24	6	12	18	24	6	12	18	24	6	12	18	24
Percussion																
Fistula			1		1	2			1	1		3				
Swelling				1												
RF/mos	-	12	-	24	-	12	-	24	-	12	-	24	-	12	-	24
Periapical R ^b					1				1		1				2	
Furcal R		2		1				2		1		3			3	
External RR									1		2					
Internal RR				2	1		2		1		3				2	

^a Spontaneous pain, pathological tooth mobility, or widened periodontal ligament space was not found.

^b R, radiolucency; RR, root resorption.

when calcium hydroxide (Schröder, 1978; Waterhouse *et al.*, 2000) and the Er:YAG laser are used, than when formocresol or ferric sulfate is used.

The external validity of this study—revealing new data concerning the controlled use of the Er:YAG laser for pulpotomies—is limited, due to the fact that the pulpotomies were performed by specialists in a hospital, with patients identified mainly following referral, and with special options offered, such as general anesthesia (Nadin *et al.*, 2003).

After 24 mos, only calcium hydroxide was significantly less effective than formocresol. To answer the question whether the non-significant results comparing the Er:YAG laser or ferric sulfate with formocresol indicate that there is in fact no difference, an increased sample size and power would be required, *e.g.*, within a large-scale multi-center study.

ACKNOWLEDGMENTS

The authors acknowledge Željka Maruniza, Kathrin Braunmüller, and Kerstin Weidlich for their project assistance. The study was completely financed by Departmental funding.

REFERENCES

- ADA American Dental Association Council on Scientific Affairs (2001). Acceptance program guidelines: dental and enamel adhesive materials. Chicago: American Dental Association.
- Altman DG (1991). Practical statistics for medical research. London: Chapman & Hall.
- Avram DC, Pulver F (1989). Pulpotomy medicaments for vital primary teeth. Surveys to determine use and attitudes in pediatric dental practice and in dental schools throughout the world. *J Dent Child* 56:426-434.
- Benz C, Reeka A, Stroinj A, Hickel R (1998). Comparison of two pulpotomy techniques in deciduous dentition: a clinical study. *Ital J Paediatr Dent* 1:38-39.
- Casas MJ, Layug MA, Kenny DJ, Johnston DH, Judd PL (2003). Two-year outcomes of primary molar ferric sulphate pulpotomy and root canal therapy. *Pediatr Dent* 25:97-102.
- Dupont WD, Plummer WD (1990). Power and sample size calculations. A review and computer program. *Control Clin Trials* 11:116-128.
- Fei AL, Udin R, Johnson R (1991). A clinical study of ferric sulphate as a pulpotomy agent in primary teeth. *Pediatr Dent* 13:327-332.
- Fuks AB (2002). Current concepts in vital primary pulp therapy. *Eur J Paediatr Dent* 3:115-120.
- Fuks AB, Holan G, Davis JM, Eidelman E (1997). Ferric sulphate versus dilute formocresol in pulpotomized primary molars: long-term follow up. *Pediatr Dent* 19:327-330.
- Gruythuysen RJ, Weerheijm KL (1997). Calcium hydroxide pulpotomy with a light-cured cavity-sealing material after two years. *J Dent Child* 64:251-253.
- Ibricevic H, Al-Jame Q (2000). Ferric sulfate as pulpotomy agent in primary teeth: twenty month clinical follow-up. *Clin Pediatr Dent* 24:269-272.
- Jayawardena JA, Kato J, Moriya K, Takagi Y (2001). Pulpal response to exposure with Er:YAG laser. *Oral Surg Oral Med Oral Pathol Radiol Endod* 91:222-229.
- Keller U, Hibst R (1991). Tooth pulp reaction following Er:YAG laser application. *Proc SPIE* 1424:127-133.
- Kimura Y, Yonaga K, Yokoyama K, Watanabe H, Wang X, Matsumoto K (2003). Histopathological changes in dental pulp irradiated by Er:YAG laser: a preliminary report on laser pulpotomy. *J Clin Laser Med Surg* 21:345-350.
- King SR, McWhorter AG, Seale NS (2002). Concentration of formocresol used by pediatric dentists in primary tooth pulpotomy. *Pediatr Dent* 24:157-159.
- Lemon RR, Steele PJ, Jeanson BG (1993). Ferric sulfate hemostasis: effect on osseous wound healing. Left in situ for maximum exposure. *J Endod* 19:170-173.
- Lewis B (1998). Formaldehyde in dentistry: a review for the millennium. *Pediatr Dent* 22:167-177.
- Liang KY, Zeger SL (1986). Longitudinal data analysis using generalized linear models. *Biometrika* 73:13-22.
- Matsumoto K (2000). Lasers in endodontics. *Dent Clin North Am* 44:889-906.
- Mielke CH Jr, Kaneshiro MM, Maher IA, Weiner JM, Rapaport SI (1969). The standardized normal Ivy bleeding time and its prolongation by aspirin. *Blood* 34:204-215.
- Moher D, Schulz KF, Altman DG (2001). The CONSORT statement: revised recommendations for improving the quality of reports of parallel-group randomized trials. *Ann Intern Med* 134:657-662.
- Nadin G, Goel BR, Yeung CA, Glennly AM (2003). Pulp treatment for extensive decay in primary teeth. *Cochrane Database Syst Rev* 1:CD003220.
- Ranly DM, García-Godoy F (2000). Current and potential pulp therapies for primary and young permanent teeth. *J Dent* 28:153-161.
- Schoop U, Moritz A, Kluger W, Patruta S, Goharkhay K, Sperr W, *et al.* (2002). The Er:YAG laser in endodontics: results of an in vitro study. *Lasers Surg Med* 30:360-364.
- Schröder U (1978). A 2-year follow-up of primary molars, pulpotomized with a gentle technique and capped with calcium hydroxide. *Scand J Dent Res* 86:273-278.
- Thompson KS, Seale NS, Nunn ME, Huff G (2001). Alternative method of hemorrhage control in full strength formocresol pulpotomy. *Pediatr Dent* 23:217-222.
- Waterhouse PJ, Nunn JH, Whitworth JM (2000). An investigation of the relative efficacy of Buckley's Formocresol and calcium hydroxide in primary molar vital pulp therapy. *Br Dent J* 188:32-36.