

Weekly Irinotecan in a Patient with Metastatic Colorectal Cancer on Hemodialysis due to Chronic Renal Failure

J. Stemmler^a A. Weise^b U. Hacker^a V. Heinemann^a A. Schalhorn^a

^aDept. of Internal Medicine III, University Hospital of Munich

^bDept. of Internal Medicine – Nephrology, Harlaching, Munich

Key Words

CPT-11 · Colorectal cancer, metastatic · Hemodialysis

Summary

Background: The cytotoxic treatment of patients suffering from advanced or metastatic cancer undergoing hemodialysis due to chronic renal failure still remains a problem, since for those patients pharmacokinetic and pharmacodynamic data on most cytotoxic agents are lacking. **Case Report:** We report a 45-year-old male who suffered from chronic renal failure and was diagnosed with stage-3 colorectal cancer (CRC) in February 2000. After surgical removal of the tumor an adjuvant chemotherapy of dose-reduced i.v. bolus 5-fluorouracil and folinic acid was begun (Mayo protocol). Due to excessive gastrointestinal toxicity, therapy was discontinued after the first cycle. In April 2000 liver metastases were diagnosed. The patient was then put on a weekly schedule of dose-reduced CPT-11 (50 mg/m², 80 mg total). No hematological or non-hematological toxicity grade 3/4 was observed. Due to excellent tolerability and lack of severe side effects the dose was increased up to 80 mg/m² (140 mg total) weekly. A dose escalation to 100 mg/m² (180 mg total) resulted in severe diarrhea (grade 4). Within 2 months of treatment the patient achieved a lasting partial remission until April 2001 (12 months). A significant progression of hepatic metastases required an alternative treatment regimen beginning in July 2001 (HAI, hepatic artery infusion). **Conclusion:** This case report demonstrates the feasibility and efficacy of a weekly treatment with dose-reduced CPT-11 in a patient with metastatic CRC on hemodialysis due to chronic renal failure.

Schlüsselwörter

CPT-11 · Kolonkarzinom, metastasiertes · Hämodialyse

Zusammenfassung

Hintergrund: Die chemotherapeutische Behandlung von chronisch dialysepflichtigen Patienten mit fortgeschrittenen oder metastasierten Tumoren ist häufig problematisch, da für dieses spezielle Patientenkollektiv pharmakokinetische und pharmakodynamische Daten nur unzureichend verfügbar sind. **Kasuistik:** Wir berichten im Folgenden über einen 45-jährigen dialysepflichtigen Patienten bei dem im Februar 2000 ein Kolonkarzinom im Stadium 3 diagnostiziert wurde. Im Anschluss an die operative Resektion wurde aufgrund der Dialysepflichtigkeit eine dosisreduzierte, adjuvante Chemotherapie nach dem sogenannten Mayo-Protokoll durchgeführt (i.v. Bolus 5-Fluorouracil und Folinsäure). Aufgrund einer exzessiven gastrointestinalen Toxizität musste diese Therapie jedoch vorzeitig abgebrochen werden. Im April 2000 wurden dann Lebermetastasen diagnostiziert. Wir begannen eine wöchentliche, dosisreduzierte Therapie mit CPT-11 (50 mg/m², 80 mg Gesamtdosis). Diese Therapie wurde ohne wesentliche hämatologische oder nicht-hämatologische Toxizität (keine Toxizität Grad 3/4) toleriert. Die Dosis wurde daraufhin auf 80 mg/m² wöchentlich (140 mg Gesamtdosis) gesteigert. Eine Dosisescalation auf 100 mg/m² (180 mg Gesamtdosis) konnte wegen des Auftretens einer schweren Diarrhö (Grad 4) nicht durchgeführt werden. Nach 2-monatiger Therapiedauer erreichte der Patient eine bis April 2001 anhaltende partielle Remission (12 Monate). Seit Juli 2001 wird wegen einer signifikanten Progression eine alternative Therapie durchgeführt (HAI = intraarterielle, lokoregionäre Chemotherapie). **Schlussfolgerung:** Diese Kasuistik zeigt die Durchführbarkeit und Effektivität einer wöchentlichen, dosisreduzierten Therapie mit CPT-11 bei einem dialysepflichtigen Patienten mit metastasiertem Kolonkarzinom.

Introduction

Colorectal cancer (CRC) is one of the most prevalent malignancies and second leading cause of cancer death in many industrialized countries [1–5].

Irinotecan (CPT-11) as a topoisomerase I inhibitor displays a broad range of clinical activity against several tumors. The drug lacks cross-resistance with 5-fluorouracil (5-FU) and is commonly used for first- or second-line treatment of metastatic CRC. As single agent therapy, CPT-11 can be administered on weekly schedules (100–150 mg/m², weekly × 4, q6w) as well as on a 3-week schedule (250–350 mg/m², q3w).

In the second-line treatment of metastatic CRC, CPT-11 induces a response rate of 10–19% and increases significantly the 1-year survival when compared to best supportive care (36.2 vs. 13.8%) [1]. The main toxicity of single-agent CPT-11 therapy consists of diarrhea, cholinergic syndrome, alopecia, nausea and vomiting, and neutropenia.

As indicated in a pharmacokinetic study, nearly 80% of the overall clearance of CPT-11 can be attributed to nonrenal processes, including metabolic degradation of CPT-11. Part of this nonrenal elimination was accounted for by fecal excretion of unchanged CPT-11 and its four major metabolites.

In knowledge of these data, CPT-11 may be used in patients suffering from chronic renal failure.

Case Report

We report a 45-year-old male who was started on hemodialysis in September 1994 due to chronic renal failure caused by rapid progressive glomerulonephritis. In addition, he suffered from a congenital immunoglobulin deficiency syndrome with low levels of IgA and IgM, leading to frequent infections of the respiratory tract.

In February 2000 the patient was diagnosed with stage-3 CRC which was surgically removed by left-sided hemicolectomy (pT3, pN2(9/15), M0, G2, R0). Due to positive lymph node involvement, the patient was started on an adjuvant chemotherapy schedule in March 2000, consisting of folinic acid (FA) and dose-reduced 5-FU due to chronic renal failure (i.v. bolus regimen 'Mayo protocol').

The first cycle consisted of FA (20 mg/m²) followed by 5-FU (200 mg/m²) given as i.v. bolus on days 1–4. Even 2 days after finishing the first cycle, the patient showed markedly gastrointestinal toxicity with excessive diarrhea and abdominal pain for a period of 10 days.

After reconstitution, the patient was diagnosed with elevated CEA levels (6.6 ng/ml) in April 2000, leading to recurrence of CRC. A CT scan was performed, detecting multiple hepatic metastases with a maximum extension of 2 cm.

At the end of April 2000 the patient then was started on a weekly schedule of dose-reduced CPT-11 (50 mg/m², 80 mg total). No hematological and non-hematological toxicity grade 3/4 was observed and the patient achieved a partial remission in the course of treatment, diagnosed by CT scan and decreasing CEA levels (3.3 ng/ml). Due to excellent tolerability with only mild diarrhea and lacking of severe side effects, the dose was escalated up to 80 mg/m² (140 mg total dose) weekly. Side effects like severe diarrhea (grade 4) occurred if the dose was escalated up to 100 mg/m² (180 mg total dose), therefore treatment was continued with a weekly dose of 80 mg/m².

Although CEA levels had begun to increase since October 2000, imaging procedures (CT scan) showed a stable disease without significant changes in size of the hepatic metastases in January 2001.

In April 2001, 12 months after starting CPT-11 treatment, a significant progression of liver metastases was diagnosed by CT scan and required an alternative treatment regimen (HAI, hepatic artery infusion) beginning in July 2001 (fig. 1).

During the whole treatment period no significantly changes concerning frequency of hemodialysis or laboratory tests of renal parameters were observed.

Discussion

With an incidence of around 875,000 newly diagnosed cases per year worldwide, CRC is one of the most frequent cancer entities. Due to its frequency, it is not surprising when patients suffering from chronic renal insufficiency are diagnosed with CRC [3, 4].

The treatment of patients suffering from cancer undergoing hemodialysis due to chronic renal failure still remains a problem, since for most cytotoxic agents pharmacokinetic and pharmacodynamic data are lacking.

Irinotecan [CPT-11, 7-ethyl-10-[4-(1-piperidino)-1-piperidino]-carbonyloxycamptothecin] as a topoisomerase I inhibitor has demonstrated clinical activity against 5-fluorouracil-refractory CRC. As single-agent therapy, CPT-11 can be administered on a weekly schedule with doses between 100 and 150 mg/m² (weekly), or on a 3-week schedule with doses between 250 and 350 mg/m² (q3w) [4, 5].

In the second-line treatment of CRC, CPT-11 significantly increases the 1-year survival compared to best supportive care (36.2 vs. 13.8%) [1]. Also, when comparing CPT-11 treatment to different 5-FU-based schedules, CPT-11 resulted in a significant increased 1-year survival rate (44.8 vs. 32.4%, *p* = 0.0035) [2]. The response rates in the second-line treatment ranged from 10 to 19%. A combination regimen of a protracted 5-FU infusion with CPT-11 achieved a remission rate of 49% in the first-line therapy of CRC and the combination resulted in a significantly increased survival rate [6, 7].

The main toxicity of single-agent CPT-11 therapy comprises diarrhea, neutropenia, alopecia, cholinergic syndrome, and nausea and vomiting [4, 5].

In a trial of Pitot et al. [8] of CPT-11 given on a weekly schedule (*n* = 121; 90 patients pretreated with 5-FU, CPT-11 125 mg/m² weekly × 4, q6w), diarrhea grade 3/4 occurred in 36.4%, and neutropenia grade 3/4 was observed in 21.5% of the patients (febrile neutropenia in 3.3%). The response rate in the first-line treatment amounted to 25.8% (95% CI: 11.9–44.6%), and to 13.3% (95% CI: 7.1–22.1%) in the second-line treatment. In a trial of Rougier et al. [9] including 213 patients treated on a 3-week schedule (350 mg/m² q3w), grade-3/4 neutropenia was observed in 47%, and diarrhea grade 3/4 occurred in 39% of the patients. An overall response rate of 18.8% (95% CI: 8.9–32.6%) was observed in the first-line situation

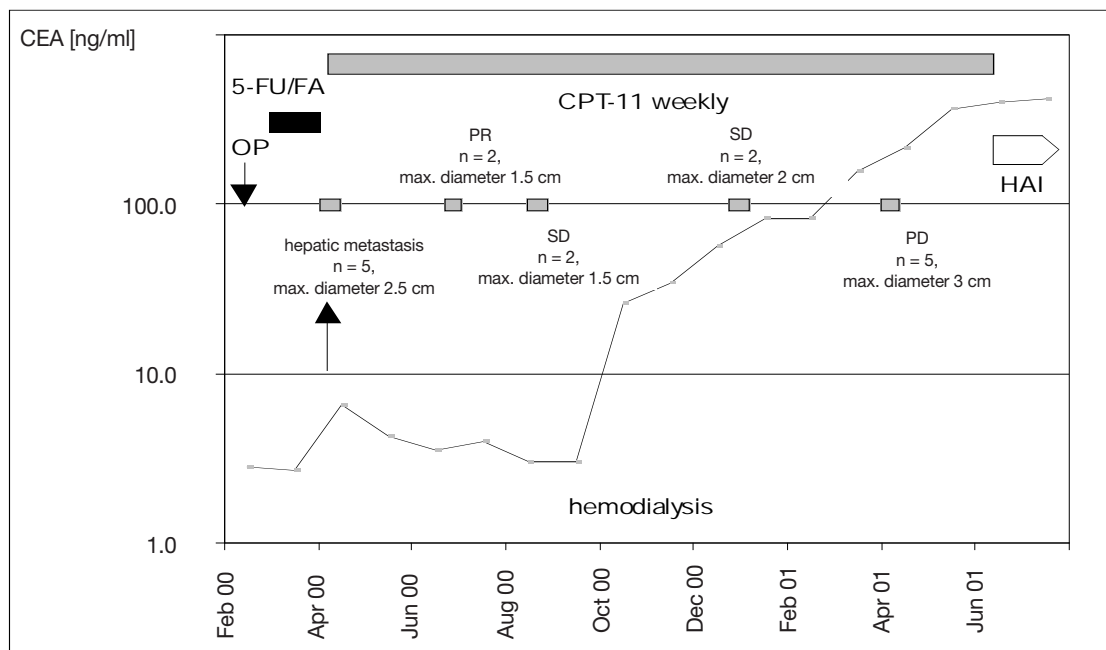


Fig. 1. Course of treatment including CEA levels and CT findings. 5-FU = 5-fluorouracil; FA = folinic acid; HAI = hepatic artery infusion; OP = surgical tumor resection.

and amounted to 17.7% (95% CI: 11.5–25.3%) in the second-line treatment.

When given CPT-11 (80 mg/m² weekly) in combination with a weekly 5-FU infusion schedule (up to 2.6 g/m²/24 h), neutropenia did not exceed grade-2 toxicity, and diarrhea grade 3/4 only occurred when CPT-11 was escalated to a weekly dose of 100 mg/m². The response rate in this study amounted to 64% (95% CI: 45–83%) [10].

In our patient the observation of grade-4 diarrhea over a period of more than a week after the first dose-reduced 5-FU/FA cycle led to disruption of a 5-FU-based regimen. Although 5-FU undergoes hepatic metabolism, it still remains unclear whether the observed excessive gastrointestinal toxicity was influenced by the chronic renal failure or whether it was a dihydropyrimidine dehydrogenase (DPD) deficiency.

The above-mentioned toxicity data of CPT-11 indicate that single-agent CPT-11 at a weekly dose of 50 mg/m², as administered for the initial dose level in our patient, may result in a treatment with low toxicity. In the course of treatment we have not observed any toxicity which had exceeded grade 2, although the dose was increased to 80 mg/m² per week.

The reason for the low toxicity of the treatment may be caused by metabolism of CPT-11. The drug was generated into the active metabolite SN-38 (7-ethyl-1-hydroxycamptothecin) by a carboxylesterase of the serum, liver, and the small intestine [11]. Preliminary data suggested also an activation by carboxylesterase activity within the tumor [12]. As in-

dicated by a pharmacokinetic study of Sparreboom et al. [11], nearly 80% of the overall clearance of CPT-11 can be attributed to nonrenal processes, including metabolic degradation of CPT-11 by UDP glucuronosyltransferase 1A1 to an inactive beta-glucuronide derivative (SN-38G). Part of this nonrenal elimination was accounted for by fecal excretion of unchanged CPT-11 and its four major metabolites. The finding that CPT-11 undergoes significant hepatic metabolism, and the preliminary pharmacokinetic and toxicity results of a study of CPT-11 administration in adults with liver dysfunction, suggested that the dose should be reduced by one third in patients with total bilirubin more than 3× the upper limit of the normal level [13].

Minor experiences are published for CPT-11 (and the camptothecin analogue topotecan) in patients with renal dysfunction. For topotecan, one observed severe neutropenia in patients with moderate to severe renal dysfunction treated at one third of the adult maximal tolerated dosage (0.5 mg/m²/day) [14].

Although renal excretion is a minor route of elimination for CPT-11 and SN-38, no experiences concerning the administration of this cytotoxic agent in patients undergoing hemodialysis are published so far. The lack of any severe toxicity in our patient over a treatment period of 14 months leads to the conclusion that dose-reduced weekly CPT-11 may be feasible and effective in patients undergoing hemodialysis due to chronic renal failure.

References

- 1 Cunningham D, Pyrhönen S, James RD, Punt CJA, Hickish TF, Heikkilä R, Johannessen TB, Starkhammar H, Topham CA, Awad L, Jacques C, Herait P: Randomised trial of irinotecan plus supportive care versus supportive care alone after fluorouracil failure for patients with metastatic colorectal cancer. *Lancet* 1998;352:1413–1418.
- 2 Rougier P, VanCutsem E, Bajetta E, Niederle N, Possinger K, Labianca R, Navarro M, Morant R, Bleiberg H, Wils J, Awad L, Herait P, Jacques C: Randomised trial of irinotecan versus fluorouracil by continuous infusion after fluorouracil failure in patients with metastatic colorectal cancer. *Lancet* 1998;352:1407–1412.
- 3 Köhne CH, Harstrick A (Hrsg): Aktuelle Therapie des kolorektalen Karzinoms. Bremen, Uni-Med, 2001.
- 4 Schmoll HJ, Höffken K, Possinger K (Hrsg): Kompendium Internistische Onkologie; 3. Aufl. Heidelberg, Springer, 1999.
- 5 Seeber S, Schütte J (Hrsg): Therapiekonzepte Onkologie; 3. Aufl. Heidelberg, Springer, 1998.
- 6 Douillard JY, Cunningham D, Roth AD, Navarro M, James RD, Karasek P, Jandik P, Iveson T, Carmichael J, Alakl M, Gruia G, Awad L, Rougier P: Irinotecan combined with fluorouracil compared with fluorouracil alone as first-line treatment for metastatic colorectal cancer: A multicentre randomised trial. *Lancet* 2000;355:1041–1047.
- 7 Saltz LB, Cox JV, Blanke CH, Rosen LS, Fehrenbacher L, Moore MJ, Maroun JA, Ackland SP, Locker PK, Pirotta N, Elfring GL, Miller LL: Irinotecan plus fluorouracil and leucovorin for metastatic colorectal cancer. *N Engl J Med* 2000; 343:905–914.
- 8 Pitot HC, Wender DB, O'Connell MJ, Schroeder G, Rubin J, Mailliard JA, Knost JA, Ghosh C, Kirschling RJ, Levitt R, Windschitl HE: Phase II trial of irinotecan in patients with colorectal carcinoma. *J Clin Oncol* 1997;15:2910–2919.
- 9 Rougier P, Bugat R, Douillard JY, Culine S, Suc E, Brunet P, Becouarn Y, Ychou M, Marty M, Extra JM, Bonnetterre J, Adenis A, Seitz JF, Ganem G, Namer M, Conroy T, Negrier S, Merrouche Y, Burki F, Mousseau M, Herait P, Mahjoubi M.: A phase II study of irinotecan in the treatment of advanced colorectal cancer in chemotherapy-naïve patients and patients pretreated with fluorouracil-based chemotherapy. *J Clin Oncol* 1997;15:251–260.
- 10 Vanhoefer U, Harstrick A, Köhne CH, Achterrath W, Rustum YM, Seeber S, Wilke H: Phase I study of a weekly schedule of irinotecan, high-dose leucovorin, and infusional fluorouracil as first-line chemotherapy in patients with advanced colorectal cancer. *J Clin Oncol* 1999;17:907–913.
- 11 Sparreboom A, deJonge MJ, deBruijn P, Brouwer E, Nooter K, Loos WJ, van Alphen RJ, Mathijssen RH, Stoter G, Verweij J: Irinotecan (CPT-11) metabolism and disposition in cancer patients. *Clin Cancer Res* 1998;4:2747–2754.
- 12 Rivory LP, Bowles MR, Robert J, Pond SM: Conversion of irinotecan (CPT-11) to its active metabolite, 7-ethyl-10-hydroxycamptothecin (SN-38), by human liver carboxylesterase. *Biochem Pharmacol* 1996;52:1103–1111.
- 13 Raymond E, Vernillet L, Boige V et al.: Phase I and pharmacokinetic study of irinotecan (CPT-11) in cancer patients with hepatic dysfunction. *Proc Am Soc Clin Oncol* 1999;18:165a(abstr).
- 14 O'Reilly S, Rowinsky EK, Slichenmeyer W, Donehower RC, Forastiere AA, Ettinger DS, Chen TL, Sartorius S, Grochow LB: Phase I and pharmacologic study of topotecan in patients with impaired renal function. *J Clin Oncol* 1996;14:3062–3073.