

P. Danos<sup>a</sup>  
 S. Kasper<sup>b</sup>  
 F. Grünwald<sup>c</sup>  
 E. Klemm<sup>c</sup>  
 C. Krappel<sup>d</sup>  
 K. Broich<sup>e</sup>  
 G. Höflich<sup>d</sup>  
 B. Overbeck<sup>c</sup>  
 H.J. Biersack<sup>c</sup>  
 H.J. Möller<sup>f</sup>

<sup>a</sup> Department of Psychiatry,  
 University of Magdeburg, Germany,  
<sup>b</sup> Department of General Psychiatry,  
 University of Vienna, Austria,  
<sup>c</sup> Clinic for Nuclear Medicine,  
 University of Bonn,  
 Departments of Psychiatry,  
<sup>d</sup> University of Bonn,  
<sup>e</sup> University of Halle, and  
<sup>f</sup> University of Munich, Germany

## Pathological Regional Cerebral Blood Flow in Opiate-Dependent Patients during Withdrawal: A HMPAO-SPECT Study

### Abstract

The aims of the present study were to investigate regional cerebral blood flow (rCBF) in heroin-dependent patients during withdrawal and to assess the relation between these changes and duration of heroin consumption and withdrawal data. The rCBF was measured using brain SPECT with <sup>99m</sup>Tc-HMPAO in 16 heroin-dependent patients during heroin withdrawal. Thirteen patients received levomethadone at the time of the SPECT scans. The images were analyzed both visually and quantitatively. A total of 21 hypoperfused brain regions were observed in 11 of the 16 patients. The temporal lobes were the most affected area, hypoperfusions of the right and left temporal lobe were observed in 5 and 5 patients, respectively. Three of the patients had a hypoperfusion of the right frontal lobe, 2 patients showed perfusion defects in the left frontal lobe, right parietal lobe and left parietal lobe. The results of the quantitative assessments of the rCBF were consistent with the results of the qualitative findings. The stepwise regression analysis showed a significant positive correlation ( $r = 0.54$ ) between the dose of levomethadone at the time of the SPECT scan and the rCBF of the right parietal lobe. Other significant correlations between clinical data and rCBF were not found. The present results suggest brain perfusion abnormalities during heroin withdrawal in heroin-dependent patients, which are not due to the conditions of withdrawal.

### Key Words

Opiates  
 HMPAO-SPECT  
 rCBF

### Introduction

The effect of acute and long-term heroin use and heroin withdrawal on regional cerebral blood flow (rCBF) is still not well understood [1]. Increase and decrease of CBF after acute application of synthetic opoids on CBF

have been reported in animal experiments and in human volunteers, depending on the dose application, state of the subject (conscious or anesthetized) or brain region. However, these experiments suggest that synthetic opoids have not a direct cerebrovascular action but that changes of CBF are more related to metabolic, neuronal or respi-

KARGER

Fax + 41 61 306 12 34  
 E-Mail karger@karger.ch  
 www.karger.com

© 1998 S. Karger AG, Basel  
 0302-282X/98/0374-0194\$15.00/0

This article is also accessible online at:  
<http://BioMedNet.com/karger>

Peter Danos, MD  
 Department of Psychiatry, University of Magdeburg  
 Leipziger Strasse 44  
 D-39120 Magdeburg (Germany)  
 Fax +49 391 67190018, E-Mail peter.danos@medizin.uni-magdeburg

ratory effects of heroin receptor stimulation changes in neuronal activity [2].

Therefore, as in other psychiatric diseases [3], investigations of rCBF in subjects with a heroin dependence can be useful in identifying areas of brain dysfunction in this disease.

There are just a few studies exploring the changes of the rCBF in acute and chronic heroin use [4–6]. However, these studies have focused more on the acute effects of opiates [4] or on the effects of opiate withdrawal on rCBF [5, 6].

One of the purposes of our study was to measure the CBF by HMPAO-SPECT in subjects with heroin dependence who presented for detoxification in our department. Another purpose of the present study was to figure out whether changes in CBF were more related to the long-term use of heroin or are more due to withdrawal from heroin.

## Methods

### Subjects

Sixteen patients, 9 women and 7 men (mean age = 25.4 years, SD = 4.3), who fulfilled DSM-III-R criteria [7] for active heroin dependence, were included in the study. Exclusion criteria were neurological signs or a history of neurological disease, head trauma, cardiovascular or endocrinological disease, current medical illness, seropositive status for the human immunodeficiency virus and DSM-III-R diagnosis of dependence on or abuse of any substance other than heroin, nicotine or caffeine. Urine toxicology testing was used on test days. These criteria were used to control potential confounding effects of other substances and withdrawal from other substances.

The mean duration of heroin use was 4.0 years (SD = 3.6), the average amount of daily street heroin was  $1,046 \pm 633$  mg/day. The SPECT scans ( $n = 16$ ) were performed during the 1st week (mean = 6.9, SD = 4.1) of detoxification. Thirteen (81.5%) patients received levomethadone (mean dose/day:  $24.1 \pm 21.1$  mg) at the time of the SPECT scan. The subjects received no other psychopharmacological drug at the time of the SPECT scan. Fourteen (87.5%) patients were right-handed, 2 patients were left-handed. Thirteen (81.2%) patients had a CT scan. No pathological findings (e.g. tumors, infarctions, hematomas) were found in the CT scans. The degree of opiate withdrawal was assessed daily with the Opiate Withdrawal Scale (OWS) [8], a self-rating scale.

### Ethics

The study was approved by the Ethical Committee of the University of Bonn. All the patients gave their written informed consent to participate in this study.

### SPECT Technique

After giving informed consent, the patient underwent SPECT following intravenous injection of 20 mCi  $^{99m}\text{Tc}$ -HMPAO. Subjects were in a resting state, with their eyes open. The perfusion agent was

supplied by Amersham International, UK, and labeled according to the manufacturer's recommendation.

A rotating double-head gamma camera (DynaScan, Picker, Berea, Ohio; full-width half-maximum = 12–15 mm) equipped with a low-energy high-resolution parallel-hole collimator was used to obtain 64 frames with  $64 \times 64$  matrix within 30 min. After application of a Metz filter and attenuation correction, activity levels in coronal, sagittal, and transaxial slices parallel to the orbitomeatal line were calculated. To achieve a proper image of the temporal lobe, transversal slices parallel to the temporal lobe plane were reconstructed [9].

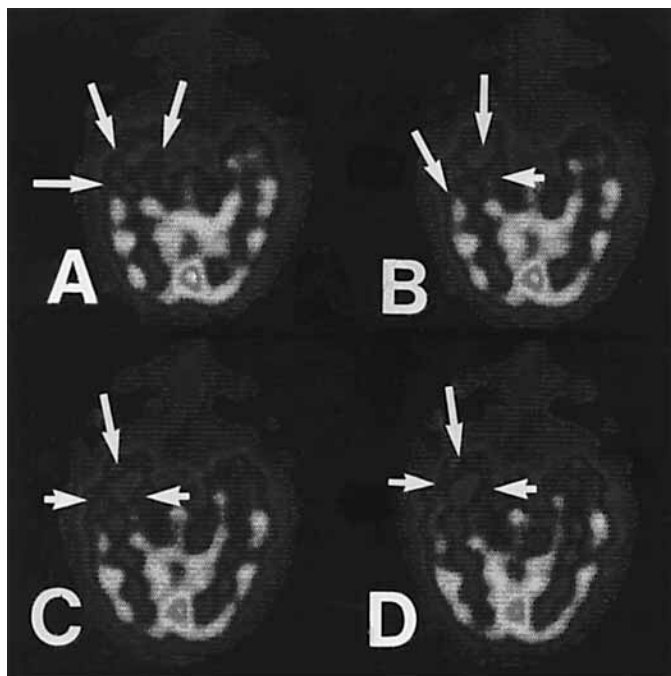
For the quantitative analysis, regions of interest (ROIs) of the same size and shape (84 pixels, 1 pixel corresponding to  $6 \times 6$  mm) were drawn on 30 cerebral areas including the basal ganglia and the cerebellum by an investigator who was unaware of the diagnosis, visual findings and psychopathology. The ROIs were defined as follows: First, three transversal slices parallel to the orbitomeatal line were selected, one within the basal ganglia plane, one 2.4 cm above the basal ganglia plane, and one towards the cerebellum. In addition, one transversal slice parallel to the temporal lobe plane was reconstructed to display a proper image of the temporal lobe, coronal slices were cut both through the basal ganglia and the temporal lobe, each perpendicular to the corresponding transversal plane. Sagittal slices were placed 1.2 cm lateral to the median slice on both sides. Anatomical regions were assigned according to the anatomic atlas of Matsui and Hirano [10].

The regional activity was calculated as follows: Frontal and occipital lobe: mean of the corresponding ROI within the transversal slice across the basal ganglia and the sagittal slice; parietal lobe: mean of the corresponding ROI within the transversal slice 2.4 cm above the basal ganglia plane and the sagittal slice; temporal lobe: mean of the corresponding ROI in the transversal temporal lobe plane and the perpendicular coronal slice across the temporal lobe; basal ganglia: mean of the corresponding ROI of the transversal slice and the perpendicular coronal slice, both across the basal ganglia; cerebellum: mean of two ROI on each side of the cerebellum (transversal plane across the cerebellum). All values were calculated for both sides and normalized both to the whole slice across the basal ganglia and to the cerebellum.

The SPECT scans were analyzed qualitatively by 3 experienced nuclear medicine specialists. Diminished perfusion (hypoperfusion) was defined by markedly reduced tracer uptake in one or more brain regions relative to the remaining regions as determined by 3 experienced nuclear medicine specialists. Intrarater reliability was more than 95%, and interrater reliability more than 94%.

### Statistical Analysis

Mann-Whitney U tests were performed for the analyses of the differences of clinical data as age, length of heroin dependence, dose of daily consumed heroin, day of the SPECT study within the withdrawal period, dose of levomethadone at the time of the SPECT study, score on the OWS at the time of the SPECT study in the subjects with and without pathological qualitative findings. Multiple linear regression analysis was applied for the quantitative analyses to evaluate the relationship between rCBF and clinical data. The criterion for statistical significance was set at  $p < 0.05$  to have adequate power to detect differences with the small number of subjects. All data analyses were performed on a microcomputer using the SPSS/PC+ 4.0.1 (SPSS Inc., Chicago, Ill.) statistical software.



**Fig. 1. A-D** Transaxial (rotated parallel to the longitudinal axis of the temporal lobe) images of rCBF from a 23-year-old heroin-dependent woman with a 1-year history of heroin dependence who was free of opioids for 6 days at the time of the scanning. Dark areas represent areas with low rCBF and light areas represent areas with high rCBF. The left side of the images corresponds to the right hemisphere. Note the decrease of the rCBF in the medial and lateral part of the right temporal lobe visible in 4 consecutive sections (arrows). The localization of the 4 slices is represented in the schematic illustration below.

**Table 1.** Frequency of brain regions with hypoperfusion in 16 opioid-dependent patients during first week of withdrawal

Region	Right	Left
Frontal	3	2
Temporal	5	5
Parietal	2	2
Occipital	1	0
Basal ganglia	1	0
Total regions with hypoperfusion	12	9
Total patients <sup>1</sup>	7	7

<sup>1</sup> Three patients showed hypoperfusions in the right and left hemisphere, therefore the number of patients with at least one pathological CBF was 11.

## Results

Eleven (68.7%) of the 16 heroin-dependent patients showed at least one region with a pathological CBF pattern. A total of 21 hypoperfused brain regions was observed in 11 of the 16 patients. The major findings were hypoperfusions of the right ( $n = 5$ ) and left ( $n = 5$ ) temporal lobe (fig. 1). Right frontal hypoperfusion was found in 3 patients, 2 patients showed hypoperfusions of the left frontal lobe. Hypoperfusions of the right and left parietal lobe were found in 2 patients each. The distribution of all areas with a decreased CBF is shown in table 1.

To compare the results of visual interpretation with those of quantitative analysis, two groups with pathological versus normal rCBF patterns were formed for the brain areas in which hypoperfusion was most commonly found (left and right temporal lobe).

Statistical analysis with the Mann-Whitney U test revealed significant differences between the rCBF in patients with visually determined hypoperfusion and those with visually determined normal blood flow for the analyzed regions. The mean  $\pm$  SD values for the hypoperfused areas were: left temporal  $1.05 \pm 0.07$ , right temporal  $1.12 \pm 0.06$ . The corresponding values for normal flow were: left temporal  $1.16 \pm 0.07$ , right temporal  $1.21 \pm 0.09$ .

Stepwise regression analysis was then performed to analyze possible relationships between rCBF and age, length of heroin dependence, dose of daily consumed heroin, day of the SPECT study within the withdrawal

period, dose of levomethadone at the time of the SPECT study, score on the OWS at the time of the SPECT study.

The stepwise regression analysis showed a significant positive correlation ( $r = 0.54$ ) between the dose of levomethadone on the day of the SPECT study and rCBF of the right parietal lobe (analysis of variance:  $F = 6.02$ ,  $d.f. = 1$ ,  $p = 0.02$ ). All other correlations did not reach a significance level. Especially, there was no significant correlation between the self-ratings measured with the OWS and the rCBF.

## Discussion

In this study, we used HMPAO-SPECT to measure rCBF in patients with heroin dependence during the first days of withdrawal.

The findings from this study can be summarized as follows: (1) the majority ( $n = 11$ , 68.7%) of the 16 heroin-dependent patients showed a pathological CBF during withdrawal. A total of 21 hypoperfused brain regions were observed; (2) the most affected brain areas were the right ( $n = 5$ ) and left ( $n = 5$ ) temporal lobes and the right ( $n = 3$ ) and left ( $n = 2$ ) parietal lobes, and (3) the quantitative assessments of hypoperfusion of the right parietal lobe correlated with the dose of levomethadone on the day of the SPECT study; other significant correlations were not found between rCBF heroin abuse history or withdrawal data.

The results of the present study should be interpreted in the context of some potentially important methodological limitations. One bias of our study is the absence of a control group. However, (1) we used an intraindividual paradigm for our assessments by comparing all defined regions of one hemisphere with the same regions of the other hemisphere, and (2) the qualitative assessments were supported by the quantitative data.

Another possible limitation is the use of qualitative data. Despite the great value of quantification in modern nuclear medicine techniques, visual interpretation of images is known to be a valuable tool. The relative decrease of mean values in the temporal lobes was 9.5% (left temporal lobe), and 7.4% (right temporal lobe). These values agree well with the approximate 10% limit defining hypoperfusion which is commonly practiced in many SPECT laboratories and is also used by us. The limit defining hypoperfusion in qualitative assessments is approximately 10%. Furthermore, in a study by Heiss et al. [11], it was concluded that the results assessed with the SPECT technique can be compared with the results of

PET studies. A recent study has shown that volumetric analysis of regional hypoperfusion on SPECT/HMPAO-SPECT is highly accurate and reproducible [12].

Another possible limitation of our results is that the decrease of metabolism in the temporal lobes may reflect the level of anxiety of the patients at the time of the scans. The results of SPECT studies and PET studies reporting relationships between anxiety and CBF are inconclusive. In the study by O'Carroll et al. [13], reductions of the rCBF were reported in right temporal lobe and occipital regions in patients suffering from phobia after anxiety induction. However, in the study by Mountz et al. [14], no relationship was found between anxiety and cerebral blood flow. Mathew and Wilson [15] concluded in their review article on anxiety and CBF that the effect of acute anxiety on CBF is highly complex and associated with a number of factors such as arousal, sympathetic tone,  $CO_2$ , etc.

Another limitation of the study is that the majority ( $n = 13$ ) of the subjects received levomethadone at the time of the SPECT study. However, Levin et al. [16] found that abnormal rCBF after detoxification was improved in their HMPAO-SPECT study on heroin-dependent poly-drug abusers in a dose-related manner by treatment with buprenorphine. Furthermore, in our study we found a hypoperfusion of the parietal lobe in the opiate addicts and also a positive significant correlation between the rCBF in the right parietal lobe and the dose of levomethadone. This means that treatment with levomethadone rather improved the pathological rCBF in the parietal lobe. Therefore, it does not appear plausible that observed pathological rCBF findings were due to the levomethadone treatment.

What pathophysiological mechanisms are responsible for the observed decreases in the rCBF of different brain regions in heroin-dependent patients? There are several possible explanations. One possibility is that the observed pathological findings are due to the heroin withdrawal state. This would mean that the pathological findings are reversible after the termination of the withdrawal. In our study, we found a significant negative correlation between quantitative rCBF of the right parietal lobe and dose of levomethadone at the time of the SPECT scan. Similar results were obtained in a study of Rose et al. [6]. In their first scan 1 week after discontinuation of the medication with clonidine, 9 of the 10 subjects demonstrated significant perfusion defects in the frontal parietal and temporal cortices, however, in the repeat scan 2 weeks later all 9 subjects with former pathological findings showed an improvement of the abnormal scans.

Our results are also consistent with findings of an abnormal cerebral metabolism in heroin-dependent patients measured by  $^{31}\text{P}$  MR spectroscopy [17]. However, in this study, the subjects also met DSM-III-R criteria for a concurrent cocaine dependence. Therefore it is not clear whether the described pathological results are not due to the cocaine dependence.

In the study by Krystal et al. [5], naloxone was administered in 10 methadone-maintained patients and the changes of the rCBF were measured by HMPAO-SPECT. Opiate-dependent patients, but not healthy subjects, developed opiate withdrawal signs. In this study, a significant reduction in ratios activities in the frontal and parietal cortices were observed in the patients who developed withdrawal signs. However, the methadone-maintained patients showed also a pathological blood flow even if they did not receive naloxone. In addition, in the study of Rose et al. [6], abnormal scans were obtained after 1 week of drug discontinuation when all symptoms of withdrawal had subsided.

Therefore, another mechanism that could account for the pathological SPECT scans in our study includes a direct effect of heroin on rCBF. The acute effects of opiates on human cerebral metabolism have been described in a study by London et al. [4]. In their study, 30 mg of morphine given intramuscularly produced reduced glucose utilization by 10% in the whole brain and by about 5–15% in the telencephalic areas of the cerebellar cortex. A reduction of the cerebral glucose metabolism was also observed after administration of 1 mg buprenorphine in polydrug abusers [18]. An opioid-induced decrease of the CBF has been described in previous studies in animals and humans [2, 19].

However, in these studies the distribution and degree of decreases of rCBF were not correlated with the distribution of opioid receptors in human brain [20], suggesting a rather complex association between opioids and CBF or glucose utilization respectively.

However, little information is available on the long-term effects of opiates on CBF and cerebral metabolism [1]. Brust and Richter [21] reported on strokes associated with addiction to heroin. However, in these reported cases, different etiologic factors, including loss of consciousness following after an overdose of heroin, intracerebral hemorrhage, cerebral embolization or vessel arteritis were implicated.

A third explanation is that the observed hypoperfusions in the temporal and parietal lobes were due to structural brain changes. This includes also secondary effects of drug abuse as long-term nutritional deficiencies, trau-

matic injuries of the head, infections of the central nervous system, repeated anoxic states or cerebral metabolism disturbances due to liver diseases. There are reports which revealed structural brain changes in heroin addicts [22, 23]. Experimental studies have shown that endogenous opioids [24] and morphine [25] interact with mechanisms which control neural growth, findings which may be relevant to the long-term effects of chronic use of opioids in humans. However, other CT and MRI studies did not replicate pathological morphological findings in opioid dependents [26, 27].

However, in the present study, the lack of pathological findings on CT examinations does not support this hypothesis. Furthermore, we did not find any significant correlation between the duration of heroin use, dose of daily consumed heroin and the qualitative or quantitative SPECT findings. In addition, the pathological findings in the study of Rose et al. [6] were reversible in the repeat scan 2 weeks later.

The localization of the decreases in the temporal lobes in our study are consistent with the findings of other studies which investigated the effects of opioids on glucose utilization, or CBF. London et al. [4] found significant decreases of regional cerebral metabolic rates for glucose in the temporal cortical regions after the administration of morphine. A decrease of rCBF in temporal areas was observed after administration of fentanyl [17].

In the studies of Krystal et al. [5] and Rose et al. [6], the pathological findings were located in the frontal and parietal lobes. In the study of Rose et al. [6] pathological findings were also found in the temporal lobe. In the present study the most affected brain region was the temporal lobe. These discrepancies between our study and the cited studies could be due to differences in the SPECT technique: The transaxial sections were cut parallel to the longitudinal axis of the temporal lobe [9]. Previous SPECT studies in psychiatric patients [13, 28] chose ROIs located only on sections parallel to the cantomeathal line. We think that with our method we can measure the rCBF in the temporal lobe more precisely than in previous studies.

The observed positive correlation between the dose of levomethadone on the day of the SPECT study and rCBF in the right parietal lobe is partly consistent with findings in the study of Krystal et al. [5]. In this HMPAO-SPECT study, administration of naloxone, an opioid antagonist, in healthy subjects was associated with decreased right parietal cortex activity ratios. Therefore, hypoperfusion in the right parietal region seems to be associated with withdrawal-dependent factors.

In conclusion, the present results are consistent with previous findings of pathological CBF in opiate withdrawal. The distribution of affected brain regions is not closely associated with the distribution of opioid receptors in human brain. These pathological findings appear also not to be mainly due to the withdrawal status.

As alterations of rCBF in other psychiatric diseases, the pathophysiological mechanisms that underlie rCBF disturbances in opiate dependence are complex and still little understood.

## References

- 1 Mathew RJ, Wilson WH: Substance abuse and cerebral blood flow. *Am J Psychiatry* 1991;148:292-305.
- 2 Benyó Z, Wahl M: Opiate receptor-mediated mechanisms in the regulation of cerebral blood flow. *Cerebrovasc Brain Metab Rev* 1996;8:326-357.
- 3 Klemm E, Danos P, Grünwald F, Kasper S, Möller HJ, Biersack HJ: Temporal lobe dysfunction and correlation of regional cerebral blood flow abnormalities with psychopathology in schizophrenia and major depression - A study with single photon emission computed tomography. *Psychiatry Res* 1996;68:1-10.
- 4 London ED, Broussolle EPM, Links JM, Wong DF, Cascella NG, Dannals RF, Sano M, Herning R, Snyder FR, Rippetoe LR, Toung TJK, Jaffe JH, Wagner Jr HN: Morphine-induced metabolic changes in human brain. Studies with positron emission tomography and [<sup>18</sup>F]fluorodeoxyglucose. *Arch Gen Psychiatry* 1990;47:73-81.
- 5 Krystal JH, Woods SW, Kosten TR, Rosen MI, Seibyl JP, van-Dyck CC, Price LH, Zubal IG, Hoffer PB, Charney DS: Opiate dependence and withdrawal: Preliminary assessment using single photon computerized tomography (SPECT). *Am J Drug Alcohol Abuse* 1995;21:47-63.
- 6 Rose JS, Branchey M, Buydens-Branchey L, Stapleton JM, Chasten K, Werrell A, Maayan ML: Cerebral perfusion in early and late opiate withdrawal: A technetium-99m-HMPAO SPECT study. *Psychiatry Res* 1996;67:39-47.
- 7 American Psychiatric Association: *Diagnostic and Statistical Manual of Mental Disorders*, ed 3, revised DSM-III-R. Washington, American Psychiatric Press, 1987.
- 8 Bradley BP, Gossop M, Phillips GT, Legarda JJ: The development of an Opiate Withdrawal Scale (OWS). *Br J Addict* 1987;82:1139-1142.
- 9 Grünwald F, Durwen HF, Bockisch A, Hotze A, Kersjes W, Elger CE, Biersack HJ: Technetium-99m-HMPAO brain SPECT in medically intractable temporal lobe epilepsy: A postoperative evaluation. *J Nucl Med* 1991;32:388-394.
- 10 Matsui T, Hirano A: *An Atlas of the Human Brain for Computerized Tomography*. Tokyo, Igaku-Shoin, 1978.
- 11 Heiss W-D, Herholz K, Podekra I, Neubauer I, Pietrzyk U: Comparison of (<sup>99m</sup>Tc)HMPAO SPECT with (<sup>18</sup>F)fluoromethane PET in cerebrovascular disease. *J Cereb Blood Flow Metab* 1990;10:687-697.
- 12 Infeld B, Binns D, Lichtenstein M, Hopper JL, Davis SM: Volumetric analysis of cerebral hypoperfusion on SPECT: Validation and reliability. *J Nucl Med* 1997;38:1447-1453.
- 13 O'Carroll RE, Moffoot APR, Van Beck M, Dougall N, Murray C, Ebmeier KP, Goodwin GM: The effect of anxiety on the regional uptake of <sup>99m</sup>Tc-exametazime in single phobia as shown by single photon emission tomography (SPET). *J Affect Disord* 1993;28:203-210.
- 14 Mountz JM, Modell JG, Wilson MW, Curtis GC, Lee MA, Schmaltz S, Kuhl DE: Positron emission tomographic evaluation of cerebral blood flow during state anxiety in simple phobia. *Arch Gen Psychiatry* 1989;46:501-504.
- 15 Mathew RJ, Wilson WH: Anxiety and cerebral blood flow. *Am J Psychiatry* 1990;147:838-849.
- 16 Levin JM, Mendelson JH, Holman BL, Teoh SK, Garada B, Schwartz RB, Mello NK: Improved regional cerebral blood flow in chronic cocaine polydrug users treated with buprenorphine. *J Nucl Med* 1995;36:1211-1215.
- 17 Christensen JD, Kaufman MJ, Levin JM, Mendelson JH, Holman BL, Cohen BM, Renshaw PF: Abnormal cerebral metabolism in polydrug abusers during early withdrawal: a <sup>31</sup>P MR spectroscopy study. *Magn Reson Med* 1996;35:658-663.
- 18 Walsh SL, Gilson SF, Jasinski DR, Stapleton JM, Phillips RL, Dannals RF, Schmidt J, Preston KL, Grayson R, Bigelow GE, Sullivan JT, Contoreggi C, London ED: Buprenorphine reduces cerebral glucose metabolism in polydrug abusers. *Neuropsychopharmacology* 1994;10:157-170.
- 19 Firestone LL, Gyulai F, Mintun M, Adler LJ, Urso K, Winter PM: Human brain activity response to fentanyl imaged by positron emission tomography. *Anesth Analg* 1996;82:1247-1251.
- 20 Pfeiffer A, Pasi A, Mehraein P, Herz A: Opiate receptor binding sites in human brain. *Brain Res* 1982;248:87-96.
- 21 Brust JCM, Richter RW: Stroke associated with addiction to heroin. *J Neurol Neurosurg Psychiatry* 1976;39:194-199.
- 22 Hill SY, Mikhael MA: Computerized transaxial tomographic and neuropsychological evaluations in chronic alcoholics and heroin abusers. *Am J Psychiatry* 1979;136:598-602.
- 23 Strang J, Gurling H: Computerized tomography and neuropsychological assessment in long-term high-dose heroin addicts. *Br J Addict* 1989;84:1011-1019.
- 24 Hauser KF, McLaughlin J, Zagon IS: Endogenous opioid systems and the regulation of dendritic growth and spine formation. *J Comp Neurol* 1989;281:13-22.
- 25 Stiene-Martin A, Gurwell JA, Hauser KF: Morphine alters astrocyte growth in primary cultures of mouse glial cells: Evidence for a direct effect of opiates on neural maturation. *Dev Brain Res* 1991;60:1-7.
- 26 Amass L, Nardin R, Mendelson JH, Teoh SK, Woods BT: Quantitative magnetic resonance imaging in heroin- and cocaine-dependent men: A preliminary study. *Psychiatry Res* 1992;45:15-23.
- 27 Cascella NG, Pearlson G, Wong DF, Broussolle E, Nagoshi C, Margolin RA, London ED: Effects of substance abuse on ventricular and sulcal measures assessed by computerized tomography. *Br J Psychiatry* 1991;159:217-221.
- 28 Ebert D, Feistel H, Barocka A: Effects of sleep deprivation on the limbic system and the frontal lobes in affective disorders: A study with Tc-99m-HMPAO SPECT. *Psychiatry Res* 1991;40:247-251.