

Prognostic Factors in Seminomas with Special Respect to HCG: Results of a Prospective Multicenter Study

L. Weissbach^a R. Bussar-Maatz^a U. Löhrs^b G.E. Schubert^c K. Mann^d
M. Hartmann^e K.P. Dieckmann^f J. Fassbinder^g
for the Seminoma Study Group¹

^aAbteilung für Urologie, Krankenhaus Am Urban, Berlin; ^bInstitut für Pathologie, Universität München;
^cInstitut für Pathologie, Klinikum Barmen, Wuppertal; ^dStudienlaboratorium, Abteilung für Endokrinologie,
Medizinische Klinik, Universität München; ^eAbteilung für Urologie, Bundeswehrkrankenhaus Hamburg;
^fAbteilung für Urologie, Albertinen-Krankenhaus, Hamburg, ^gInstitut für medizinische Informatik, Biometrie und
Epidemiologie, Universität Essen, Deutschland

Key Words

Seminoma, prognostic factors · Human chorionic gonadotropin · Multicenter study, seminoma · Radiotherapy

Abstract

Objective: In a prospective multicenter trial, it was our intention to elucidate clinical prognostic factors of seminomas with special reference to the importance of human chorionic gonadotropin (HCG) elevations in histo-

logically pure seminomas. **Methods:** Together with 96 participating urological departments in Germany, Austria, and Switzerland, we recruited 803 seminoma patients between 1986 and 1991. Out of 726 evaluable cases, 378 had elevated, while 348 had normal HCG values in the cubital vein. Histology was reviewed by two reference pathologists. HCG levels were determined in local laboratories and in a study laboratory. Standard therapy was defined as radiotherapy in stages I (30 Gy) and IIA/B (36 Gy) to the paraaortal and the ipsilateral (stage I) and bilateral (stage IIA/B) iliac lymph nodes; higher stages received polychemotherapy and surgery in case of residual tumor masses. Statistics included chi-square tests, linear Cox regression, and log-rank test. **Results:** The HCG elevation is associated with a larger tumor mass (primary tumor and/or metastases). HCG-positive and HCG-negative seminomas had no different prognostic outcome after standard therapy. The overall relapse rate of 6% and the survival rate of 98% after 36 months (median) indicate an excellent prognosis. The calculation of the relative risk of developing a relapse discovered only stage of the disease and elevation of the lactate dehydrogenase concentration and its prolonged

¹ Participating hospitals with ≥ 5 evaluable cases: Kantonsspital, Basel; Krankenhaus Moabit, Berlin; Klinikum Benjamin Franklin, Berlin; Krankenhaus Am Urban, Berlin; Urologische Universitätsklinik, Bonn; Krankenanstalten, Düren; Klinik Golzheim, Düsseldorf; Bundeswehrkrankenhaus, Hamburg; Urologische Universitätsklinik, Hannover; Allgemeines Öffentliches Krankenhaus, Klagenfurt; Krankenhaus Holweide, Köln; Urologische Universitätsklinik, Lübeck; Marienhospital, Marl; Elisabeth-Krankenhaus, Mönchengladbach-Rheydt; Klinikum Grosshadern, München; Landeskrankenanstalten, Salzburg; Städtisches Krankenhaus, Salzgitter-Bad; Evangelisches Jung-Stilling-Krankenhaus, Siegen; Katharinenhospital, Stuttgart; Krankenhaus der Barmherzigen Brüder, Trier; Krankenhaus der Barmherzigen Brüder, Wien; Krankenhaus Rudolfstiftung, Wien; Universitätsklinik, Wien; Stadtkrankenhaus, Worms; Klinikum Barmen, Wuppertal.

marker decay as independent prognostic factors for seminomas. A more detailed analysis of the prognostic significance of the stage revealed that the high relapse rate in stage IIB seminomas after radiotherapy (24%) is responsible for this result. **Conclusions:** We conclude that HCG-positive seminomas do not represent a special entity. Provided standard therapy is applied, HCG has no influence on the prognosis. Patients with stage IIB disease should be treated with chemotherapy because of the demonstrated higher relapse rate outside the retroperitoneum.

Copyright © 1999 S. Karger AG, Basel

Introduction

Elevations of human chorionic gonadotropin (HCG) levels in histologically pure seminomas lead to conjectures about the histological origin, the prognosis, and the adequate therapy of these tumors.

While elevated α -fetoprotein (AFP) levels are inconsistent with the diagnosis of a pure seminoma [1], immunohistochemistry was able to demonstrate syncytiotrophoblastic giant cells and even mononuclear seminoma cells to be the origin of the HCG production [2, 3]. Moreover, marker investigations of blood samples of the testicular vein demonstrated that nearly all seminomas are able to produce HCG [4]. Reviewing the published results of other investigators, we revealed an incidence of about 20% of the seminomas with elevated HCG serum titers in the cubital vein and that a positive immunohistological staining was successful in only 14% of the cases [5].

The supposed poor prognosis of HCG-positive seminomas was supported [6–9] or refuted [10–19] by reports on small series. It was discussed, whether it represented an intermediate form between seminomas and nonseminomas [20]. This disagreement contributed to the uncertain situation and resulted in various recommendations to treat HCG-positive seminomas. At the Consensus Conference in Hull [21] it was suggested to regard patients with HCG values >200 U/l as having nonseminomas.

In 1986 we initiated a prospective multicenter trial to assess prognostic factors of seminomas with special regard to the influence of HCG. In this paper, we want to clarify the mystery surrounding HCG-positive seminomas: (1) Do HCG-positive and negative seminomas have different stage distributions? (2) Do they have a different prognostic outcome after standard therapy? (3) Are there any other prognostic factors than HCG elevations in seminomas?

Table 1. Distribution of HCG values in HCG-positive seminomas (n = 375)

HCG, IU/l	n	%
<30	182	49
20–50	61	16
50–200	68	18
200–1,000	40	11
>1,000	24	6

Patients and Methods

All patients having seminomas with serologically positive HCG entered the study. AFP-positive tumors were excluded. Between January 1986 and December 1991, 803 patients from 96 urological departments were recruited, 515 of these prospectively.

77 patients had to be excluded (elevated AFP, nonseminomas, extragonadal tumors, missing data); in 8 patients the reference pathologist found nonseminomatous elements. 726 cases were evaluable. Out of them, 378 had elevated HCG levels in the cubital vein before (n = 375) or after (n = 3) orchiectomy (table 1). 348 patients had normal HCG values. Overall, marker determinations were performed in 726 patients for HCG and AFP, in 440 for lactate dehydrogenase (LDH) and in 174 for PIAP. The markers were determined in local laboratories by using different commercial assays. A second sample was sent to the study laboratory in Munich. The tumor markers were considered elevated, if the values exceeded the normal ranges. To determine a normal/prolonged marker decay, we used half-lives of 36 h for HCG and of 24 h for LDH and PIAP. However, we had to consider that the markers could be evaluated only according to the *clinical* stage.

For staging purposes we used the following classification: I – no metastases; IM – no visible metastases, but elevated tumor markers after orchiectomy; IIA – solitary lymph node metastasis <2 cm; IIB₁ – multiple lymph node metastases <2 cm; IIB₂ – lymph node metastases 2–5 cm; IIC – lymph node metastases >5 cm, and III – lymph node metastases above the diaphragm and/or distant metastases.

We recommended a stage-dependent therapy: stage I – infradiaphragmatic radiation with 30 Gy (ipsilateral iliacal lymph nodes); stage IIA/B – infradiaphragmatic radiation with 36 Gy (with iliacal lymph nodes included), and stages IM, IIC, and III – primary chemotherapy and/or surgical resection of residuals. However, RPLND and adjuvant chemotherapy in stage IIA/B were allowed because of the uncertainty in that stage. 84% of the patients received standard therapy (radiotherapy in stage I–IIB and polychemotherapy and surgery in case of residual tumor masses in stage IIC–III). The median radiation dose was 30 (range 26–36) Gy in stage I and 36 (range 30–41) Gy in stage IIA/B.

Statistics

For a suggested association between two continuous variables, the linear correlation was used. Independent variables were tested by a chi-square (Pearson test with Yates' correction, and for special tests with low cell counts, Fisher's exact test was used. To illustrate differences in progression risk for stage and for HCG status, Kaplan-Meier

curves are given. A multivariate analysis of prognostic variables seemed not to be appropriate because the numbers of relapses were too low (6% of the whole group). The Cox proportional hazards model was used in order to assess how a putative prognostic factor actually affects the risk of progression. As tumor stage is obviously a prognostic factor, the other variables were stratified according to the four levels 'stage I', 'stage IIA', 'stage IIB', and 'stage IIC/III'. The stratified relative risk estimates can be interpreted as the excess risk modification when the stage is already considered. Unstratified risk estimates are given for comparison. All relative risk estimates are calculated along with confidence intervals at the local 5% level. Continuous variables have been polychotomized at clinically motivated points. Patient not receiving standard therapy have been excluded from this analysis. Patients who developed a secondary tumor or a contralateral testicular tumor were considered observed without progression up to that point and censored at that point.

Results

The stage distribution (for this analysis we used only those patients who were consecutively documented in 14 of the participating hospitals) showed significant differences for HCG-positive and HCG-negative seminomas. 72% of all patients had stage I disease. HCG-positive seminomas were more often associated with metastatic disease than HCG-negative cases (37 vs. 18%, $p < 0.0001$), predominantly with larger retroperitoneal lymph node metastases.

8 of 515 prospectively enrolled patients had nonseminomatous elements when the histological slides were reviewed. Immunohistochemistry was positive in 59% of the serologically HCG-positive seminomas.

98% of the patients are alive after a median follow-up period of 36 months after standard therapy. 7 patients died of their disease, and 3 patients died of therapy-related complications (leukopenia after chemotherapy for multiple relapses, pulmonary embolism under chemotherapy for relapse after radiotherapy, and respiratory insufficiency after retroperitoneal lymph node dissection after chemotherapy). 3 patients died of other causes, and a further 2 of unknown reasons. 42 patients (6%) developed a relapse, 22 (3%) a contralateral testis tumor, and 9 (1%) a secondary nontesticular carcinoma.

There were no differences in the relapse-free survival rates between HCG-positive and HCG-negative seminomas. Significant associations between relapse and pI category, LDH level elevation, and metastases could be established (table 2). The HCG level had no influence on the prognosis of the outcome: either a simple elevation or levels >200 U/l or a prolonged marker decay. A multivariate analysis was not done because of the small number of relapses.

Table 2. Univariate analysis of parameters predictive for progressive disease 24 months after standard therapy

Variable		Patients	Progression, %	p
pT category	pT1	434	5	<0.01
	>pT1	94	13	
Infiltration of				
Rete testis	no	298	7	NS
	yes	230	5	
Tunica albuginea	no	475	5	0.022
	yes	53	13	
Epididymis	no	491	5	<0.01
	yes	37	16	
Spermatic cord	no	500	6	<0.0061 (trend)
	yes	28	14	
Vascular invasion				
	no	242	5	NS
	yes	112	10	
Size of primary tumor, cm				
	<3	126	2	0.054 (trend)
	3-6	253	6	
	6-10	123	6	
	>10	30	13	
Size of primary tumor, cm				
	<6	379	4	NS
	≥ 6	153	7	
Immunohistochemistry				
	negative	157	8	NS
	positive	158	7	
HCG				
	normal	280	4	NS
	elevated	321	7	
HCG level, U/l				
	<200	533	5	NS
	>200	54	9	
HCG decay				
	normal	261	6	NS
	prolonged	66	11	
LDH				
	normal	245	3	0.015
	elevated	115	9	
LDH decay				
	normal	175	6	0.05
	prolonged	38	16	
PIAP				
	normal	47	0	0.073 (trend)
	elevated	92	7	
PIAP decay				
	normal	61	2	NS
	prolonged	21	5	
Metastases				
	no	427	4	<0.01
	yes	165	10	
Stage				
	I	427	4	<0.0001
	Im	16	6	
	IIA	42	2	
	IIB ₁	23	13	
	IIB ₂	15	33	
	IIC/III	69	9	

Table 3. Relative risk rates for different levels of diagnostic measures, stratified according to tumor stage

Level	Number of patients	Number of patients with progression	Nonstratified risk with 95% confidence interval			Stratified risk with 95% confidence interval		
			lower boundary	relative risk	upper boundary	lower boundary	relative risk	upper boundary
Stage I	454	18						
Stage IIA	44	1	0.1	0.6	4.2			
Stage IIB	38	8	2.4	5.6	12.8			
Stage IIC/III	69	7	1.2	2.8	6.7			
No metastases	438	17						
Metastases	167	17	1.4	2.7	5.3			
Missing	61	6						
Tumor size <3 cm	128	2						
Tumor size 3–6 cm	262	15	0.6	1.4	3.3	0.6	1.4	3.3
Tumor size 6–10 cm	124	7	0.5	1.4	3.8	0.4	1.1	3.1
Tumor size >10 cm	26	4	0.9	3.1	10.4	0.6	2.2	8.0
Missing	65	1						
pT ₁	444	21						
pT ₂	68	8	1.3	3.0	6.7	1.0	2.2	5.1
pT ₃	28	4	1.3	3.8	10.9	0.9	2.6	8.0
Missing	65	1						
Infiltration of rete testis	305	21	0.3	0.7	1.4	0.4	0.8	1.6
Missing	65	1						
Infiltration of tunica albuginea	485	26	1.1	2.5	5.9	1.0	2.4	5.6
Missing	65	1						
Infiltration of epididymis	503	27	1.5	3.7	8.9	0.8	2.0	5.2
Missing	65	1						
Infiltration of germinal cord	512	29	1.0	2.8	8.1	0.7	2.0	6.0
Missing	243	9						
No vascular invasion	247	14						
Vascular invasion	115	11	0.7	1.6	3.6	0.6	1.4	3.1
Missing	61	6						
Negative immunohistochemistry	164	12						
Positive immunohistochemistry	158	13	0.5	1.2	2.6	0.5	1.2	2.6
HCG normal	349	15						
HCG elevated	256	19	0.9	1.8	3.5	0.7	1.4	2.8
HCG <200 U/l	550	58						
HCG >200 U/l	55	6	0.9	2.1	5.1	0.7	1.7	4.5
Missing	270	11						
HCG decay normal	269	15						
HCG decay prolonged	66	8	0.9	2.2	5.2	0.6	1.7	4.7
Missing	234	17						
LDH normal	269	15						
LDH elevated	117	10	1.2	3.2	8.4	1.1	3.1	8.8
Missing	386	16						
LDH decay normal	182	11						
LDH decay prolonged	37	7	1.2	3.2	8.3	1.0	3.0	9.5
Missing	464	27						
PIAP normal	47	0						
PIAP elevated	94	7	–	–	–	–	–	–
Missing	520	32						
PIAP decay normal	65	1						
PIAP decay prolonged	20	1	0.2	3.3	52.8	0.4	6.2	98.9

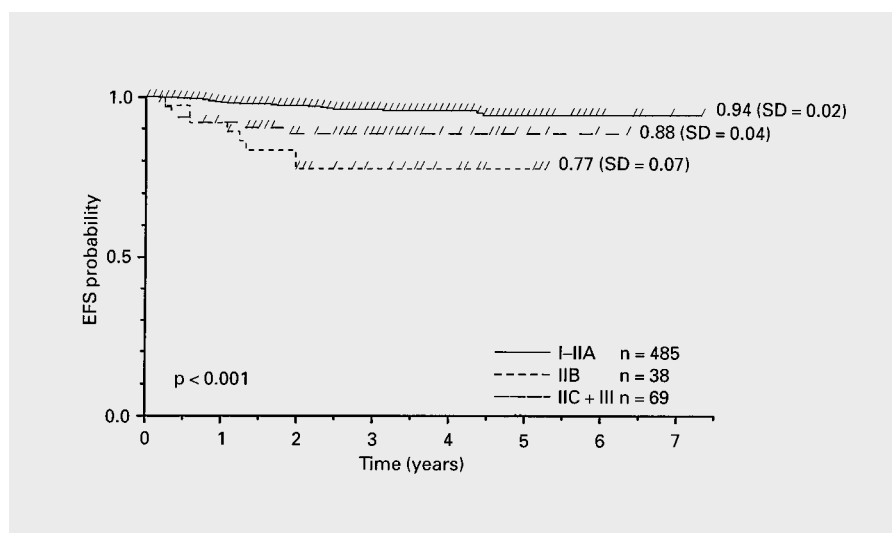


Fig. 1. Stage-related relapse-free survival of patients with seminomas after standard therapy. EFS = Event-free survival.

Instead of this, we calculated the relative risk of developing a relapse (table 3): stage IIB had the highest risk after radiotherapy. Moreover, an elevation of the LDH level and its prolonged marker decay seem to be independent predictive factors for a relapse because the relative risk does not change when we stratify for clinical stage.

The cumulative relapse-free 3-year survival rate in stage I was 94% for HCG-positive and 96% for HCG-negative seminomas. The results in stage IIA (one positive node <math>< 2</math> cm) were similar. Patients with stage IIB had a worse prognosis after radiotherapy, especially when the lymph nodes exceeded 2 cm (tables 2, 3). The relapse rate of irradiated stage IIB patients is even higher than that of patients with more advanced stages after chemotherapy. Comparison of the relapse rate of stage IIB patients revealed a significant difference from patients with lower stages and an obvious but not significant difference from patients with higher stages (fig. 1).

Details of the relapsing patients are summarized in table 4. 6 or 7 patients out of 9 developed their relapse outside the retroperitoneum.

Discussion

The primary histological diagnostic error was very low, as only 1.5% of the patients had nonseminomatous elements in the histological material reviewed. In our series, the meticulous histological investigations resulted in a better correlation between the serologically measured HCG values and the immunohistochemical staining than

described in the literature. 59% of the specimens stained positive, whereas the early publications reported on 14% HCG-positive stainings by immunohistochemistry [5]. During the course of the study, it was shown that about 80% of the patients with seminomas had elevated HCG values in the testicular vein, even when the samples from the cubital vein were negative [4, 22]. Today, we have to assume that each seminoma is able to produce HCG. This assumption is supported by the fact that HCG could be stained in STGC or mononuclear seminomas despite negative serum values. Thus, we have to conclude that an HCG-positive seminoma is not a special entity.

We could demonstrate that pathological HCG levels are correlated with the total tumor burden, i.e., the size of the primary tumor as well as the stage of the disease [23]. Our data confirm the results of other authors who found higher stages in seminomas with HCG or LDH elevations [1, 24, 25].

The prognosis of HCG-positive seminomas has been a subject of debate. Some investigators have observed the same good results as for HCG-negative seminomas [10, 14, 16, 18, 19, 26–28], while others stated a poorer outcome [6, 7, 17, 29–32]. Nearly all reports were based on small, retrospectively documented series. Only the retrospective analysis of Mirimanoff et al. [25] attained 132 HCG-positive cases from ten centers in Switzerland. Schwartz et al. [33] reported on 191 stage I seminomas that could be completely reviewed, retrospectively. 13% of them had preoperatively elevated serum levels of HCG. All normalized after orchiectomy, and none suffered a recurrence after a median follow-up period of 50

Table 4. Characteristics of the patients with relapse in stage IIA/B

No.	Stage ^a	HCG	Radiation Gy ^b	Time to relapse months	Localization of relapse	Marker AFP	Elevated HCG	Elevated LDH	Relapse PIAP	Treatment of relapse	Outcome months ^c
8007/01	IIB ₂	+	P 42	24	mediastinum	-	+	+	?	4 × carboplatin	NED 52
A110/01	IIB ₂	+	P 38	24	retroperitoneum	-	+	+	+	4 × PEB	NED 17
5600/04	IIB ₂	+	P+S 40	4	bone	?	?	+	?	radiation, surgery, 4 × PEB	DOD
5600/08	IIB ₂	+	P+S 36	9	marker only	-	+	-	?	1 × PEB, radiation	NED 42
5600/09	IIB ₂	+	P 36	6	bone	-	+	?	?	4 × PEB	DOD
2007/51	IIB ₁	+	P 40	15	retrosternal	-	+	-	?	3 × PEB	lost to follow-up
7000/04	IIB ₂	-	P 29	12	retroperitoneum	?	?	?	?	surgery + radiation	lost to follow-up
1004/25	IIB ₂	-	P 36	15	retroperitoneal + pulmonary	?	?	?	?	4 × PEB	NED 48
8007/08	IIB ₁	-	P 40	2	bone	-	+	+	-	4 × VIP	NED 45

^a Stage IIB₁ = Lymph node metastases <2 cm; IIB₂ = lymph node metastases 2–5 cm.

^b P = Periaortal; S = supradiaphragmal.

^c NED = No evidence of disease; DOD = died of disease.

months. In our literature review we found no difference between HCG-positive and HCG-negative seminomas in stage I. A poorer outcome was demonstrated only in metastatic (and unknown) stages.

According to our results, the prognosis was excellent when standard therapy was applied (radiotherapy in stages I–IIB and polychemotherapy and/or surgery for residuals in stages IIC/III) after a median follow-up period of 36 months. Only 6% of the entire group relapsed, and 98% are alive and free from disease. There was no difference between HCG-positive and HCG-negative seminomas. All stages had comparable relapse and survival rates.

In none of our analyses we found an influence of HCG on the prognosis. This is valid for the simple preoperative HCG elevation and values >200 U/l as well. The limit of 200 U/l was defined at the Consensus Meeting in Hull [21]: As to the experience of most of the participants, high HCG titers were predominantly observed in bulky tumors which require chemotherapy anyway. For the expected

small number of patients with seminomas with HCG titers >200 U/l and small metastatic lymph nodes, the participants precautiously recommended chemotherapy. Our results conclude this would apply to only 3% of all seminomas and to 8% of the HCG-positive seminomas.

In contrast, patients with elevated LDH levels had a significantly worse prognosis ($p = 0.015$), and those with elevated PIAP showed a trend to a poorer outcome ($p = 0.073$) than patients with normal marker values. The calculation of the relative risk discovered only clinical stage and the elevation of the LDH concentration and its prolonged marker decay as independent prognostic factors. Interestingly, stage IIB patients had the worst therapeutic outcome as compared with all other stages when standard therapy was applied. As even more advanced stages had a more favorable outcome, it must be concluded that radiotherapy for stage IIB seminomas should no longer be regarded as standard therapy. After radiotherapy, the relapse-free survival rate was only 75% for HCG-positive and 76% for HCG-negative seminomas. A comparison

Table 5. Literature review of the results of radiotherapy in stage IIA/B seminoma

Authors	Year of publication	n	Relapse-free survival, %	Survival %	Relapse rates, %	
					IIA	IIB
Evensen et al. [9]	1985	24	96	100	0	6
Gregory and Peckham [12]	1986	39	87	95	11	18
Zagars and Babian [36]	1987	37	95	95	?	?
Mason and Kearsley [37]	1988	25	96	96	?	?
Pfannmüller-Schurr et al. [35]	1988	69	88	?	0	24
Kellokumpu-Lehtinen and Halme [15]	1990	56	82	94	?	?
Bayens et al. [34]	1992	29	76	93	0	33
Hanks et al. [13]	1992	107	96	97	?	?
Gospodarowicz et al. [11]	1994	56	89	96	12	9
Present series		80	87	97	2	24
Overall		522	90	96	7	22

Table 6. Relapse sites (n = 28) after radiotherapy in stage IIA/B seminomas [11, 12, 15, 34] (multiple sites possible)

Localization	n
Abdomen	6
Mediastinal/supraclavicular, or supradiaphragmatic	14
Pulmonal	5
Hepatic	1
Bones	6
Miscellaneous	3

with other published results was hampered by the fact that most radiotherapists use classifications that do not allow a safe differentiation of stages IIA and IIB from higher stages. Some even classify lymph node masses of up to 10 cm as IIA [8]. We summarized the data of seminomas with low-volume metastases, considering only reports with at least 20 cases in stage IIA/B (table 5), and found the same trend as in our study. Patients with metastases between 2 and 5 cm had a recurrence rate of 22% (range 6–40%) [12, 34, 35]. Most of the relapses are localized outside the retroperitoneum (table 6), presuming a systemic disease which requires systemic therapy. 30% of the relapsing patients died of their disease. Despite the small number of cases evaluated, we recommend chemotherapy for these patients, especially because patients with stage IIC/III had a better outcome after chemotherapy than those with stage IIB after radiotherapy.

Concluding Remarks

HCG-positive seminomas have significantly higher stages than those with normal values in the cubital vein. HCG has no negative influence on the relapse rate of seminomas. The risk of relapse is higher for patients with pT category higher than 1 and for those with elevated LDH levels. Obviously, seminomas – irrespective of their HCG status – are sufficiently treated by the current standard therapy. Therapy should only be altered in stage IIB (metastases 2–5 cm), as local radiotherapy cannot prevent the demonstrated systemic relapses. Therapy recommendations are radiotherapy for patients with clinical stages I and IIA (no lymph node metastases or <2 cm) and chemotherapy for patients with lymph nodes >2 cm or distant metastases.

Acknowledgment

This work was supported by the Ministry of Research and Technology of the Federal Republic of Germany (Grant No. 0701915).

References

- 1 Rustin GJS, Vogelzang NJ, Sleijfer DT, Nisselbaum JN: Consensus Statement on Circulating Tumour Markers and Staging Patients with Germ Cell Tumours. EORTC Genitourinary Group Monograph 7: Prostate Cancer and Testicular Cancer. New York, Wiley-Liss, 1990, pp 277–284.
- 2 Henkel K, Tschubel K, Bussar-Maatz R: Die Morphologie des HCG-positiven Seminoms; in Weissbach L, Hildenbrand G (eds): Register und Verbund-Studie für Hodentumoren – Bonn. Ergebnisse einer prospektiven Untersuchung. München, Zuckschwerdt, 1982, pp 73–82.
- 3 Kurmann RJ, Scardino PT, McIntire KR, Waldmann TA, Javadpour N: Cellular localization of a-fetoprotein and human chorionic gonadotropin in germ cell tumors of the testis using an indirect immunoperoxidase technique. *Cancer* 1977;40:2136.
- 4 Mumperow E, Hartmann M: Spermatic cord β -human chorionic gonadotropin levels in seminoma and their clinical implications. *J Urol* 1992;147:1041–1043.
- 5 Weissbach L, Bussar-Maatz R: HCG-positive seminoma. *Eur Urol* 1993;23(suppl 2):29–32.
- 6 Butcher DN, Gregory WM, Gunter PA, Masters JRW, Parkinson MC: The biological and clinical significance of HCG-containing cells in seminoma. *Br J Cancer* 1985;51:473–478.
- 7 Caillaud JM, Bellet D: Etude par immunoperoxidase de 80 tumeurs germinales testiculaires de l'adulte. *Nouv Presse Méd* 1981;10:1057–1060.
- 8 Dosmann MA, Zagars GK: Post-orchietomy radiotherapy for stages I and II testicular seminoma. *Int J Radiat Oncol Biol Phys* 1993;26:381–390.
- 9 Evensen JF, Fossa SD, Kjellevoid K, Lien HH: Testicular seminoma: Analysis of treatment and failure for stage II disease. *Radiother Oncol* 1985;4:55–61.
- 10 Fossa A, Fossa SD: Serum lactate dehydrogenase and human chorionic gonadotropin in seminoma. *Br J Urol* 1989;63:408–415.
- 11 Gospodarowicz MK, Warde PR, Pazarella T, et al: The Princess Margaret Hospital experience in the management of stage I and II seminoma – 1981 to 1991; in Jones WG, Harnden P, Appleyard I (eds): *Germ Cell Tumours*. Oxford, Pergamon Press, 1994, vol III, pp 177–186.
- 12 Gregory C, Peckham MJ: Results of radiotherapy for stage II testicular seminoma. *Radiother Oncol* 1986;6:285–292.
- 13 Hanks GE, Peters T, Owen J: Seminoma of the testis: Long-term beneficial and deleterious results of radiation. *Int J Radiat Oncol Biol Phys* 1992;24:913–919.
- 14 von Hochstetter AR, Sigg C, Saremaslani P, Hedinger C: The significance of giant cells in human testicular seminomas. *Virchows Arch A Pathol Anat Histopathol* 1985;407:309–322.
- 15 Kellokumpu-Lehtinen P, Halme A: Results of treatment in irradiated testicular seminoma patients. *Radiother Oncol* 1990;18:1–7.
- 16 Kratzik C, Kubler W: Metastasierung beim Seminom des Hodens mit besonderer Berücksichtigung des HCG-positiven Seminoms: Eine Registerauswertung. *Verhandlungsbericht der 34. Tagung der Deutschen Gesellschaft für Urologie* 1982.
- 17 Lang PH, Nochmovitz LE, Rosai J, et al: Serum alpha-fetoprotein and human chorionic gonadotropin in patients with seminoma. *J Urol* 1980;124:473.
- 18 Mauch P, Weichselbaum R, Botnick L: The significance of positive chorionic gonadotropins in apparently pure seminoma of the testis. *Int J Radiat Oncol Biol Phys* 1979;5:887–889.
- 19 Mirimanoff RO, Shipley WU, Dosoretz DE, Meyer JE: Pure seminoma of the testis: The results of radiation therapy in patients with elevated human chorionic gonadotropin titers. *J Urol* 1985;134:1124–1126.
- 20 Dieckmann KP, Düe W, Bauer HW: Seminoma testis with elevated serum beta-HCG – a category of germ cell cancer between seminoma and nonseminoma. *Int Urol Nephrol* 1989;21:175–184.
- 21 Thomas G, Jones W, van Oosterom A, Kawai T: Consensus statement on the investigation and management of testicular seminoma 1989; in Newling DW, Jones WG (eds): *Prostate Cancer and Testicular Cancer*. New York, Wiley-Liss, 1990, pp 285–294.
- 22 Hartmann M, Pottek T, Bussar-Maatz R, Weissbach L: Elevated HCG concentrations in the testicular vein and in peripheral venous blood in seminoma patients: An analysis of various parameters. *Eur Urol* 1997;31:408–413.
- 23 Weissbach L, Bussar-Maatz R, Mann K: The value of tumor markers in testicular seminomas: Results of a prospective multicenter study. *Eur Urol* 1997;32:13–19.
- 24 Fossa SD, Risberg T: β -HCG producing seminoma; in Khoury S, Küss R, Murphy GP, Chatelain C, Karr JP: *Testicular Cancer*. New York, Liss, 1985, pp 105–106.
- 25 Mirimanoff RO, Sinzig M, Kruger M, Mirabell R, Thoni A, Ries G, Bosset JF, Bernier J, Bolla M, Nguyen TD, et al: Prognosis of human chorionic gonadotropin producing seminoma treated by postoperative radiotherapy. *Int J Radiat Oncol Biol Phys* 1993;27:17–23.
- 26 Bal D, Barrett A, Peckham MJ: The management of metastatic seminoma testis. *Cancer* 1982;50:2289–2294.
- 27 Bartsch G, Mikuz G, Fommhold H, Scheiber K: Treatment of seminoma: Does a positive HCG influence prognosis? In Khoury S, Küss R, Murphy GP, Chatelain C, Karr JP: *Testicular Cancer*. New York, Liss, 1985, pp 483–484.
- 28 Swartz DA, Johnson DE, Hussey DH: Should an elevated human chorionic gonadotropin titer alter therapy for seminoma? *J Urol* 1984;131:63–65.
- 29 Morgan DAL, Caillaud JM, Bellet D, Eschwege F: Gonadotrophin-producing seminoma: A distinct category of germ cell neoplasm. *Clin Radiol* 1982;33:149–153.
- 30 Mostofi FK: Pathology of germ cell tumors of testis: A progress report. *Cancer* 1980;45:1735–1754.
- 31 Percarpio B, Clements JC, McLeod DG, Sorgen SD, Cardinale FS: Anaplastic seminoma: An analysis of 77 patients. *Cancer* 1979;43:2510–2513.
- 32 Roth A, le Pelletier O, Cukier L: Cryptocarcinome trophoblastique à cellules mononucléées sécrétrices d'hormones gonadotrophiques chorioniques bêta dans les séminomes: Valeur pronostique. *Presse Méd* 1983;12:2801–2804.
- 33 Schwartz BF, Auman R, Peretsman SJ, Moul JW, Deshon GE, Hernandez J, Rozanski TA, Thrasher JB: Prognostic value of BHCG and local tumor invasion in stage I seminoma of the testis. *J Surg Oncol* 1996;61:131–133.
- 34 Bayens YC, Helle PA, Van Putten WLJ, Mali SPM: Orchietomy followed by radiotherapy in 176 stage I and II testicular seminoma patients: Benefits of a 10-year follow-up study. *Radiother Oncol* 1992;25:97–102.
- 35 Pfannmüller-Schurr EL, Hodapp N, Bruggmoser G, Wannenmacher M: Strahlentherapie der Seminome im Stadium II A/B; in Schmoll HJ, Weissbach L (eds): *Diagnostik und Therapie von Hodentumoren*. Berlin, Springer, 1988, pp 409–414.
- 36 Zagars GK, Babian RJ: The role of radiation in stage II testicular seminoma. *Int J Radiat Oncol Biol Phys* 1987;13:163–170.
- 37 Mason BR, Kearsley JH: Radiotherapy for stage 2 testicular seminoma: The prognostic influence of tumor bulk. *J Clin Oncol* 1988;6:1856–1862.