

Lower Limb Radiology of Distal Myopathy due to the S60F Myotilin Mutation

Alisdair McNeill^a Daniel Birchall^b Volker Straub^c Lev Goldfarb^d Peter Reilich^e
Maggie C. Walter^e Nicolai Schramm^f Hanns Lochmüller^c Patrick F. Chinnery^{c, g}

^aClinical Genetics Unit, Birmingham Women's Hospital, Birmingham, ^bNeuroradiology, Regional Neurosciences Centre, Newcastle General Hospital, and ^cMRC Neuromuscular Centre, Institute of Human Genetics, International Centre For Life, Newcastle upon Tyne, UK; ^dClinical Neurogenetics, National Institute of Neurological Disorders and Stroke, Bethesda, Md., USA; ^eFriedrich Baur Institute, Department of Neurology, and ^fClinical Radiology, Ludwig Maximilians University of Munich, Munich, Germany; ^gMitochondrial Research Group, The Medical School, University of Newcastle upon Tyne, Newcastle upon Tyne, UK

Key Words

Distal myopathies · Lower limb radiology · Myotilinopathy · S60F myotilin mutation · Titin myopathy · *TTID* mutation · Welander distal myopathy

Abstract

Distal myopathies are a clinically and genetically heterogeneous group of disorders in which the distal limb musculature is selectively or disproportionately affected. Precisely defining specific categories is a challenge because of overlapping clinical phenotypes, making it difficult to decide which of the many known causative genes to screen in individual cases. In this study we define the distinguishing magnetic resonance imaging findings in myotilin myopathy by studying 8 genealogically unrelated cases due to the same point mutation in *TTID*. Proximally, the vastii, biceps femoris and semi-membranosus were involved with sparing of gracilis and sartorius. Distally, soleus, gastrocnemius, tibialis anterior, extensor hallucis and extensor digitorum were involved. This pattern contrasts with other distal myopathies and provides further support for the role of imaging in the clinical investigation of muscle disease.

Copyright © 2009 S. Karger AG, Basel

Introduction

Distal myopathies are a clinically and genetically heterogeneous group of disorders in which the distal limb musculature is selectively, or disproportionately, affected [1]. Mutations in genes coding for a diverse group of muscle proteins have been identified in affected pedigrees, including desmin [2–4], nebulin [5], dysferlin [6–12], titin [13], myosin [14] and *GNE* [15]. Mutations in the gene coding for myotilin (*TTID*), a Z-disc component, have recently been associated with a late-onset, autosomal-dominant distal myopathy [16–19]. Distal myopathies present a considerable diagnostic challenge because of the phenotypic overlap on clinical examination [1]. A definitive diagnosis rests upon molecular genetic testing [1], but the size and complexity of the multiple genes involved has limited comprehensive molecular analysis to a few research centres worldwide [1]. There is therefore a need to identify phenotypic markers which help to distinguish between the different genetic subtypes of distal myopathy, enabling accurate clinical diagnosis and targeted mutation analysis. Magnetic resonance imaging (MRI) is a useful tool in diagnosis of myopathies [20] and has been shown to dis-

Table 1. T₁ leg MRI appearances in myotilin myopathy due to the S60F *TTID* mutation. This table summarizes extent of muscle infiltration by fat on T₁ MRI scan where hyperintensity was used as a proxy measure for fat deposition

	A	B	C	D	E	F	G	H
Age, years	43	57	59	68	81	66	67	85
Disease duration, years	3	2	5	8	15	19	8	9
Proximal								
Iliopsoas	0	0	0	0	0	0	0	0
Rectus femoris	0	0	0	0	0	0	0	0
Vastus lateralis	0	+	0	+	0	+	0	+++
Vastus intermedius	0	+++	0	++	++	+++	0	+++
Vastus medialis	0	0	0	++	++	++	0	+++
Gluteal	+	+	0	0	0	+	0	+++
Obturator externus	0	0	0	0	0	0	0	0
Sartorius	0	0	0	+	0	+	0	0
Gracilis	0	0	0	0	0	0	0	0
Semitendinosus	0	0	0	+	0	+	0	+++
Semimembranosus	+	+++	++	++	+++	++	0	+++
Biceps femoris	+	+++	++	+	+	++	0	+++
Distal								
Tibialis anterior	+	++	0	++	+++	+++	+++	+
Tibialis posterior	+	+	0	+++	+++	+++	0	0
Extensor hallucis longus	0	+++	++	0	+++	+++	0	0
Extensor digitorum longus	0	+++	++	+++	+++	+++	0	0
Lateral gastrocnemius	0	+	0	+	+++	+	0	0
Medial								
gastrocnemius	0	+++	+++	+++	+++	+++	0	0
Soleus	0	+++	+++	+++	+++	+++	+++	+
Popliteal	0	0	0	0	+++	+++	+++	+
Flexor digitorum longus	0	0	0	0	0	0	0	0
Peroneus longus	0	++	++	+++	+++	++	0	0

0 = Muscle not involved; + = <30% of muscle involved by hyperintense lesions; ++ = 30–60% of muscle involved by hyperintense lesions; +++ = >60% of muscle involved by hyperintense lesions.

tinguish between Welander distal myopathy and titin myopathy [21]. Here, we sought to define the muscle MRI features of myotilin myopathy by studying a group of unrelated patients with the same *TTID* mutation. By comparing the pattern of muscle involvement to published data, we aimed to define the features distinguishing myotilin myopathy from the other distal myopathies.

Methods

In order to identify clear patterns of muscle involvement at different stages of the same disease, we studied 8 genealogically unrelated patients who carried the S60F *TTID* substitution with clinical evidence of a myopathy. T₁-weighted MRI scans of their legs were obtained. Images were independently analysed by two investigators (A.M. and D.B.) who were blinded to the clinical

features in each case. Increased T₁ signal within muscle was used to assess fat infiltration and semiquantitatively scored. Mild involvement (+) was classified as <30% of the muscle volume affected, moderate (++) as 30–60% affected and severe involvement (+++) >60% involved [20]. Twenty-two muscles in the proximal and distal leg were examined. Comparison with the literature was carried out by performing a systematic review using PubMed [www.pubmed.com] to identify descriptions of the MRI findings in other genetic subtypes of distal myopathy. Search terms included *magnetic resonance imaging, MRI, myotilin, nebulin, dysferlin, desmin, titin* and *myosin*.

Results

Clinical Features of the Affected Individuals

Patient A developed leg aches upon exertion aged 40. She was assessed aged 43 and noted to have mild proximal

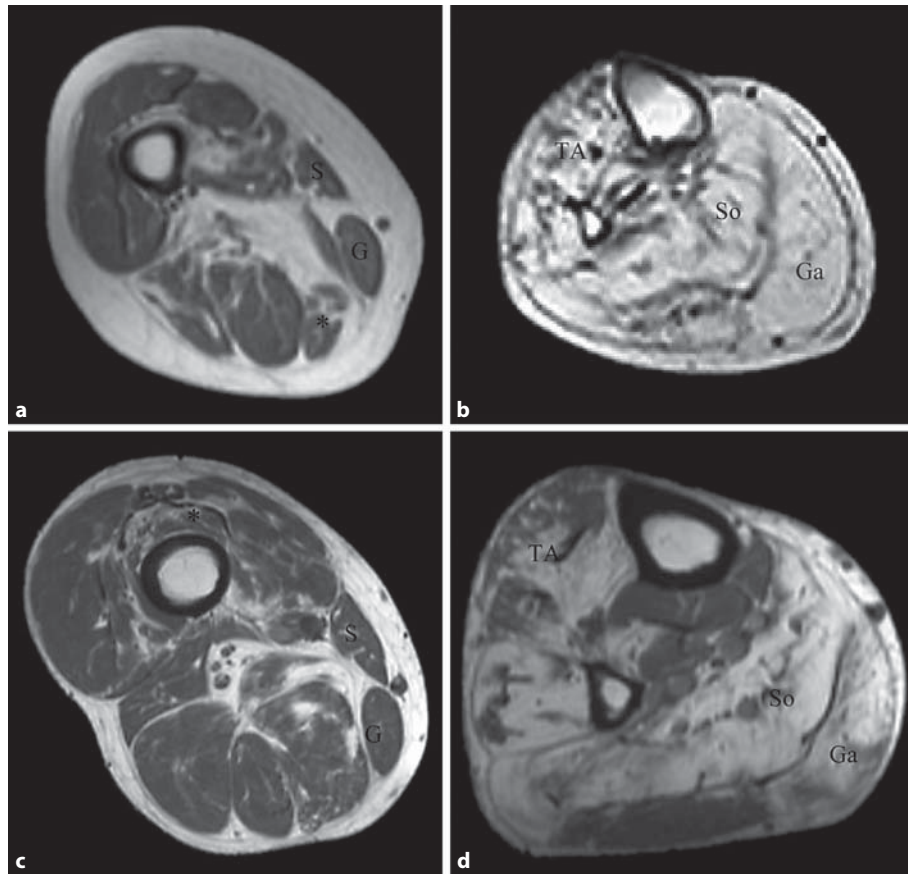


Fig. 1. T₁ MRI images from cases of myotilinopathy. **a** Axial image at mid-thigh from an 81-year-old woman (Patient E) with predominantly distal lower limb weakness. Note fatty infiltration of semi-membranosus (*), with sparing of gracilis (G) and sartorius (S). **b** Axial image at mid-calf from Patient E. Note extensive fatty infiltration of gastrocnemius (Ga), soleus (So) and tibialis anterior (TA). **c** Axial image at mid-thigh from a 68-year-old man (Patient D) with predominantly distal lower limb weakness. Note mild fatty infiltration of vasti (*), with sparing of sartorius (S) and gracilis (G). **d** Axial image at mid-calf from Patient D. Note fatty infiltration of medial gastrocnemius (Ga), soleus (So) and tibialis anterior (TA).

limb weakness. Creatine kinase (CK) was 150 U/l (normal <170 U/l). Electromyography (EMG) demonstrated myopathic changes. Her pulmonary function tests (PFTs) and echocardiogram were normal. Her father was affected by a distal myopathy and carried the S60F mutation.

Patient B is a woman who developed difficulty walking due to distal leg weakness aged 55. On examination aged 57 she had marked weakness of foot dorsiflexion and plantarflexion with Achilles tendon contractures. PFTs were normal. CK was 245 U/l (normal <170 U/l) and EMG demonstrated myopathic changes. No information on family history was available.

Patient C developed difficulty with stairs aged 54. She was assessed aged 59 years and had mild proximal arm and leg weakness, Achilles contractures and weakness of the long finger flexors. CK was 263 U/l (normal <170 U/l). EMG, echocardiogram and PFTs were not performed. No information on family history was available.

Patient D is a man who developed weakness of the finger extensors aged 59. He was assessed aged 68. On examination he had bilateral weakness of finger extensors

and bilateral weakness of foot dorsiflexors and plantarflexors. CK was 700 U/l (normal <180 U/l). EMG demonstrated mixed myopathic/neuropathic changes. PFTs and echocardiogram were normal. Patient D's parents had no history of muscle weakness, but his brother had distal arm and leg weakness and both his children carried the S60F myotilin mutation but were clinically normal.

Patient E is a woman who presented age 66 with foot drop. On examination at 81 years old she had proximal weakness of arms and legs (MRC 4/5) with absent dorsiflexion of both feet and weak plantarflexion of the feet (MRC 2/5). CK was 151 U/l (normal <150 U/l). EMG revealed mixed myopathic and neuropathic changes. There was no information on the health of Patient E's parents, but her children were clinically unaffected.

Patient F is a 66-year-old man who developed difficulty climbing stairs aged 45. Neurological examination revealed predominantly distal lower limb weakness with ankle dorsiflexion and plantarflexion MRC 1/5 and mild proximal weakness with knee flexion and hip adduction MRC 3/5. His echocardiogram was normal, and his PFTs

Table 2. Summary of the reported T₁ MRI features in adult-onset distal myopathies

Myopathy [ref.]	Gene involved	Proximal		Distal	
		affected	spared	affected	spared
Nebulin [5]	nebulin	VL, GRA, SAT	hamstrings, adductors	TA	SO, peroneal and posterior calf muscles
Miyoshi [6–12]	dysferlin	BF, SM	quadriceps	GA, SO	TA, TP, peroneal muscles
Welander [13–16]	locus 2p13		all	GA, SO, TA	TP, peroneal muscles
Tibial muscular dystrophy [13]	titin	hamstrings (rarely)	quadriceps	TA	GA, SO (usually)
DMRV [15]	<i>GNE</i>	BF, SM, ST	quadriceps	TA, TP, GA, EDL	SO
Desmin [2–4]	desmin	SM, ST, BF, GRA, SAT	quadriceps	TA, GA, EDL	
Zaspopathy [24]	<i>ZASP</i>	SM, ADM	GRA, SAT, quadriceps	GA, SO, EDL, TA	
ADMERF [23]	unknown	IP, OE, SAT, GRA, ST	SM, BF	TA, GA, SO, FDL	
Myotilinopathy [16–19]	<i>TTID</i>	vastii, SM, BF	GRA, SAT, ST	TA, TP, SO, GA, EDL, FDL, PL	FDL

VL = Vastus lateralis; GRA = gracilis; SAT = sartorius; BF = biceps femoris; SM = semimembranosus; ST = semitendinosus; ADM = adductor magnus; IP = iliopsoas; OE = obturator externus; TA = tibialis anterior; TP = tibialis posterior; GA = gastrocnemius; SO = soleus; EDL = extensor digitorum longus; FDL = flexor digitorum longus; PL = peroneus longus; EDL = extensor digitorum longus.

ADMERF = Autosomal-dominant myopathy with early respiratory failure; DMRV = distal myopathy with rimmed vacuoles.

suggested diaphragmatic weakness with a forced vital capacity of 2.41 l (64% of predicted) sitting and 2.26 l (60% of predicted) lying. The CK was mildly elevated (326 U/l). EMG was not performed. His father had late-onset muscle weakness and was wheelchair bound by age 64 years.

Patient G is a woman who developed a foot drop aged 59. At age 67, examination revealed mild weakness of wrist extension (MRC 4/5) and elbow flexion (MRC 4/5) with marked weakness of foot dorsiflexion and plantarflexion bilaterally (MRC 2–3/5). Echocardiogram and PFTs were normal. CK was 200 U/l (normal <200 U/l). EMG demonstrated a mixed myopathic/neuropathic picture. There was no family history of muscle weakness.

Patient H is a man who presented age 76 with bilateral foot drop and weak finger flexion. On examination at age 85 there was weak wrist extension (MRC 4/5) and foot dorsiflexion (MRC 1/5). Echocardiogram and PFTs were normal. CK ranged from 273 to 360 U/l (normal <180 U/l). EMG demonstrated a mixed myopathic/neuropathic picture. There was no evidence of myopathy in the family history other than his mother having difficulty walking from her mid-60s.

MRI Findings

The MRI findings are summarized in table 1 and illustrated in figure 1. In the proximal leg there was consistent extensive fatty infiltration of vastus intermedius (5/8) and vastus medialis (5/8) with relative sparing of vastus lateralis. The semimembranosus, semitendinosus or biceps femoris were involved in all but 1 case. The gracilis was spared in all cases, and sartorius spared in 6/8.

A consistent pattern of muscle involvement was also observed in the distal leg. The medial gastrocnemius was involved in 5/8 cases and the soleus in 7/8. The tibialis anterior and posterior, extensor hallucis longus, extensor digitorum longus and peroneus longus were consistently involved with varying degrees of infiltration. The lateral gastrocnemius (4/8) and popliteal muscles (4/8) were relatively spared. A summary of the literature review findings are presented in table 2.

Discussion

Myotilinopathy was first described in two families with a limb girdle muscular dystrophy 1A phenotype [22]. However, most subsequent myotilinopathy kindreds have manifested a predominantly distal myopathy. Myotilinopathy typically manifests as a distal lower limb myopathy with involvement of proximal leg muscles and distal arm muscles in some [16–19]. Variable features include cardiomyopathy, peripheral neuropathy and respiratory insufficiency [16–19]. The clinical phenotype thus overlaps significantly with other late-onset distal myopathies [1]. Here we provide a detailed description of the radiology of myotilinopathy due to the S60F *TTID* mutation, in an attempt to differentiate it from other distal myopathies.

In all cases there was involvement of both proximal and distal muscles, though the distal musculature was more heavily infiltrated with fat. The tibialis anterior, medial gastrocnemius and soleus were particularly affected in the distal leg whilst the vastus medialis and intermedius were targeted in the proximal leg. The more intense involvement of the distal limb fits with clinical descriptions of an initial distal myopathy spreading proximally. The radiology of our cases overlaps with that described by Berciano et al. [16] in two symptomatic myotilinopathy patients (S55F mutation). They report involvement of tibialis anterior and posterior, extensor digitorum and hallucis, medial gastrocnemius and soleus with proximal involvement of vasti, biceps femoris and semimembranosus. This suggests that there is a consistent radiological phenotype for distal myopathy associated with myotilin mutations, which may prove diagnostically useful.

The radiological features of distal myopathies are outlined in table 2. It can be seen that there are extensive overlaps between the different genetic subtypes. However, there are differences in the pattern of muscle involvement which help to distinguish between myotilinopathy and other distal myopathies. In the majority of cases associated with nebulin mutations, MRI changes are restricted to tibialis anterior, permitting clear distinction from the more widespread changes in myotilinopathy [5]. In advanced desminopathy there is extensive involvement of proximal and distal limb musculature similar to myotilinopathy, however gracilis and sartorius are involved in desminopathy, permitting distinction from myotilin mutations [2]. The soleus muscle is spared in distal myopathy with rimmed vacuoles (Nonaka myopathy), whilst this muscle is consistently involved in

myotilinopathy [15]. In both Welander and tibial muscular dystrophy the quadriceps are spared, permitting distinction from advanced cases of myotilinopathy where the vasti are involved [21]. In the majority of cases of distal dysferlinopathy (Miyoshi myopathy) the tibialis anterior is relatively spared, contrasting with its heavy involvement in myotilinopathy [6–12]. In autosomal-dominant myopathy with early respiratory failure, the semitendinosus is heavily involved from an early stage, whilst in the majority of cases of myotilinopathy this muscle is spared [23].

The radiological descriptions of the various myopathies are mostly from advanced cases with extensive muscle atrophy and fat infiltration. The radiological appearances of distal myopathies in the early stages may be substantially different, given that myofiber degeneration and not fatty infiltration will be the dominant process. There is some evidence of this in our cohort of myotilinopathy patients, with Patient A, who had a disease duration of 3 years, having relatively mild scan appearances, while Patients D–F and H who had disease durations of >10 years had florid fat infiltration on MRI. Thus, the radiological appearances of distal myopathies in the early stages may correspond incompletely with currently published descriptions, resulting in diagnostic confusion. This must be taken account of when examining muscle MRI in clinical practice. Here we provide a detailed description of the radiological features of myotilinopathy.

MRI of muscles reveals that the genetic subtypes of distal myopathy have distinct patterns of muscle involvement. This will assist in the clinical diagnosis of myotilinopathy and facilitate targeted mutation analysis leading to accurate diagnosis, followed by appropriate genetic and prognostic counselling.

Acknowledgements

P.F.C. is a Wellcome Trust Senior Fellow in Clinical Science. MD-NET and TREAT-NMD (V.S., M.W., H.L.); MRC Centre for Neuromuscular Disease (P.F.C., V.S., H.K.). V.S., H.L. and M.C.W. are members of the German Muscular Dystrophy Network (MD-NET 01GM0601) funded by the German Ministry of Education and Research (BMBF, Bonn, Germany); www.md-net.org. MD-NET is a partner of TREAT-NMD (EC, 6th FP, proposal # 036825; www.treat-nmd.eu). A.M. is an NIHR Academic Clinical Fellow.

References

- 1 Mastaglia FL, Lamont PJ, Laing NG: Distal myopathies. *Curr Opin* 2005;18:504–510.
- 2 Olive M, Armstrong J, Miralles F, et al: Phenotypic patterns of desminopathy associated with three novel mutations of the desmin gene. *Neuromuscul Disord* 2007;17:443–450.
- 3 Goldfarb LG, Vicart P, Goebel HH, Dalakas MC: Desmin myopathy. *Brain* 2004;127:723–734.
- 4 Olive M, Goldfarb L, Moreno D, et al: Desmin-related myopathy: clinical, electrophysiological, radiological, neuropathological and genetic studies. *J Neurol Sci* 2004;219:125–137.
- 5 Wallgren-Pettersen C, Lehtokari VL, Kalimo H, et al: Distal myopathy caused by homozygous missense mutations in the nebulin gene. *Brain* 2007;130:1465–1476.
- 6 Cupler EJ, Bohlega S, Hessler R, et al: Miyoshi myopathy in Saudi Arabia: clinical, electrophysiological, histopathological and radiological features. *Neuromuscul Disord* 1998;8:321–326.
- 7 Nguyen K, Bassez G, Krahm M, et al: Phenotypic study in 40 patients with dysferlin gene mutations: high frequency of atypical phenotypes. *Arch Neurol* 2007;64:1176–1182.
- 8 Brummer D, Walter MC, Palmbach M, et al: Long-term MRI and clinical follow-up of symptomatic and presymptomatic carriers of dysferlin gene mutations. *Acta Myol* 2005;24:6–16.
- 9 Meola G, Sansone V, Rotondo G, Jabbour A: Computerised tomography and magnetic resonance muscle imaging in Miyoshi's myopathy. *Muscle Nerve* 1996;19:1476–1480.
- 10 Okahashi S, Ogawa G, Suzuki M, Ogata K, et al: Asymptomatic sporadic dysferlinopathy presenting with elevation of serum creatine kinase. Typical distribution of muscle involvement shown by MRI but not CT. *Intern Med* 2008;47:305–307.
- 11 Long-Sun R, Guey-Jen L, Tzu-Ching L, et al: Phenotypic features and genetic findings in two Chinese families with Miyoshi distal myopathy. *Arch Neurol* 2004;61:1594–1599.
- 12 Illa I, De Luna N, Dominguez-Perles R, et al: Symptomatic dysferlin mutation carriers: characterization of two cases. *Neurology* 2007;68:1284–1287.
- 13 Udd B, Partanen J, Halonen P, et al: Tibial muscular dystrophy. Late adult-onset distal myopathy in 66 Finnish patients. *Arch Neurol* 2007;50:604–608.
- 14 Oldfors A: Hereditary myosin myopathies. *Neuromuscul Dis* 2007;17:355–367.
- 15 Mizuno T, Motonaga T, Yanagida K, et al: MRI findings in studies of distal myopathy with rimmed vacuoles. *Rin Shin* 1989;29:1290–1293.
- 16 Berciano J, Gallardo E, Domínguez-Perles R, et al: Autosomal-dominant distal myopathy with a myotilin S55F mutation: sorting out the phenotype. *J Neurol Neurosurg Psychiatry* 2008;79:205–208.
- 17 Olive M, Goldfarb LG, Shatunov A, et al: Myotilinopathy: refining the clinical and myopathical phenotype. *Brain* 2005;128:2315–2326.
- 18 Penisson-Besnier I, Talvinen K, Dumez C, et al: Myotilinopathy in a family with late-onset myopathy. *Neuromuscul Dis* 2006;16:427–431.
- 19 Foroud T, Pankratz N, Batchman AP, et al: A mutation in myotilin causes spheroid body myopathy. *Neurology* 2005;65:1936–1940.
- 20 Mercuri E, Pichiecchio A, Allsop J, et al: Muscle MRI in inherited neuromuscular disorders: past, present and future. *J Magn Res Imaging* 2007;25:433–440.
- 21 Ahlberg G, Jakobsson F, Fransson A, et al: Distribution of muscle degeneration in Wexler distal myopathy – a magnetic resonance imaging and muscle biopsy study. *Neuromuscul Disord* 1994;4:55–62.
- 22 Hauser MA, Horrigan SK, Salmikangas P, et al: Myotilin is mutated in limb girdle muscular dystrophy 1A. *Hum Mol Genet* 2000;9:2141–2147.
- 23 Birchall D, von der Hagen M, Bates D, et al: Subclinical semitendinosus and obturator externus involvement defines an autosomal dominant myopathy with early respiratory failure. *Neuromuscul Disord* 2005;15:595–600.
- 24 Griggs R, Vihola A, Hackman P, et al: Zaspopathy in a large classic late-onset distal myopathy family. *Brain* 2007;130:1453–1455.