

# Minimally Invasive Surgery for the Treatment of Colorectal Cancer

W. Konrad Karcz<sup>a</sup> William von Braun<sup>b</sup>

<sup>a</sup>Department of General, Visceral, and Transplant Surgery, Ludwig Maximilian University, Munich, Germany;

<sup>b</sup>Department of Abdominal Surgery, Metro North Hospital and Health Service, Brisbane, Australia

## Keywords

Colon surgery · Oncological laparoscopic surgery ·  
Single incision · Robotically assisted surgery ·  
Transanal surgery

## Summary

**Background:** Reduction in operative trauma along with an improvement in endoscopic access has undoubtedly occupied surgical minds for at least the past 3 decades. It is not at all surprising that minimally invasive colon surgery has come a long way since the first laparoscopic appendectomy by Semm in 1981. It is common knowledge that the recent developments in video and robotic technologies have significantly furthered advancements in laparoscopic and minimally invasive surgery. This has led to the overall acceptance of the treatment of benign colorectal pathology via the endoscopic route. Malignant disease, however, is still primarily treated by conventional approaches. **Methods and Results:** This review article is based on a literature search pertaining to advances in minimally invasive colorectal surgery for the treatment of malignant pathology, as well as on personal experience in the field over the same period of time. Our search was limited to level I and II clinical papers only, according to the evidence-based medicine guidelines. We attempted to present our unbiased view on the subject relying only on the evidence available. **Conclusion:** Focusing on advances in colorectal minimally invasive surgery, it has to be stated that there are still a number of unanswered questions regarding the surgical management of malignant diseases with this approach. These questions do not only relate to the area of boundaries set for the use of minimally invasive techniques in this field but also to the exact modality best suited to the treatment of every particular case whilst maintaining state-of-the-art oncological principles.

© 2016 S. Karger GmbH, Freiburg

## Laparoscopic Surgery: Background

The main aim of minimally invasive surgery is to reduce intra-operative injury. This goal has occupied many surgeons, physicians, and scientists for over 100 years. As such, the history of laparoscopic surgery started in Dresden in 1901 when Kelling performed the first procedure of this kind. 8 years later, the internist Jacobsen published his first endoscopic diagnostics in the thorax and later on a human abdomen, and so keyhole surgery was born [1].

A quantum leap towards this goal occurred when the television started to be used for indirect observation. In 1972, Clarke patented, recorded, and published the first film of laparoscopic surgery [2], and the first laparoscopic appendectomy was performed by Semm at the University of Kiel in 1981 [3]. Over the years, the instruments needed for laparoscopy got better, smaller, and easier to use. With the development of staplers, laparoscopic surgery evolved even further, improving its quality and diversity.

Over the past few decades, laparoscopic surgery has gone through various evolutionary stages, which were certainly in line with the general industrial progress. At first, the hand- and laparoscopically assisted interventions were carried out. Later on, these methods evolved into totally intracorporeal techniques. As a next step forward, port quantity was further reduced, giving rise to single-port surgery. Recently, with the invention of mini-laparoscopy, a reduction in port sizes to 2 mm has been attempted. Due to these changes, the surgical armamentarium of many different laparoscopic techniques has now evolved to comprise many different modalities, such as hand-assisted laparoscopic surgery (HALS), laparoscopically assisted techniques, totally intracorporeal laparoscopic surgery (TILS), single-incision laparoscopic surgery (SILS), flexible laparoscopy (FLS), and robotically assisted laparoscopic surgery (RALS) [4].

Robotically assisted surgery was introduced, amongst other techniques, to increase the precision and quality of the performed operations, evolving from simple camera maneuvering to very

complex movements, which could not be carried out by means of traditional laparoscopy. The development is still a working progress, which is evident by the appearance of new devices combining flexible endoscopy and laparoscopy, i.e. 'ANUBIS', 'Endo-Samurai', 'Notes/R', DDES, and 'Spider' [5–7]. This signaled the beginning of natural orifice transluminal endoscopic surgery (NOTES). It is worthwhile pointing out that, without adding computer stabilization and robotic assistance, all of these techniques would have achieved the end point in their development. It can also be said that natural orifice surgery procedures are capable of reducing postoperative pain and improving cosmetic results even further, as opposed to the other minimally invasive techniques [8].

Consequently, laparoscopic surgery is directly combined with the progress in video technology, whereby a better view had directly influenced the operation outcomes. The quality of view was initially radically improved through the introduction of high-definition television (HDTV – 1990) and then due to three-dimensional views and ultra-high definition (4K (four times HD)/8K/16K high dynamic range). Today, it is possible to get even higher resolution with the nano-pixel technology [9].

An even further enhancement of our perception could be achieved through certain artificial modalities. Optical-based techniques, for instance, can identify tumors in the surrounding tissue through specific optical properties, light absorption, and scattering, which are primarily influenced by biochemical and morphological tissue composition. Breaking down optical spectroscopy, several further techniques can be distinguished, such as diffuse reflectance spectroscopy and fluorescence spectroscopy. These techniques enable tissue characterization by measuring the spectral response after the tissue is illuminated with a particular spectral band of light. Growing neoplasm has different properties than the tissue it is derived from. Its metabolism and cell composition allow differentiating them from healthy tissue by using specific waves of light [10]. The method has been implemented in the endoscopic diagnostic of colorectal cancer, allowing easier identification of potential neoplasms, with sensitivity and specificity ranging from 75 to 90% [11, 12]. A natural expansion of this technique is the current attempt to implement the spectroscopy method into the operating theater. Preliminary data showed promising results [13]. This technique will allow better identification of cancer-free margins in order to reduce its local recurrence. There are more methods available that help distinguishing various tissues, e.g. photodynamic diagnostic, photosensitizer therapy, and use of laser light. The photodynamic therapy is a non-thermal approach, which can be used to produce localized tissue necrosis. It requires the systemic or topical administration of a photosensitizing agent, which is activated in situ by light of a specific wavelength to form reactive oxygen isotopes in the presence of molecular oxygen. The deployable agent used can represent any substance that reacts with a specific light length, although the most commonly used agent is 5-aminolevulinic acid. Currently, all trials are at animal stage but the preliminary results are promising [14]. The progress and diagnostic possibilities, also with genotyping, will lead to an early-stage diagnostic and possibly to an increase of flexible endoscopic therapeutic

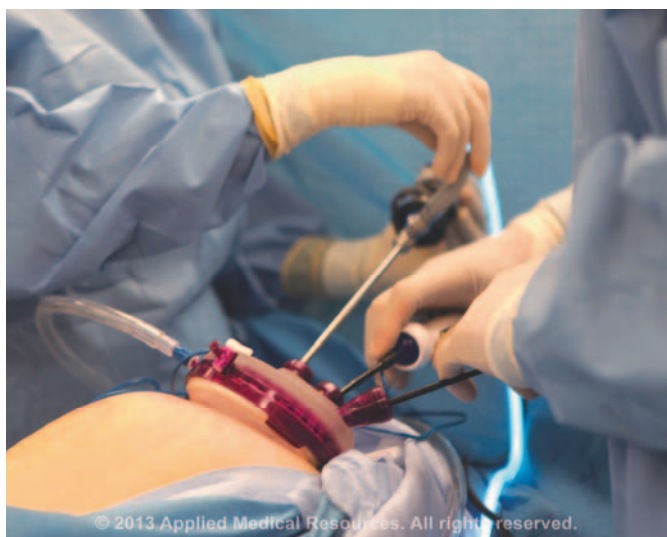options. Imaging technologies are also further developing and will probably be combined with videosurgery in the near future [15].

The majority of doctors do accept the superiority of minimally invasive techniques for the management of benign conditions. Colorectal surgery is no exception to this rule. The subject of laparoscopic techniques in colorectal surgery raised a totally different question, which has been under discussion for many years. For example, the sigmoid colectomy is the most frequently performed laparoscopic colorectal procedure and is already very well accepted by patients. Traditional open surgery is thus primarily reserved for very difficult cases. The limitations of laparoscopic colorectal surgery are first and foremost related to its adequacy for oncological indications. In 2002, Lacy et al. [16] compared the treatment of colorectal cancer by using conventional and laparoscopic techniques. Today, 5-year follow-up results are available; however, the question still remains open [17]. The recently published study by Keller et al. [18], which analyzed a 1-year prospective national inpatient database of two patient groups who underwent colon surgery by means of conventional laparotomy versus laparoscopy, presented a good example of the realities associated with the usage of laparoscopic techniques. The analysis of 6,343 patients led to the conclusion that the laparoscopic approach was more cost-effective and had better outcomes than open surgery. The authors concluded that minimally invasive surgery is a standard that should be offered to all patients [18]. It has been shown that laparoscopy significantly improves postoperative recovery and patient satisfaction, shortens length of stay, and reduces complication and readmission rates, with similar results compared to open surgery for benign and malignant colorectal neoplasms [17, 19–23]. It has to be said that the data presented by Keller et al. [18] showed that about 50% of all patients in the USA were operated using the laparoscopic approach, whereas in England, this figure was only 20% in 2010. In Germany, there is a role for laparoscopic surgery in managing benign and malignant diseases of the colon and rectum [18, 24]. 29 years after the foundation of laparoscopic surgery, we still have questions regarding the boundaries for oncological application of these techniques. Some interesting results were published by the well-designed ACOSOG-Z6051 trial (35 surgical institutions) where the non-inferiority thesis of laparoscopy in comparison to open surgery was supported according to pathological outcomes. Nonetheless, it was concluded that in order to achieve better oncological clinical outcomes, more advanced neoplasms and cancer stages should be treated by means of open surgery [25]. Established laparoscopic oncological colon surgery has to be compared with its further developments such as SILS and RALS to recognize its advantages and restrictions.

### **Advanced Clinically Approved Laparoscopic Techniques**

#### *Single-Incision Laparoscopic Surgery*

The reduction of the number of access ports as opposed to conventional laparoscopy (CL) led to the development of single-port



**Fig. 1.** Applied Medical gel port for single-incision laparoscopic surgery (courtesy of Applied Medical Resources®).

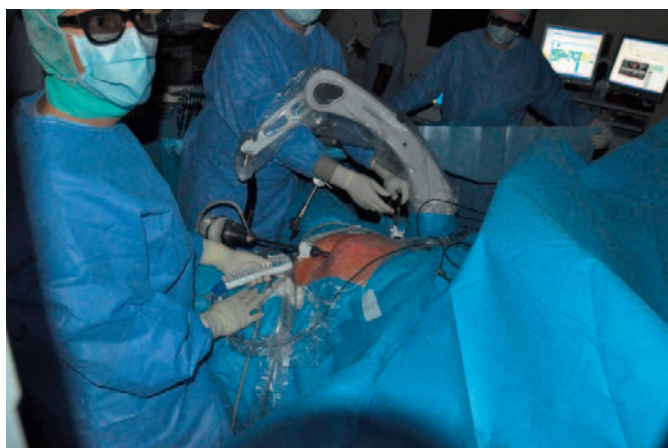
laparoscopic surgery. It was pioneered by Pelosi who first reported on SILS hysterectomy in 1992 [26]. The first colorectal operations which were carried out using this technique were the treatment of appendicitis [27] and sigmoid diverticulitis [4]. In today's practice, those techniques continue to expand but still have limitations. By direct comparison to multi-port laparoscopy, the following disadvantages have to be pointed out: lack of triangulation; different, sometimes uncomfortable position for the surgeon; no ergonomic position for the assistant; restricted number of working instruments; restricted external working space; need for additional special equipment, which in turn extends operating time and prolongs the learning curve [28] (fig. 1). New operative instruments were necessary to improve this technique, e.g. long scope with 5-mm diameter, curved laparoscopic instruments, articulated instruments etc. The variety of equipment available on the market for single-port technique rapidly increased in 2012 [29, 30]. Today, both techniques, i.e. CL and SILS, are also successfully used in oncological colon surgery. It has to be noted that since its development, SILS showed only moderate growing dynamics. The complexity of oncological techniques resulted in minimally invasive operations being special and very difficult. There are only few higher evidence-based publications which directly compare the SILS and CL procedures, and some of them were pre-planned studies. In the SILVERMAN1 trial, Winter et al. [31] proposed a prospective, well-structured trial to observe the differences in SILS and CL procedures for hemicolectomy for colonic cancer. Overall, it seemed that the SILS technique could be used to perform right hemicolectomy with quite good comparable results from 300 patients expected by the end of 2016 [31]. In 2010, Ramos-Valadez et al. [32] had already published a study with positive conclusions for SILS for the right colon surgery. Unfortunately, his observation cohort had only 11 patients [32]. In 2011, Kim et al. [33] initiated a trial to prospectively compare CL with single-port colon resections. The primary outcome of this trial showed no difference between the

groups, but the technical difficulties with SILS were pointed out [33]. Furthermore, an interesting prospective randomized trial was recently published by Wang et al. [34]; here, early morbidity was used as an end point. In this paper, technical difficulties such as limitations relating to the instrument movement, loss of triangulation, difficulties with rectal transection, and intracorporeal double-stapling of anastomoses were also pointed out. Additionally, the need to use an additional 12-mm trocar in the SILS technique was regarded as problematic [34]. In contrast, Marks et al. [35], in his retrospective study, presented slightly better results for SILS procedures in respect to operative time, incision, and blood loss. Lee et al. [36] published different results for the left hemicolectomy operative time, where SILS operations lasted longer in comparison with HALS and classical multi-port technique. The use of independent parameters like inflammatory response as well as immune response, as proposed by Wang et al. [34], could enable a completely new, independent angle for comparing the laparoscopic operation techniques. Some studies showed that the oncological safety of SILS has not been completely proven. Local recurrence rate or distant metastasis may still pose an issue. There are studies showing oncological safety with SILS; however, this has to be better evaluated through higher evidence-based studies with longer observation time, i.e. disease-free survival or 5-year survival [34, 37]. Nevertheless, the early results are promising for SILS. In contrast, Chew et al. [38] reported no difference between SILS and CL for right hemicolectomy procedures according to lymph node count in the resected specimen.

Rectal cancer is even more challenging, particularly technically, when compared to colon SILS procedures, especially when the distance between the umbilicus and the sacrum or spleen is larger or when the patients' body mass index (BMI) is higher. These considerations have undoubtedly influenced the pre-selection processes [39]. Amongst other aspects, single-incision TME techniques need to counter the tension of the new instruments, which poses further limitations [40]. It is worth mentioning that single-port techniques were mostly used for segmental colon resections and achieved the lowest rates of complications compared to CL and RALS [6, 36, 41]. However, meta-analyses have pointed out that the patients' BMI was very low in the SILS group when compared to the normal population [42]. Cianchi et al. [30] explained that the results after SILS surgery are strongly correlated with the level of surgical skills when approaching the technique (which needed to be high), pre-selection of patients with smaller tumors, lower BMI, and right-sided pathology. Nevertheless, SILS procedures are still not widely adopted in colorectal surgery due to the fact that they are associated with technical challenges, i.e. not an ergonomic position for the operator, higher procedural skills of the operator, and most certainly higher costs [43, 44].

#### *Robotically Assisted Laparoscopic Surgery*

It is not surprising that the history of medical robots overlaps with laparoscopy, although robots did appear a few years prior to laparoscopy, namely with the 'Puma 560' used for neurosurgical biopsy in 1985. Several years later, this led to the development of



**Fig. 2.** Clinical approach: robotically supported 3D laparoscopic surgery at the University of Freiburg, Germany.

the ‘Probot’ for transurethral resection of the prostate. Simultaneously, the ‘Robodoc’ was created by IBM’s Thomas J. Watson Research Center for total hip arthroplasty. There were also some NASA projects in the 1980s which focused on developing telesurgery and further accelerated the development of the robots used in surgery. The situation was also strongly influenced by the US Army projects with Mobile Advanced Surgical Hospitals (MASH) where wounded soldiers could be loaded into a vehicle with robotic equipment and be operated by a surgeon of MASH.

First commercial voice-controlled endoscopic cameras were developed by Computer Motion Inc. and were called AESOP (Automated Endoscopic System for Optimal Positioning); later, they were followed by ZEUS (fig. 2). AESOP development led to the ‘da Vinci’ system, which is the most popular RALS platform in the world nowadays. Progress in using robotic surgery was influenced even more by the extension and improvement of laparoscopic operative techniques. Germany also contributed to the history of employing robotic surgery after F.-W. Mohr had successfully carried out the first robotically assisted heart bypass in Leipzig in 1998. In 2008, the German Aerospace Center (DLR) presented the first robotic system for minimally invasive surgery [45–59] (fig. 3). In 2011, there were already 1,400 operating rooms equipped with ‘da Vinci’ systems in the USA. The higher costs slowed down the development of this technique in the Eurozone due to the limitations of the social insurance systems, and Germany was not an exception to this rule, thus resulting in only 52 working RALS systems in 2011 [50]. It is needless to say that colorectal surgery could also be performed via laparoscopy with robotic assistance [6]. However, we will analyze the scientific literature to form an independent view on this topic. It could be said that because of the disproportional operational costs, the fast development of RALS in the USA had a background of a combination of both excellent marketing performance and patients’ needs for modern technology. The meta-analysis by Tewari et al. [51] on 286,876 prostatectomies showed that oncological margins were comparable yet suggested that the adverse events decreased when using robotically assisted procedures. Furthermore, the lower



**Fig. 3.** DLR MiroSurge System for robotically assisted laparoscopic surgery (courtesy of Mr. Holger Urbanek, Institut für Robotik und Mechatronik, Deutsches Zentrum für Luft- und Raumfahrt).

readmission, reoperation, and total perioperative complication rates supported a lower morbidity with RALS. Although these studies were very good, it has to be noticed that duration of a robotic procedure, preparation time for surgery, learning curve, and costs were not analyzed [51]. Currently, we do not have large numbers of RALS techniques used in colorectal surgery. A very interesting comparison was published by Keller et al. [52], focusing on CL, SILS, and RALS procedures in colorectal surgery. The study had several restrictions, e.g. analysis of non-homogeneous groups, time of publication, small patient cohorts etc. However, the technical trends of the operations were suitable for evaluation. Firstly, in comparison to first publications about 20 years ago, CL has improved the outcomes, and secondly, because of technical restrictions, RALS was mainly used for rectal cancer [53]. The advantages of RALS were: comfortable position for the surgeons, reduction of physiological tremors, physiological position of hands, structure view enlargement, almost unrestricted motion of instruments, superior dexterity, permanent 3D view, etc. [54, 55]. Where limitations of movement (e.g. narrow spaces) exist, the advantages of robotically assisted surgery are obvious. Comparing traditional laparoscopic instruments with the possibilities of robotic instruments, i.e. rotation (up to 540°), flexion (180°) clearly emphasizes the limitations of CL [56]. Having said that, the robotic systems also had limitations which were associated with its usage in a wider operative field, such as in cases of rectal surgery, involving its mobilization with the need to mobilize the left colonic flexure during the same procedure [54]. Such changes in operative quadrants when using RALS are associated with re-docking of the system, trocar repositioning, or additional trocar placement. This consequently led to the development of hybrid techniques, where a part of the operation is carried out by means of standard laparoscopy, with consequent time prolongation or use of an additional surgeon for the robotically assisted part of the procedure [55, 57]. In contrast, many authors reported no difference in outcome between hybrid and solitary RALS [58–60]. Keller et al. [61] analyzed the operative time of robotically assisted procedures, which was longer in the same series.

Moreover, the complication and readmission rates were higher than in multi- or single-port surgery. It has to be critically pointed out that the preoperative robotic system preparation time was always significantly longer, thereby prolonging the use of the operating theater [62]. The same observation was reported by Patel et al. [63] upon comparing RALS, CL, and HALS, with similar short clinical results in all groups. The mortality rate was analyzed by Keller et al. [52]; no differences were found and the study concluded that CL, RALS, and SILS enable high-quality colorectal surgery [52]. To evaluate the conversion rate, which is an excellent laparoscopic quality characteristic, more than 60 different studies on RALS and CL were analyzed, showing average conversion rates to open surgery of 2.4 and 0.7%, respectively [62]. In oncological colon surgery, however, the prognosis and outcome for the use of robotically assisted procedures are yet to be evidence base evaluated. The very frequent usage of RALS in the pelvis could be the reason for the results presented by Baik et al. [64], where better prognosis and oncologic outcomes were concluded. There are also studies where the amount of blood loss after colon surgery by robotically assisted procedures seemed to decline [65, 66]. It is too early to talk about the disease-free survival rates but small published series showed similar outcomes to CL [67, 68]. It is certain that total mesorectal excision (TME) resection could create an interesting further chapter of robotically assisted approaches due to a small operative field and closely placed anatomical structures. The first publication on the use of robots in oncological cases was written by Pigazzi et al. [69] in 2006. The meta-analysis by Araujo et al. [56] presented 32 studies with 1,776 patients who underwent robotically assisted procedures on the rectum. Generally, the postoperative complication rate was comparable in most of the evaluated studies. Only in one well designed cohort by Baik et al. [70], the reduction of complications was significantly smaller for RALS [56]. The oncological assessments demonstrated similar results in achieving adequate circumferential resection margin, lymph node count, distal resection margin, etc. [58]. The ROLLAR (RObotic Versus LAParoscopic Resection for Rectal Cancer) trial presented at the international congress of the European Association for Endoscopic Surgery (EAES) in 2015 showed no better outcomes for robotic surgery [71]. However, it is already proven that robotic surgery is safe and comparable with conventional or laparoscopic surgery. Nonetheless, if costs for RALS surgery were optimized and the technology was better taught and widely accepted, then robotic surgery would be able to decrease the percentage of laparoscopic operations and would have a fixed place in oncological colon surgery, especially in difficult cases with narrow, small operative fields and, naturally, in cases involving sophisticated surgical reconstructions.

#### *Endoscopic Local Tumor Resections*

By definition, the term NOTES in colorectal surgery involves endoscopic resections of local colorectal tumors. The technique has been used for several years and resulted in many different modifications. The first endoscopic method for local tumor management was transanal endoscopic microsurgery (TEM), which was developed by Buess in 1983 [72]. Since then it has gradually

gained acceptance and replaced the standard transanal excision due to its benefits of quick learning curve and better augmentation of the excised area. In a meta-analysis, Clancy et al. [73] proved better oncological results when using TEM instead of standard excision. TEM is consequently an established approach, which offers a stable operating platform with magnified stereoscopic view, thus allowing precise full-thickness excision of the rectal wall as far as 15–20 cm from the anal verge. TEM for rectal cancer could remove the primary tumor but, unlike TME, is not able to remove the mesorectal lymph nodes. Thus, it is important to determine the presence of metastases in lymph nodes prior to surgery. The novel method that is currently being developed and which still needs to be proven as safe and efficient is transanal minimally invasive surgery (TAMIS) [74]. Its preliminary results are promising but require more research. With the development of new and more sophisticated equipment, endoscopic resections have been combined with other surgical techniques to create more applicable and safer methods. Transanal TME (taTME) is the combination of the three established rectal surgery techniques, i.e. TME [75], transanal transabdominal resection/intersphincteric resection [76], and TEM, inspired by the recent concept of NOTES and the TAMIS procedure [77, 78].

A taTME has the potential benefit of better visual control of hard-to-access anatomical areas which would be impossible to reach by means of standard laparoscopic approaches, especially in male patients with a high BMI and low rectal cancer, thus resulting in open surgery. Better magnification may lead to even easier nerve preservation and better identification of the resection plane [79]. A taTME is a new approach of performing minimally invasive rectal resection; it attracts a lot of attention in the literature but still requires a lot of research to determine its full usefulness and safety for future patients.

## **Conclusion**

The topic of trauma reduction without much change to the organ-specific procedures and improvement of surgical access still occupies our minds. Hence, experienced minimally invasive surgeons currently use very sophisticated equipment to further improve the already good quality of surgical colon procedures and take them to yet another level. In the future, minimally invasive surgery will further reduce the organ-dependent approach and will represent only a part of interdisciplinary therapy. The development of tailored individualized oncological approaches and diagnostic techniques will most likely reduce the range of available surgical interventions. Further development of endoscopic surgical equipment will improve the safety and quality of minimally invasive videosurgery.

## **Disclosure Statement**

The authors declare that they have no conflicts of interest in respect to this research.

## References

- Hatzinger M, Kwon ST, Langbein S, Kamp S, Häcker A, Alken P: Hans Christian Jacobaeus: inventor of human laparoscopy and thoracoscopy. *J Endourol* 2006;20:848–850.
- Clarke HC: Laparoscopy – new instruments for suturing and ligation. *Fertil Steril* 1972;23:274–277.
- Semm K: Endoscopic appendectomy. *Endoscopy* 1983;15:59–64.
- Turley RS, Mantyh CR, Migaly J: Minimally invasive surgery for diverticulitis. *Tech Coloproctol* 2013;17 (suppl 1):S11–S22.
- Giannotti D, Casella G, Patrizi G, et al: Spider surgical system versus multiport laparoscopic surgery: performance comparison on a surgical simulator. *BMC Surgery* 2015;15:54.
- Dallemagne B, Marescaux J: The ANUBIS™ project. *Minim Invasive Ther Allied Technol* 2010;19:257–261.
- Shaikh SN, Thompson CC: Natural orifice transluminal surgery: flexible platform review. *World J Gastrointest Surg* 2010;2:210–216.
- Gumbs AA, Fowler D, Milone L, Evanko JC, Ude AO, Stevens P, Bessler M: Transvaginal natural orifice transluminal endoscopic surgery cholecystectomy: early evolution of the technique. *Ann Surg* 2009;249:908–912.
- Koller P: Nanopixel bringen Display-Auflösung in eine neue Dimension. *Elektronikpraxis*, 11.07.2014. [www.elektronikpraxis.vogel.de/hmi/articles/452195](http://www.elektronikpraxis.vogel.de/hmi/articles/452195).
- Wang HW, Jiang JK, Lin CH, et al: Diffuse reflectance spectroscopy detects increased hemoglobin concentration and decreased oxygenation during colon carcinogenesis from normal to malignant tumors. *Opt Express* 2009;17:2805–2817.
- Dhar A, Johnson KS, Novelli MR, et al: Elastic scattering spectroscopy for the diagnosis of colonic lesions: initial results of a novel optical biopsy technique. *Gastrointest Endosc* 2006;63:257–261.
- Nallala J, Gobinet C, Diebold MD, et al: Infrared spectral imaging as a novel approach for histopathological recognition in colon cancer diagnosis. *J Biomed Opt* 2012;17:116013.
- Langhout GC, Spliethoff JW, Schmitz SJ, et al: Differentiation of healthy and malignant tissue in colon cancer patients using optical spectroscopy: a tool for image-guided surgery. *Lasers Surg Med* 2015;47:559–565.
- Agostinis P, Berg K, Cengel KA, et al: Photodynamic therapy of cancer: an update *CA Cancer J Clin* 2011;61:250–281.
- Weissleder R, Pittet MJ: Imaging in the era of molecular oncology. *Nature* 2008;452:580–589.
- Lacy AM, García-Valdecasas JC, Delgado S, Castells A, Taurá P, Piqué JM, Visa J: Laparoscopy-assisted colectomy versus open colectomy for treatment of non-metastatic colon cancer: a randomised trial. *Lancet* 2002;359:2224–2229.
- Jayne DG, Thorpe HC, Copeland J, Quirke P, Brown JM, Guillaou PJ: Five-year follow-up of the Medical Research Council CLASICC trial of laparoscopically assisted versus open surgery for colorectal cancer. *Br J Surg* 2010;97:1638–1645.
- Keller DS, Delaney CP, Hashemi L, Haas EM: A national evaluation of clinical and economic outcomes in open versus laparoscopic colorectal surgery *J Med Econ* 2016;19:91–100.
- Nelson H, Sargent DJ, Wieand HS, et al: Clinical Outcomes of Surgical Therapy Study Group: A comparison of laparoscopically assisted and open colectomy for colon cancer. *N Engl J Med* 2004;350:2050–2059.
- Bonjer HJ, Hop WC, Nelson H, et al: Laparoscopically assisted vs open colectomy for colon cancer: a meta-analysis. *Arch Surg* 2007;142:298–303.
- Schwenk W, Haase O, Neudecker JJ, Müller JM: Short term benefits for laparoscopic colorectal resection. *Cochrane Database Syst Rev* 2005;3:CD003145.
- Green BL, Marshall HC, Collinson F, et al: Long-term follow-up of the Medical Research Council CLASICC trial of conventional versus laparoscopically assisted resection in colorectal cancer. *Br J Surg* 2013;100:75–82.
- Van der Pas MH, Haglind E, Cuesta MA, et al: Laparoscopic versus open surgery for rectal cancer (COLOR II): short-term outcomes of a randomised, phase 3 trial. *Lancet Oncol* 2013;14:210–218.
- National Institute for Health and Clinical Excellence (NICE): NICE implementation uptake report: laparoscopic surgery for colorectal cancer. NICE Technology Appraisal 105. 2010.
- Fleshman J, Branda M, Sargent DJ, et al: Effect of laparoscopic-assisted resection vs open resection of stage II or III rectal cancer on pathologic outcomes: the ACO-SOG Z6051 randomized clinical trial. *JAMA* 2015;314:1346–1355.
- Pelosi MA, Pelosi MA 3rd: Laparoscopic supracervical hysterectomy using a single-umbilical puncture (mini-laparoscopy). *J Reprod Med* 1992;37:777–784.
- Kim HJ, Lee JI, Lee YS, Lee IK, Park JH, Lee SK, Kang WK, Cho HM, You YK, Oh ST: Single-port transumbilical laparoscopic appendectomy: 43 consecutive cases. *Surg Endosc* 2010;24:2765–2769.
- Cianchi F, Staderini F, Badii B: Single-incision laparoscopic colorectal surgery for cancer: state of art. *World J Gastroenterol* 2014;20:6073–6080.
- Uematsu D, Akiyama G, Matsuura M, Hotta K: Single-access laparoscopic colectomy with a novel multiport device in sigmoid colectomy for colon cancer. *Dis Colon Rectum* 2010;53:496–501.
- Makino T, Milsom JW, Lee SW: Feasibility and safety of single-incision laparoscopic colectomy: a systematic review. *Ann Surg* 2012;255:667–676.
- The 'SILVERMAN' Trial Single Incision Laparoscopic Versus Existing Resection (Minimal Access) for Neoplasia (SILVERMAN 1). <https://clinicaltrials.gov/ct2/show/NCT01319890?term=single+incision+laparoscopic&rank=6&show=xprt=Y>.
- Ramos-Valadez DI, Patel CB, Ragupathi M, Bartley Pickron T, Haas EM: Single-incision laparoscopic right hemicolectomy: safety and feasibility in a series of consecutive cases. *Surg Endosc* 2010;24:2613–2616.
- Kim CW, Cho MS, Baek SJ, Hur H, Min BS, Kang J, Baik SH, Lee KY, Kim NK: Oncologic outcomes of single-incision versus conventional laparoscopic anterior resection for sigmoid colon cancer: a propensity-score matching analysis. *Ann Surg Oncol* 2015;22:924–930.
- Wang Y, Liu R, Zhang Z, Xue Q, Yan J, Yu J, Liu H, Zhao L, Mou T, Deng H, Li G: A safety study of transumbilical single incision versus conventional laparoscopic surgery for colorectal cancer: study protocol for a randomized controlled trial. *Trials* 2015;16:539.
- Marks JH, Montenegro GA, Shields MV, Frenkel JL, Marks GJ: Single-port laparoscopic colorectal surgery shows equivalent or better outcomes to standard laparoscopic surgery: results of a 190-patient, 7-criterion case-match study. *Surg Endosc* 2015;29:1492–1499.
- Lee SW, Milsom JW, Nash GM: Single-incision versus multiport laparoscopic right and hand-assisted left colectomy: a case-matched comparison. *Dis Colon Rectum* 2011;54:1355–1361.
- Yun JA, Yun SH, Park YA, et al: Oncologic outcomes of single-incision laparoscopic surgery compared with conventional laparoscopy for colon cancer. *Ann Surg* 2015;DOI: 10.1097/SLA.0000000000001226.
- Chew MH, Chang MH, Tan WS, Wong MT, Tang CL: Conventional laparoscopic versus single-incision laparoscopic right hemicolectomy: a case cohort comparison of short-term outcomes in 144 consecutive cases. *Surg Endosc* 2013;27:471–477.
- Bulut O, Nielsen CB, Jespersen N: Single-port access laparoscopic surgery for rectal cancer: initial experience with 10 cases. *Dis Colon Rectum* 2011;54:803–809.
- Uematsu D, Akiyama G, Narita M, Magishi A: Single-access laparoscopic low anterior resection with vertical suspension of the rectum. *Dis Colon Rectum* 2011;54:632–637.
- Khayat A, Maggiori L, Vicaut E, Ferron M, Panis Y: Does single port improve results of laparoscopic colorectal surgery? A propensity score adjustment analysis. *Surg Endosc* 2015;29:3216–3223.
- Fung AK, Aly EH: Systematic review of single-incision laparoscopic colonic surgery. *Br J Surg* 2012;99:1353–1364.
- Pucher PH, Sodergren MH, Singh P, Darzi A, Parakeva P: Have we learned from lessons of the past? A systematic review of training for single incision laparoscopic surgery. *Surg Endosc* 2013;27:1478–1484.
- Miernik A, Schoenthaler M, Lilienthal K, Frankenschmidt A, Karcz WK, Kuesters S: Pre-bent instruments used in single-port laparoscopic surgery versus conventional laparoscopic surgery: comparative study of performance in a dry lab. *Surg Endosc* 2012;26:1924–1930.
- O'Toole MD, Bouazza-Marouf K, Kerr D, Goo-roochurn M, Vloeberghs M: A methodology for design and appraisal of surgical robotic systems. *Robotica* 2009;28:297–310.
- Gerhardus D: Robot-assisted surgery: the future is here. *J Healthc Manag* 2003;48:242–251.
- Kolata G: Results Unproven, Robotic Surgery Wins Converts. *The New York Times*. 13.02.2010. [www.nytimes.com/2010/02/14/health/14robot.html](http://www.nytimes.com/2010/02/14/health/14robot.html).
- Robodoc: History. [www.robodoc.com/patient\\_about\\_history.html](http://www.robodoc.com/patient_about_history.html).
- All About Robotic Surgery. <http://allaboutroboticsurgery.com/roboticsurgeryhistory.html>.
- Lauerer M: Technik im Operationssaal: Teurer Eingriff mit Dr. Robo. *Der Spiegel*. 01.04.2013. [www.spiegel.de/gesundheit/diagnose/chirurgie/kritik-an-operations-roboter-davinci-wegen-komplikationen-a-890261.html](http://www.spiegel.de/gesundheit/diagnose/chirurgie/kritik-an-operations-roboter-davinci-wegen-komplikationen-a-890261.html).
- Tewari A, Sooriakumaran P, Bloch DA, Seshadri-Kreaden U, Hebert AE, Wiklund P: Positive surgical margin and perioperative complication rates of primary surgical treatments for prostate cancer: a systematic review and meta-analysis comparing retropubic, laparoscopic, and robotic prostatectomy. *Eur Urol* 2012;62:1–15.
- Keller DS, Flores-Gonzalez JR, Ibarra S, Madhoun N, Tahilramani R, Mahmood A, Haas EM: Evaluating quality across minimally invasive platforms in colorectal surgery. Presented at the SAGES 2015 Annual Meeting, April 15–18, 2015, Nashville, Tennessee. *Surg Endosc* 2015;DOI: 10.1007/s00464-015-4479-0.
- Trastulli S, Farinella E, Ciocchi R, et al: Robotic resection compared with laparoscopic rectal resection for cancer: systematic review and meta-analysis of short-term outcome. *Colorectal Dis* 2012;14:e134–e156.
- Mirnezami AH, Mirnezami R, Venkatasubramaniam AK, Chandrakumaran K, Cecil TD, Moran BJ: Robotic colorectal surgery: hype or new hope? A systematic review of robotics in colorectal surgery. *Colorectal Dis* 2010;12:1084–1093.

- 55 Rodriguez RM, Pavon JM, de la Portilla F, Sillero EP, Dussort JM, Padillo J: Robotic-assisted total mesorectal excision with the aid of a single-port device. *Surg Innov* 2013;20:NP3-5.
- 56 Araujo SE, Seid VE, Klajner S: Robotic surgery for rectal cancer: current immediate clinical and oncological outcomes. *World J Gastroenterol* 2014; 20:14359-14370.
- 57 Heemskerk J, de Hoog DE, van Gemert WG, Baeten CG, Greve JW, Bouvy ND: Robot-assisted vs. conventional laparoscopic rectopexy for rectal prolapse: a comparative study on costs and time. *Dis Colon Rectum* 2007;50:1825-1830.
- 58 Soravia C, Schwieger I, Witzig J-A, Wassmer F-A, Vredenne T, Sutter P, Dufour J-P, Racloz Y: Laparoscopic robotic-assisted gastrointestinal surgery: the Geneva experience. *J Robot Surg* 2008;1:291-295.
- 59 de Hoog DE, Heemskerk J, Nieman FH, van Gemert WG, Baeten CG, Bouvy ND: Recurrence and functional results after open versus conventional laparoscopic versus robot-assisted laparoscopic rectopexy for rectal prolapse: a case-control study. *Int J Colorectal Dis* 2009;24:1201-1206.
- 60 Choi GS, Park IJ, Kang BM, Lim KH, Jun SH: A novel approach of robotic-assisted anterior resection with transanal or transvaginal retrieval of the specimen for colorectal cancer. *Surg Endosc* 2009;23:2831-2835.
- 61 Keller DS, Bankwitz B, Nobel T, Delaney CP: Using frailty to predict who will fail early discharge after laparoscopic colorectal surgery with an established recovery pathway. *Dis Colon Rectum* 2014;57:337-342.
- 62 Kim CW, Kim CH, Baik SH: Outcomes of robotic-assisted colorectal surgery compared with laparoscopic and open surgery: a systematic review. *J Gastrointest Surg* 2014;18:816-830.
- 63 Patel CB, Ragupathi M, Ramos-Valadez DI, Haas EM: A three-arm (laparoscopic, hand-assisted, and robotic) matched case analysis of intraoperative and postoperative outcomes in minimally invasive colorectal surgery. *Dis Colon Rectum* 2011;54:144-150.
- 64 Baik SH: Robotic total mesorectal excision for rectal cancer: it may improve survival as well as quality of life. *Surg Endosc* 2008;22:1556.
- 65 Memon S, Heriot AG, Murphy DG, Bressel M, Lynch AC: Robotic versus laparoscopic proctectomy for rectal cancer: a meta-analysis. *Ann Surg Oncol* 2012;19:2095-2101.
- 66 Yang Y, Wang F, Zhang P, Shi C, Zou Y, Qin H, Ma Y: Robot-assisted versus conventional laparoscopic surgery for colorectal disease, focusing on rectal cancer: a meta-analysis. *Ann Surg Oncol* 2012;19:3727-3736.
- 67 Lim DR, Min BS, Kim MS, Alasari S, Kim G, Hur H, Baik SH, Lee KY, Kim NK: Robotic versus laparoscopic anterior resection of sigmoid colon cancer: comparative study of long-term oncologic outcomes. *Surg Endosc* 2013;27:1379-1385.
- 68 Baik SH, Kim NK, Lim DR, Hur H, Min BS, Lee KY: Oncologic outcomes and perioperative clinicopathologic results after robot-assisted tumor-specific mesorectal excision for rectal cancer. *Ann Surg Oncol* 2013; 20:2625-2632.
- 69 Pigazzi A, Ellenhorn JD, Ballantyne GH, Paz IB: Robotic-assisted laparoscopic low anterior resection with total mesorectal excision for rectal cancer. *Surg Endosc* 2006;20:1521-1525.
- 70 Baik SH, Kwon HY, Kim JS, Hur H, Sohn SK, Cho CH, Kim H: Robotic versus laparoscopic low anterior resection of rectal cancer: short-term outcome of a prospective comparative study. *Ann Surg Oncol* 2009;16: 1480-1487.
- 71 European Association for Endoscopic Surgery (EAES) 2015, Bucharest, Romania. [www.eaes-eur.org/home.aspx](http://www.eaes-eur.org/home.aspx).
- 72 Buess G, Theiss R, Hutterer F, et al: Transanal endoscopic surgery of the rectum - testing a new method in animal experiments (Article in German). *Leber Magen Darm* 1983;13:73-77.
- 73 Clancy C, Burke JP, Albert MR, et al: Transanal endoscopic microsurgery versus standard transanal excision for the removal of rectal neoplasms: a systematic review and meta-analysis. *Dis Colon Rectum* 2015;58:254-261.
- 74 Albert MR, Atallah SB, deBeche-Adams TC, et al: Transanal minimally invasive surgery (TAMIS) for local excision of benign neoplasms and early-stage rectal cancer: efficacy and outcomes in the first 50 patients. *Dis Colon Rectum* 2013;56:301-307.
- 75 Heald RJ, Moran BJ, Ryall SD, et al: Rectal cancer: the Basingstoke experience of total mesorectal excision, 1978-1997. *Arch Surg* 1998;133:894-899.
- 76 Marks J, Mizrahi B, Dalane S, et al: Laparoscopic transanal abdominal transanal resection with sphincter preservation for rectal cancer in the distal 3 cm of the rectum after neoadjuvant therapy. *Surg Endosc* 2010; 24:2700-2707.
- 77 ASGE, SAGES: ASGE/SAGES Working Group on Natural Orifice Transluminal Endoscopic Surgery White Paper October 2005. *Gastrointest Endosc* 2006; 63:199-203.
- 78 Whiteford MH, Denk PM, Swanström LL: Feasibility of radical sigmoid colectomy performed as natural orifice transluminal endoscopic surgery (NOTES) using transanal endoscopic microsurgery. *Surg Endosc* 2007; 21:1870-1874.
- 79 Rasulov AO, Mamedli ZZ, Gordeyev SS, et al: Short-term outcomes after transanal and laparoscopic total mesorectal excision for rectal cancer. *Tech Coloproctol* 2016;20:227-234.