

Cohesive Polydensified Matrix[®] hyaluronic acid volumizer injected for cheek augmentation has additional positive effect on nasolabial folds

Gerd Gauglitz¹
Stephanie Steckmeier¹
Julian Pötschke²
Hannah Schwaiger¹

¹Department of Dermatology and Allergy, Ludwig-Maximilian University, Munich, Germany; ²Department of Plastic and Hand Surgery, Klinikum St Georg gGmbH, Leipzig, Germany

Purpose: Cohesive Polydensified Matrix[®] hyaluronic acid (CPM-HA) volumizer has been used successfully for several years to reverse biometric volume loss during facial aging. This observational study explored the additive effect on nasolabial folds when CPM-HA volumizer is injected into the neighboring cheek area.

Patients and methods: In this open-label, prospective, postmarketing noninterventional study, 18 adult patients seeking esthetic enhancement of the lateral cheek hollows and cheekbone area were injected with CPM-HA volumizer integrated with lidocaine (CPM-HA-VL) in the upper or lower cheek area. Safety and performance of CPM-HA-VL up to 12 months after injection with follow-up visits at week 4 and month 3, 6, and 12 were assessed. The primary endpoint was improvement of cheek fullness on the validated Merz Aesthetics Scales. Additionally, changes in nasolabial folds were quantified using a phaseshift rapid in vivo measurement of skin optical three-dimensional (3D) in vivo measurement device.

Results: Patients (94.4% female, median age 52 years, age range 39–69 years) were injected with a mean volume of 2.5±1.1 mL CPM-HA-VL per side. Immediately after injection, mean severity for upper and lower cheek fullness assessed on the validated MAS improved from 2.5±0.6 and 2.8±0.5, respectively, to 1.0±0.0, and remained unchanged through month 12. Improvement in relation to baseline was attested on the Global Aesthetics Improvement Scale for all assessments. Compared with baseline, the following assessments offered a statistical significance in the reduction of wrinkle depth of nasolabial folds (maximum depth reduction by 30.4% at 3 months) according to optical 3D in vivo measurements. Pain during injection was minimal and abated within 30 minutes. Treatment was well tolerated and led to great patient satisfaction.

Conclusion: CPM-HA-VL injected into the upper and lower cheeks led to long-lasting satisfactory cosmetic results in cheek augmentation as well as in reducing depth of nasolabial folds adjacent to the injection site.

Keywords: CPM-HA-VL volumizing filler, facial rejuvenation, esthetic procedure, dermal filler, PRIMOS 3D

Introduction

Alterations in the craniofacial skeleton are a common accompanying effect of the aging process. Changes in the relative dynamics of bone expansion and bone resorption lead to a significant loss of facial bone with age.¹ In consequence of the resulting biometric volume loss, the jaw line becomes less pronounced, the skin in cheeks, under the eyes, and around the nose and mouth yields to gravity and starts sagging. This process is further promoted by the decrease in muscle tone and increasing laxity of ligaments. In addition, wrinkle formation intensifies with the deceleration of collagen

Correspondence: Gerd Gauglitz
LMU München Klinik für Dermatologie und Allergologie, Frauenlobstraße 9 – 11, 80337 Munich, Germany
Tel +49 89 4400 56 001
Fax +49 89 4400 56 002
Email Gerd.Gauglitz@med.uni-muenchen.de

and elastin production.² Prompted by the wish to maintain a youthful appearance, increasingly more individuals seek esthetic correction of this facial aging process by minimally invasive procedures.

In previous decades, facial rejuvenation focused on the treatment of wrinkles alone. However, with growing understanding of the facial aging process in recent years, the primary focus has shifted to the reversion of volume loss. Enhancement of the lateral cheek hollows and cheekbone area recreates midface volume, smoothens nasolabial folds, and restores the youthful V-form of the face.³ Therefore, the current treatment strategies aim at restoring juvenile proportions of the entire face by injection of a soft-tissue filler.

Volume fillers based on hyaluronic acid (HA) have become increasingly popular because of their good performance and favorable safety profile.⁴ Depending on the individual treatment goal and area of application, available HA fillers vary in their clinical characteristics which are determined by particle size, the type of cross-linking agent used, the degree of cross-linking, the percentage of cross-linked HA, the amount of free unlinked HA, and the elastic modulus (G').⁵ For the enhancement of the lateral cheek hollows and cheekbone area, the use of Cohesive Polydensified Matrix[®] (CPM)-HA volumizer is supported by 5 years of clinical experience. Resulting from CPM technology, it is characterized by variable cross-linking densities within the gel – denser areas for the volumizing effect and areas of lesser density for cohesivity of the matrix. This property allows for better integration into soft tissues and prevention of the Tyndall effect.⁶ Furthermore, the CPM-HA-specific plasticity of this filler allows the practitioner to mold and sculpt the product easily into the desired shape after the injection in order to achieve optimal esthetic results. Clinical data have confirmed the safety and efficacy of the CPM-HA volumizer with regard to the respective areas that have been injected.^{7–10}

While concomitant correction of the nasolabial fold has been observed by volumizing the cheek and the lost malar fat pads,¹⁰ there is little information on the extent and duration of the additive effect a dermal filler has on the areas adjacent to the injection site. Therefore, the present observational study further explored the effect on nasolabial folds when a filler is injected into the cheek.

Materials and methods

The study was designed as an open-label, prospective, non-interventional study performed at a single center in Germany. It was conducted from July 2014 to November 2015 in accordance with the Declaration of Helsinki and was reviewed and

approved by the Ethics Committee of the Ludwig-Maximilian University. All patients provided written informed consent before enrollment in the study.

The primary endpoint was improvement of cheek fullness on the validated Merz Aesthetics Scales (MAS). Enhancement of the lateral cheek hollows and cheekbone area by a CPM-HA volumizer with integrated lidocaine (CPM-HA-VL, Belotero[®] Volume Lidocaine; Merz Pharmaceuticals GmbH, Frankfurt, Germany) was expected to lead to a reduction of the depth of nasolabial folds after injection in the cheek area. These changes were objectified and evaluated. Additional secondary endpoints included the assessment of safety and patient satisfaction of CPM-HA-VL up to 12 months postinjection.

A total of 18 adult patients seeking esthetic treatment in the upper or lower cheek area were recruited from the investigator's patient pool. Prior to treatment at the first visit (V1) baseline characteristics were documented, including a severity assessment of the area to be treated using the validated 5-point MAS for upper and lower cheek fullness.¹¹

Furthermore, depth of nasolabial folds was measured using a phaseshift rapid in vivo measurement of skin (PRIMOS) optical three-dimensional (3D) in vivo measurement device (GF Messtechnik GmbH, Teltow, Germany).^{12–16} To observe changes in fold depth, a parallel stripe pattern of light was projected which was afterwards captured by a camera system and plotted in a color-coded height map of the measured surface.¹² At each visit, measurements were performed by the same investigator.

During the first visit, patients were treated in the lower and upper cheek area with CPM-HA-VL according to the investigator's usual practice and patients' needs. The CE-marked dermal filler consists of 26 mg/mL HA from biofermentation origin cross-linked with 1,4-butanediol diglycidyl ether. The volumes to be injected as well as the injection techniques were subject to the investigator's discretion. During and 30 minutes after the injection, pain was assessed on an 11-point visual analog scale (VAS) ranging from "0" (no pain) to "10" (extreme pain). Immediately after the injection and at follow-up visits 4 weeks (V2), 3 (V3), 6 (V4), and 12 months (V5) postinjection the following assessments were conducted: changes in 1) severity of cheek hollowness and 2) depth of nasolabial folds were documented. Performance was assessed using the MAS. The cosmetic result was rated in comparison to baseline using the Global Aesthetics Improvement Scale (GAIS). To verify the comparison, photographs were taken at each visit. Written informed consent was obtained from each patient. The informed consent included the scientific

application and publication of the fully identifiable pictures. Patient satisfaction was assessed on a 6-point Likert scale (very good, good, satisfactory, sufficient, poor, insufficient). Patients also stated whether they would undergo treatment with CPM-HA-VL again. Tolerability was assessed on a 5-point Likert scale (very good, good, satisfactory, sufficient, poor). Reactions at the injection site were documented at each visit.

Statistical methods

The analyses were descriptive based on the observed cases. Continuous variables were summarized by number, mean, SD, median, minimum, and maximum. For quantitative variables, absolute and percent frequencies (N, %) were calculated. Evaluation of parameters measuring the clinical course was performed by intraindividual difference analysis (first vs last examination) using the Wilcoxon signed rank test. Difference was calculated per patient and subsequently averaged. Patients with missing data for one or both variables were not imputed. All tests were two-sided, and significance was declared at the 0.05 level.

Results

A total of 17 females and 1 male were enrolled between July and November 2014. Median age was 52 years (range 39–69). At baseline, mean severity on the MAS for upper and lower cheek fullness was 2.5 ± 0.6 and 2.8 ± 0.5 , respectively. Mean depth of nasolabial folds at baseline was 3.2 ± 1.6 mm (right) and 3.7 ± 2.1 mm (left). There was no statistically significant difference between the left and right side. Therefore, values were pooled for the analysis of the clinical course.

Mean injected volume was 2.5 ± 1.1 mL per side of the face. The fanning technique using a blunt cannula 22G 50 mm provided within the package was applied in most cases (72.2%), while CPM-HA-VL was administered using bolus and fanning technique in 3 patients (16.7%, $n=2$ not reported). No additional anesthetic or cooling was applied. Mean pain during and 30 minutes postinjection was rated 1.5 ± 1.1 (range 0–3) and 0.1 ± 0.4 (range 0–1.5) on the VAS, respectively. Five patients (27.8%) felt no pain at all during the injection. Thirty minutes postinjection, only 2 patients still felt minimal pain (0.5 and 1.5 on the VAS, respectively).

Efficacy

All patients showed significant increase of cheek volume and decreases in wrinkle depth at all postinjection measurements compared with baseline. All patients experienced lasting improvement on the MAS throughout the study period. Mean

severity of the upper and lower cheek on the MAS improved to 1.0 ± 0.0 after treatment and remained unchanged through month 12. Improvement in relation to baseline was attested on the GAIS for all postinjection assessments (Figure 1A). Results on the GAIS were consistent with the photo documentation (Figure 1B, C).

Matching of PRIMOS 3D measurements indicated that the effect on nasolabial folds occurred immediately after the injection. Wrinkle depth of nasolabial folds continued to decrease during the first 3 months postinjection (Figure 2). Months 6 (2.799 ± 2.004 mm) and 12 (3.067 ± 1.713 mm) showed slight increases in wrinkle depth compared with month 3 (2.769 ± 1.849 mm), but the reduction compared with baseline remained significant (Figure 3).

Patient reported outcomes

The clear majority of patients (94.4%) rated their satisfaction with the treatment result as very good immediately after the injection as well as 4 weeks and 3 months postinjection (Figure 4). The rating continued to be favorable (very good or good) during the remaining visits. One patient assessed satisfaction with the result as good immediately and 4 weeks after the injection. With one exception, all patients stated that they would undergo the treatment again.

Safety

The investigator rated the tolerability of the product as good or very good in all patients (Figure 5). Mild transient redness was observed in 1 patient for a brief period immediately after injection. No other adverse events or reactions at the injection site were reported. In total, 13 patients completed the 12-month follow-up visit. Five patients dropped out of the study ($N=1$ at month 3, $N=2$ at month 6, $N=2$ at month 12) due to the time required for the assessments.

Discussion

The study with 18 patients confirmed the good performance and safety of lidocaine containing CPM-HA volumizer for augmentation of the cheeks. Improvement was visible immediately after the injection and lasted up to 12 months. During the entire postinjection period, patients showed a mean improvement of 1.5 points on the MAS when compared with baseline. The positive results achieved in cheek augmentation are in line with previous studies.^{17,18} The long-lasting treatment success in cheek augmentation may be attributed to the high capacity of CPM-HA-VL to resist vertical and dynamic compression which makes CPM-HA-VL ideal for achieving an excellent volumizing effect following deep

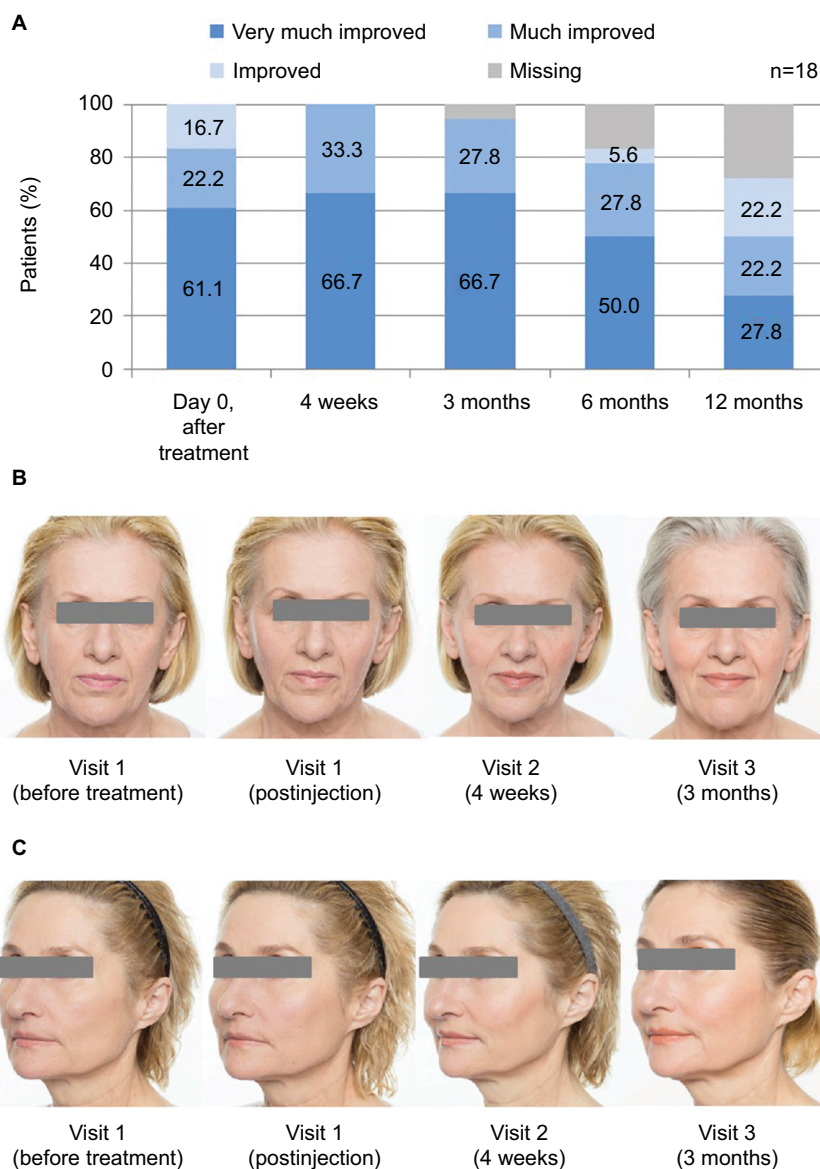


Figure 1 Assessment of the cosmetic result **(A)** on the GAIS and by means of photo documentation of **(B)** a 59-year-old patient and **(C)** a 55-year-old patient. **Abbreviation:** GAIS, Global Aesthetics Improvement Scale.

implantation.¹⁹ Clinical studies and postmarketing clinical observations have shown a lasting effect without touch-up up to 18 months.^{18,20,21} Compared to other dermal fillers, CPM-HA-VL has an intermediate elastic modulus (G') of 300 Pa¹⁹ which leads to greater tissue supporting capacity and consequently better volume efficiency.²² Furthermore, CPM-HA-VL benefits from the high compression parameters E' and F_N , which confer the ability to apply mechanical pressure on fibroblasts in the extracellular matrix, thus stimulating the synthesis of de novo collagen.¹⁹ This recently discovered connection between HA injection and induction of collagen synthesis may contribute to explaining the clinical persistence of the treatment effect which outlasts the bioavailability of the

filler product in the dermis.²³ During the process of optimal tissue integration over the first weeks after implantation, CPM-HA-VL continues to develop, thus achieving a pleasing 3D effect. Furthermore, the filler binds water, leading to an additional volumizing effect not restricted to the treated area, but extending to the adjacent regions as well, such as the nasolabial folds in this study. The good integration into the tissue²⁴ also ensures that the filler material remains at the injection site without caudal migration.

Beyond the beneficial effects observed in cheek augmentation, CPM-HA-VL injected into the upper and lower cheeks also had an impact on the nasolabial folds.²⁵ This result was to be expected because deflation of the midface

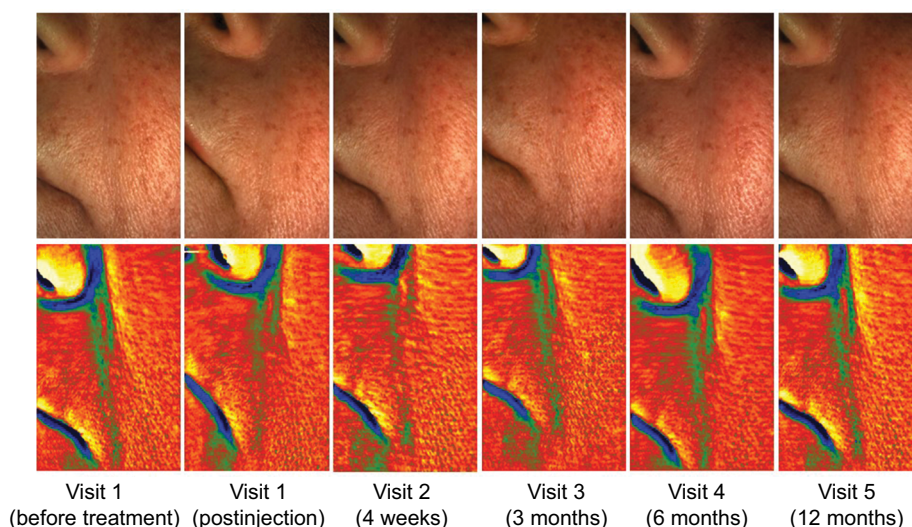


Figure 2 PRIMOS 3D photo documentation and wrinkle depth (derived from the matching mode program of PRIMOS) over the course of the study. Green and blue colors indicate deeper areas.

Abbreviations: PRIMOS, phaseshift rapid in vivo measurement of skin; 3D, three-dimensional.

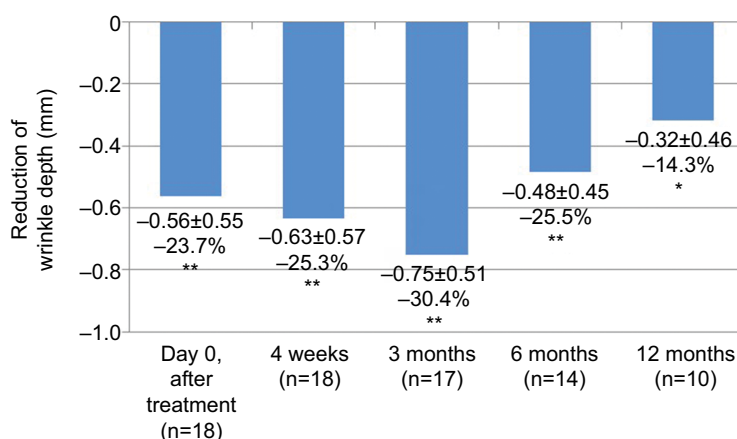


Figure 3 Nasolabial folds: reduction of wrinkle depth. Measurements of the left and right side were pooled. * $p < 0.01$; ** $p < 0.001$.

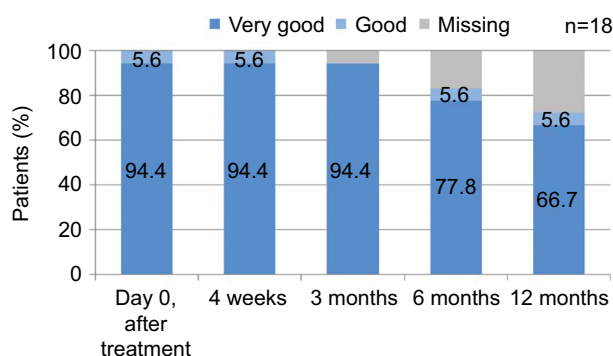


Figure 4 Patient satisfaction rated on a 6-point Likert scale.

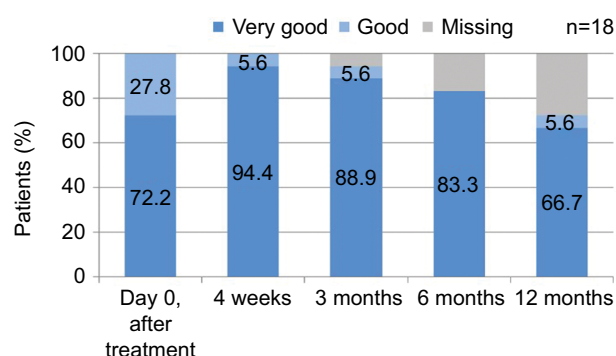


Figure 5 Global tolerability assessment on a 5-point Likert scale.

is the primary cause of nasolabial folds.²² However, to the best of our knowledge, this is the first study that objectively quantified the extent of the effect on a location adjacent to the

injection site. There was a significant long-term reduction in wrinkle depth. The added positive impact on nasolabial folds spares the patient the necessity to undergo further treatment

for this indication, thus reducing treatment costs as well as inconveniences and risks associated with minimally invasive procedures involving injectables. Accordingly, these objective results reflected in the subjective patient assessment: all patients were satisfied with the cosmetic result.

Due to the lidocaine content in the filler product, additional anesthetics were not required. After 30 minutes, pain had abated in almost all patients. Studies have shown that lidocaine integrated into the filler reduced the perception of pain during the injection and correlated with higher patient satisfaction.²⁶ Although injection site reactions such as redness, swelling, and bruising are expected with any type of dermal filler injection,¹⁷ only 1 event of redness was reported. Consistently, most patients in the present study stated their willingness to repeat the procedure.

This study is limited by its noninterventional design and lack of a control group as well as the low number of patients. However, by use of standardized objective assessment measures, such as the PRIMOS optical 3D in vivo measurement, solid data were obtained. The technique has been repeatedly employed in the analysis of subtle wrinkles and other indications such as scars.^{14–16} Lateral solution in the two-digit micrometer range enables high precision imaging which allows the analysis of subtlest irregularities on the skin surface. The use of photo documentation also increased data quality and ruled out recall bias when comparing the cosmetic result with baseline.

From investigations of the aging face, experts have come to the conclusion that changes occur in all tissue structures and that a change in one area may influence changes in neighboring tissues.²⁷ This observation may also be applicable for the reverse process of restoring youthful proportions. Therefore, the additive effect on nasolabial folds observed in this study supports the paradigm shift toward considering all structural changes in the aging face and the interdependency between them instead of focusing treatment on individual lines and folds.

Conclusion

CPM-HA-VL injected into the upper and lower cheeks led to satisfactory cosmetic results in cheek augmentation as well as in reducing depth of nasolabial folds adjacent to the injection site. The effect lasted up to 12 months and was associated with minimal levels of transient injection-related pain, leading to a high degree of patient satisfaction.

Acknowledgments

The authors would like to thank Dr Petra Jöstingmeyer (medunit GmbH, Cologne, Germany) for support in writing

the manuscript and Merz Pharmaceuticals GmbH (Frankfurt,, Germany) for financial writing support.

Author contributions

All authors contributed toward data analysis, drafting and critically revising the paper, gave final approval of the version to be published, and agree to be accountable for all aspects of the work.

Disclosure

GG serves as speaker and advisor for Merz Pharmaceuticals, Galderma, Sinclair Pharma, Lumenis, Candela, Asclepion, Cynosure, Pollogen, Johnson & Johnson, Almiral, Biofrontera, Urgo GmbH, and MediWound. The other authors report no conflicts of interest in this work.

References

- Vleggaar D, Fitzgerald R. Dermatological implications of skeletal aging: a focus on supraperiosteal volumization for perioral rejuvenation. *J Drugs Dermatol*. 2008;7(3):209–220.
- Shaw RB Jr, Katzel EB, Koltz PF, et al. Aging of the facial skeleton: aesthetic implications and rejuvenation strategies. *Plast Reconstr Surg*. 2011;127(1):374–383.
- Carruthers J, Carruthers A, editors. *Soft Tissue Augmentation Procedures in Cosmetic Dermatology Series*. 3rd ed. London: Saunders Elsevier; 2013.
- Cohen JL, Dayan SH, Brandt FS, et al. Systematic review of clinical trials of small- and large-gel-particle hyaluronic acid injectable fillers for aesthetic soft tissue augmentation. *Dermatol Surg*. 2013;39(2):205–231.
- Brandt FS, Cazzaniga A. Hyaluronic acid gel fillers in the management of facial aging. *Clin Interv Aging*. 2008;3(1):153–159.
- Prager W, Steinkraus V. A prospective, rater-blind, randomized comparison of the effectiveness and tolerability of Belotero® Basic versus Restylane® for correction of nasolabial folds. *Eur J Dermatol*. 2010;20(6):748–752.
- Buntrock H, Reuther T, Prager W, Kerscher M. Efficacy, safety, and patient satisfaction of a monophasic cohesive polydensified matrix versus a biphasic nonanimal stabilized hyaluronic acid filler after single injection in nasolabial folds. *Dermatol Surg*. 2013;39(7):1097–1105.
- Micheels P, Ascher B, Beilin G, et al. Évaluation clinique de l'efficacité et l'innocuité d'un acide hyaluronique volumateur de technologie CPM® pour le traitement de multiples zones du visage [Clinical evaluation of the efficacy and safety of a volumizing hyaluronic acid with CPM technology for the treatment of multiple areas of the face]. *Realités Thérapeutiques en Dermato-Vénérologie*. 2014;235:1–8. French.
- Hevia O, Cohen BH, Howell DJ. Safety and efficacy of a cohesive polydensified matrix hyaluronic acid for the correction of infraorbital hollow: an observational study with results at 40 weeks. *J Drugs Dermatol*. 2014;13(9):1030–1036.
- Wollina U. Improvement of tear trough by monophasic hyaluronic acid and calcium hydroxylapatite. *J Clin Aesthet Dermatol*. 2014;7(10):38–43.
- Carruthers J, Flynn TC, Geister TL, et al. Validated assessment scales for the mid face. *Dermatol Surg*. 2012;38(2 Spec No):320–332.
- Bleve M, Capra P, Pavanetto F, Perugini P. Ultrasound and 3D skin imaging: methods to evaluate efficacy of striae distensae treatment. *Dermatol Res Pract*. 2012;2012:673706.
- Perry DM, McGrouther DA, Bayat A. Current tools for noninvasive objective assessment of skin scars. *Plast Reconstr Surg*. 2010;126(3):912–923.

14. Bloemen MC, van Gerven MS, van der Wal MB, Verhaegen PD, Middekoop E. An objective device for measuring surface roughness of skin and scars. *J Am Acad Dermatol*. 2011;64(4):706–715.
15. Gauglitz GG, Bureik D, Dombrowski Y, Pavicic T, Ruzicka T, Schaubert J. Botulinum toxin A for the treatment of keloids. *Skin Pharmacol Physiol*. 2012;25(6):313–318.
16. Poetschke J, Schwaiger H, Steckmeier S, Ruzicka T, Gauglitz GG. Hyaluronsäurehaltige Antifaltencremes: Wie gut wirken sie? [Anti-wrinkle creams with hyaluronic acid: how effective are they?] *MMW Fortschr Med*. 2016;158(Suppl 4):1–6. German.
17. Kühne U, Esmann J, von Heimburg D, Imhof M, Weissenberger P, Sattler G. Safety and performance of cohesive polydensified matrix hyaluronic acid fillers with lidocaine in the clinical setting – an open-label, multicenter study. *Clin Cosmet Investig Dermatol*. 2016;9:373–381.
18. Micheels P, Vandeputte J, Kravtsov M. Treatment of age-related mid-face atrophy by injection of cohesive polydensified matrix hyaluronic acid volumizer. *J Clin Aesthet Dermatol*. 2015;8(3):28–34.
19. Gavard Molliard S, Albert S, Mondon K. Key importance of compression properties in the biophysical characteristics of hyaluronic acid soft-tissue fillers. *J Mech Behav Biomed Mater*. 2016;61:290–298.
20. Prager W, Kerscher M. Analysis of anatomical volume variations in the midface following injection of volumizing hyaluronic acid gels. In: Podium presentation at AMWC Conference; March 31–April 2, 2016; Monaco, France.
21. Kerscher M, Agsten K, Kravtsov M, Prager W. Effectiveness evaluation of two volumizing hyaluronic acid dermal fillers in a controlled, randomized, double-blind, split-face clinical study. *Clin Cosmet Investig Dermatol*. 2017;10:239–247.
22. Sundaram H, Cassuto D. Biophysical characteristics of hyaluronic acid soft-tissue fillers and their relevance to aesthetic applications. *Plast Reconstr Surg*. 2013;132(4 Suppl 2):5S–21S.
23. Landau M, Fagian S. Science of hyaluronic acid beyond filling: fibroblasts and their response to the extracellular matrix. *Plast Reconstr Surg*. 2015;136(5 Suppl):188S–195S.
24. Micheels P, Besse S, Sarazin D, et al. Ultrasound and histologic examination after subcutaneous injection of two volumizing hyaluronic acid fillers: a preliminary study. *Plast Reconstr Surg Glob Open*. 2017;5(2):e1222.
25. Biesman BS, Bowe WP. Effect of midfacial volume augmentation with non animal stabilized hyaluronic acid on the nasolabial fold and global aesthetic appearance. *J Drugs Dermatol*. 2015;14(9):943–947.
26. Smith L, Cockerham K. Hyaluronic acid dermal fillers: can adjunctive lidocaine improve patient satisfaction without decreasing efficacy or duration? *Patient Prefer Adherence*. 2011;5:133–139.
27. Fitzgerald R, Vleggaar D. Facial volume restoration of the aging face with poly-l-lactic acid. *Dermatol Ther*. 2011;24(1):2–27.

Clinical, Cosmetic and Investigational Dermatology

Publish your work in this journal

Clinical, Cosmetic and Investigational Dermatology is an international, peer-reviewed, open access, online journal that focuses on the latest clinical and experimental research in all aspects of skin disease and cosmetic interventions. This journal is included on PubMed. The manuscript management system is completely online

Submit your manuscript here: <https://www.dovepress.com/clinical-cosmetic-and-investigational-dermatology-journal>

Dovepress

and includes a very quick and fair peer-review system, which is all easy to use. Visit <http://www.dovepress.com/testimonials.php> to read real quotes from published authors