



# RHINOLOGY


Vol. 29 - No. 2

June 1991

## CONTENTS

### FREE CONTRIBUTIONS

<i>Hiroshi Moriyama, Masashi Ozawa, Yoshio Honda</i> Endoscopic endonasal sinus surgery. Approaches and post-operative evaluation . . . . .	93
<i>Desmond A. Nunez</i> Presentation of rhinosinugenic intracranial abscesses . . . . .	99
<i>A. Berghaus, S. Jovanovic</i> Technique and indications of extended sublabial rhinotomy ("midfacial degloving") . . . . .	105
<i>G.J. Nolst Trenité</i> Trauma reduction in rhinoplastic surgery . . . . .	111
<i>D. Dokic, S. Jovanovic, A. Berghaus, T. Brunnee</i> Diagnosis of nasal allergy to the house dust mite . . . . .	117
<i>Keiichi Ichimura, Wataru Okita, Toshiyoshi Tanaka</i> Vasoactivity of endothelin in nasal blood vessels . . . . .	125



Contents to be continued next page

*H. Malmberg, E. Holopainen, M. Simola, I. Böss, N. Lindqvist*  
A comparison between intranasal budesonide aerosol and  
budesonide dry powder in the treatment of hay fever symptoms 137

*K. Ichikawa, M. Okuda, F. Naka, H. Yago*  
The sources of chemical substances in allergic nasal fluid . . . 143

## CLINICAL CONTRIBUTION

*Ron Milo, Juana Schiffer, Julio Karpuch, Shlomo Sarfaty,  
Sara Shikar*  
Frontal bone osteomyelitis complicating frontal sinusitis caused  
by *Haemophilus influenzae* type a . . . . . 151

## HISTORICAL CONTRIBUTION

*R.A. Tange*  
Some historical aspects of the surgical treatment of the infected  
maxillary sinus . . . . . 155

BOOKS . . . . . 163

ANNOUNCEMENTS . . . . . 167

*This journal is cited in Index Medicus and Excerpta Medica*

# Technique and indications of extended sublabial rhinotomy (“midfacial degloving”)

A. Berghaus and S. Jovanovic

Dept. of O.R.L., Steglitz Medical Center, Free University Berlin, Germany

## SUMMARY

*Midfacial degloving is an extended sublabial rhinotomy, which permits good bilateral access to the nasal and paranasal cavities, the base of the skull, and the clivus. The incisions leave no visible scars. The access is suitable for large benign tumours (such as nasopharyngeal fibromas or inverted papillomas), but can also be used for malignant tumours. It can be enlarged by supplementary incisions to meet the demands of tumour surgery.*

## INTRODUCTION

Midfacial degloving is an operative technique for sublabial access to the deeper midfacial regions, particularly to the nasal cavities, the paranasal sinuses, the nasopharynx, the retromaxillary space, the base of the skull and the clivus.

The procedure has two main advantages:

1. The incision leaves no externally visible scars.
2. The access nevertheless permits an extensive overview and is bilateral, if necessary.

In the past years, midfacial degloving has been elaborated and propagated primarily by Conley and Price (1979) and Maniglia (1986) in the U.S.A.

## OPERATIVE PROCEDURE

The performance of this sublabial rhinotomy requires four connecting incisions:

1. The transfixion incision that separates the nasal columella from the septum.
2. Bilateral intercartilaginous incisions.
3. A bilateral circumvestibular incision that connects the intercartilaginous with the transfixion incision via the floor of the nose.
4. A bilateral sublabial incision extending beyond the midline.

---

Paper presented at the 13th Congress of the European Rhinologic Society including the IXth I.S.I.A.N., London (United Kingdom), June 1990.

The intercartilaginous incision is followed by separation of the dorsum of the nose and notching of the periosteum at the edge of the piriform aperture. From the vestibule of the mouth, the soft parts of the midface are separated subperiosteally; dissection extends to the edge of the piriform aperture and the incisions already performed intranasally. This permits the upper lip to be lifted together with the tip of the nose. Mobilization of the midfacial soft parts is then continued transnasally and transorally up to the orbital margin or nasofrontal angle. The infraorbital nerve is generally preserved.

After completion of the dissection, the soft parts of the midface with the upper lip, cheeks and nose, including the alar cartilages, can be lifted from the osseous substratum in one piece. The midfacial skeleton with the triangular cartilages and septum then lies fully exposed.

In order to advance into deeper regions, bone resections can now be performed as required. Thus the medial and anterior maxillary sinus wall can be removed through a cranial and caudal osteotomy of the piriform aperture ("medial maxillectomy"). This provides a wide access to the septum as well as to the ethmoid and sphenoid bone. The retromaxillary space is reached by temporary resection of a lateral bone segment including the anterior and laterodorsal maxillary sinus walls with the zygomatic insertion, as shown by Berghaus (1990).

The accessible region is bordered laterally by the coronoid processes of the mandibles and dorsally by the carotids passing through the sphenoidal sinus. The lower border is generally the palate. However, a resection of the palate, an inferior maxillectomy and even a total maxillary resection with orbital exenteration can be achieved via this access without particular difficulties. The resected bone walls can be repositioned after excision of the pathological processes.

#### CASE REPORTS

The indications for this surgical technique will be illustrated by some examples:

##### *Case 1: Inverted papilloma (Figures 1 and 2)*

The CT shows a tumour with extension in the right maxillary sinus, the right nasal cavity and the nasopharynx. Preoperatively, the histological examination of a biopsy specimen gave rise to the unconfirmed suspicion of a squamous cell carcinoma.

After midfacial degloving and temporary resection of parts of the maxillary sinus walls, the tumour was clearly demonstrable. The histological examination now yielded the diagnosis of inverted papilloma. Postoperatively, the patient's face showed no noticeable changes even though an extensive access had been created to provide a good overview.

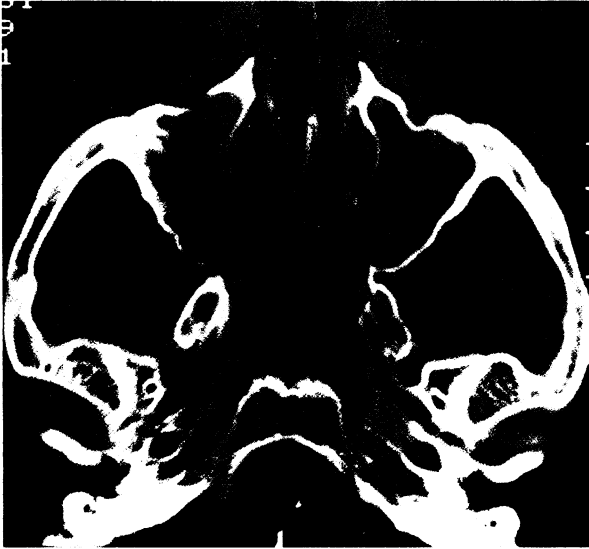

Figure 1. CT scan of inverted papilloma of right nasal cavity and nasopharynx.

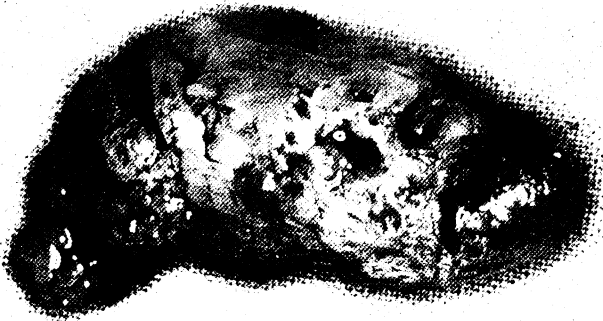

Figure 2. The resected tumour

*Case 2: Carcinoma of the left maxillary sinus (Figures 3 and 4)*

The tumour had perforated the anterior and dorsal maxillary sinus wall and reached the floor of the orbit.

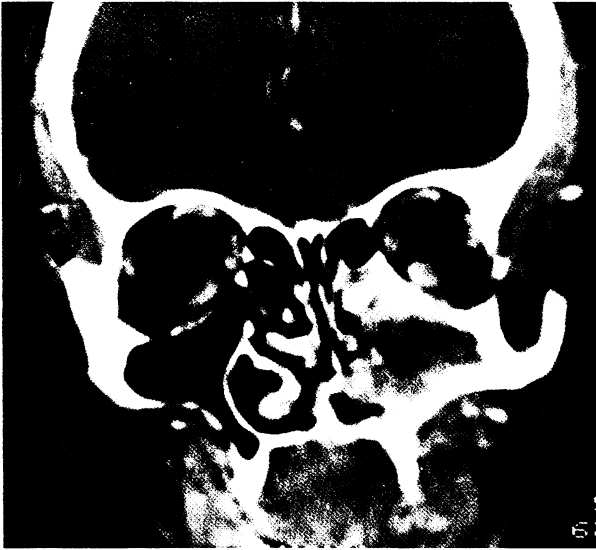

Figure 3. CT scan of carcinoma of left maxillary sinus.

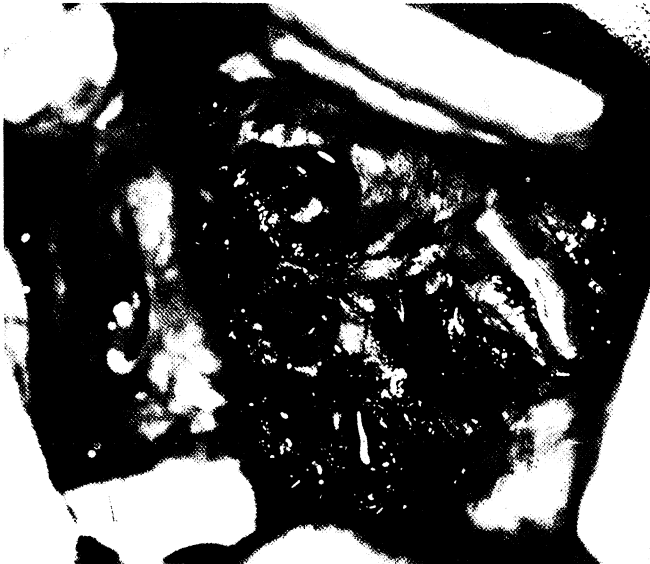

Figure 4. Intraoperative situation after left maxillectomy and orbital exenteration via midfacial degloving.

Exposure of the midface by degloving was followed by maxillary resection with orbital exenteration. Dura also had to be resected and submitted to plastic treat-

ment in the area of the ethmoidal roof because of destruction at the base of the skull. After resection of the wings of the sphenoid, there was no longer any macroscopic evidence of a tumour.

*Case 3: Juvenile angiofibroma*

The CT showed a tumour of the epipharynx, sphenoidal sinus and retromaxillary space. The structure, consisting of two main parts connected via the pterygo-maxillary fissure, was dumbbell-shaped. It was the recurrence, in a 17-year-old patient, of a juvenile angiofibroma that had been submitted to transpalatal surgery several years previously.

An embolization was performed prior to operation of the recurrent tumour; shortly thereafter, the intervention was carried out via midfacial degloving.

After extensive transoral exposure of the midfacial region while preserving the intraorbital nerves, the frontal and lateral maxillary sinus wall was temporarily resected together with a part of the zygoma (Figures 5 and 6).

From the described access, the tumour was then clearly demonstrable and could be removed in one piece. The tumour spread amounted to nearly 8 cm.

At the end of the intervention, the temporarily removed bone fragment was repositioned and fixed again. Even the patient himself noticed no appreciable post-operative changes except for a slight soft-tissue swelling that receded completely with a few weeks.

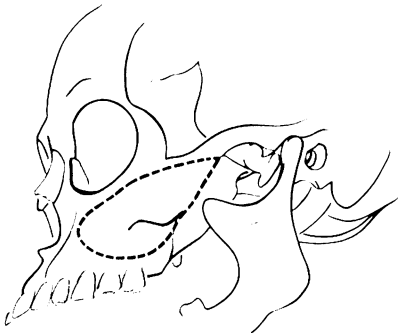

Figure 5. Dotted line: Parts of maxillary wall and zygoma to be resected for access to retromaxillary space via midfacial degloving.

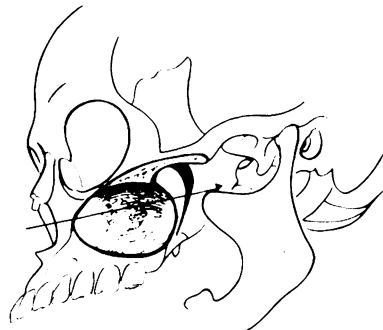

Figure 6. Anterior operative access to retromaxillary space after bone resection (Figure 3a) through midfacial degloving.

**RESULTS**

Having applied midfacial degloving 14 times so far, we should like to summarize our experience as follows:

Midfacial degloving provides an extensive overview by wide and, if necessary, bilateral access to the midface and its deeper regions. External facial scars are avoided. The procedure is suitable not only for larger benign tumours but also for malignant ones.

For otobasal processes, the temporal paths of access according to Fisch or Obwegeser are more appropriate. However, retromaxillary tumours situated more towards the middle of the skull base can be reached well via sublabial rhinotomy.

An interesting indication arises in connection with deepseated processes of unclarified histology. Then an external incision is avoided by midfacial degloving, while, at the same time, a radical operation can be performed via the same access if a malignant process is found.

According to our experience, no particular conditions of an unfavourable nature occur as a consequence of midfacial degloving. This technique represents an advance for head and neck surgeons who perform more extensive interventions in the midfacial area.

**REFERENCES**

1. Berghaus A. Midfacial degloving. *HNO*, 1990; 38: 7-11.
2. Conley J, Price JC. Sublabial approach to the nasal and nasopharyngeal cavities. *Am J Surg* 1979; 138: 615-618.
3. Maniglia AJ. Indications and techniques of midfacial degloving. A 15-year experience. *Arch Otolaryngol Head Neck Surg* 1986; 112: 750-752.
4. Fisch U, Mattox D. *Microsurgery of the skull base*. Stuttgart, New York: Thieme, 1988.
5. Hadjiangelou O, Obwegeser HL. Temporal Zugang zum retromaxillären-infrakranialen Raum und zur Orbita in der Tumorchirurgie. *Lar Rhinol Otol* (1986); 65: 46-56.

Prof. Dr. A. Berghaus  
Dr. S. Jovanovic  
HNO-Abteilung  
Universitätsklinikum Steglitz  
Hindenburgdamm 30  
D-1000 Berlin 45  
Germany