

Distribution of T-lymphocyte subsets in porcine lymphoid tissues

N. JONJIĆ,* S. JONJIĆ,† A. SAALMÜLLER,‡ D. RUKAVINA† & U. H. KOSZINOWSKI‡ *Departments of*

** Anatomy, and † Physiology and Immunology, Medical Faculty, University of Rijeka, Rijeka, Yugoslavia, and ‡ Federal Research Centre for Virus Diseases of Animals, Tübingen, West Germany*

Accepted for publication 7 November 1986

SUMMARY

The distribution of the functional subsets of porcine T cells, the cytolytic/suppressor (Tc/s) and the helper/inducer (Th/i) cells was studied in cryostat sections of thymus, lymph nodes, tonsils, Peyer's patches, spleen and liver using the indirect immunoperoxidase technique. Three murine monoclonal antibodies (mAb) were used. The mAb 8/1 reacts with an antigen present on all T cells and on cells of the myeloid lineage; the antigen has not yet been characterized biochemically. The mAb 295/33 (anti-T8) binds to the porcine T8 antigen and defines the Tc/s subset, while mAb PT-4 (anti-T4) detects the porcine T4 antigen and defines the Th/i subset. Practically all thymocytes were stained by mAb 8/1. The majority of cortical thymocytes apparently co-expressed T8 and T4, whereas distinct fractions of medullary cells were labelled by either anti-T8 or anti-T4. In peripheral lymphoid organs all three mAb reacted with cells in the thymus-dependent areas and with cells scattered in the lymphoid follicles. In lymph nodes, tonsils and Peyer's patches, anti-T8 and anti-T4 each labelled approximately half of the cells stained by mAb 8/1. In the periarteriolar lymphoid sheath of the spleen, anti-T4 labelled more cells than did anti-T8. The reactivity of mAb 8/1 with the Kupffer cells of the liver demonstrated the expression of the 8/1 antigen on cells of the monocyte lineage. The T8 and T4 antigens could not be detected in acetone-fixed and paraffin-embedded sections, while the antigen recognized by mAb 8/1 remained preserved. Altogether, despite an inverted microanatomical structure of porcine lymph nodes, the frequency and distribution of T8⁺ and T4⁺ cells in thymus-dependent areas proved to be similar to those found in other species.

INTRODUCTION

The use of monoclonal antibodies (mAb) in the peroxidase immunohistochemical technique offers several advantages for studying the distribution of T and B lymphocytes and their subpopulations in lymphoid and non-lymphoid tissues. This has been demonstrated in several mammalian species by detailed investigation of the anatomical distribution of lymphocyte subpopulations by using mAb directed to cell surface antigens (Bhan *et al.*, 1980, 1981; Poppema *et al.*, 1981; Barclay, 1981; Hsu, Cossman & Jaffe, 1983; Van Ewijk *et al.*, 1981).

Despite several functional and anatomical studies on the porcine immune system (for review see Binns, 1982; Salmon, 1982; Pabst, Binns & Licence, 1985; Thistlethwaite *et al.*, 1983; Denecke, Mannuss & Trautwein, 1985), only limited information could be given on the anatomical distribution of porcine T-lymphocyte subsets because, in the past, subset-specific reagents were not available. Studies with mAb are required to complete the characterization of the porcine immune system and, because of the peculiar and unusual functional microanatomy of the

porcine lymphoreticular tissue (Binns, 1982), are also of interest for comparative anatomy. In the pig, lymph nodes are structurally inverted, with medullary tissues at the periphery and thymus-dependent, cortical tissues in central parts adjacent to the trabecular lymph sinuses that transport the afferent lymph. In addition, efferent lymph is almost acellular, reflecting a difference in lymphocyte recirculation pathways (Binns, 1982; Binns *et al.*, 1985).

Recently, a series of mAb reactive with porcine thymocytes and T lymphocytes has been produced. These mAb allow the characterization of T-lymphocyte subsets and their function (Jonjić & Koszinowski, 1984; Pescovitz, Lunney & Sachs, 1984, 1985).

In order to define the tissue distribution of the porcine Tc/s and Th/i cell subsets, the present study makes use of mAb 295/33 (in this paper referred to as anti-T8), which under reducing conditions precipitates the 33,000–35,000 molecular mass porcine T8 analogue (Jonjić & Koszinowski, 1984), and of mAb PT-4 (in this paper referred to as anti-T4), which under reducing conditions precipitates the 55,000 molecular mass porcine T4 analogue (Pescovitz, Lunney & Sachs, 1985). In order to compare these T-cell subsets with the whole T-cell population, mAb 8/1 was used. This antibody detects a T-cell associated

Correspondence: Dr U. H. Koszinowski, Federal Research Centre for Virus Diseases of Animals, PO Box 1149, D-7400 Tübingen, West Germany.

antigen that is not expressed on B cells (A. Saalmüller *et al.*, submitted). The data show that in porcine lymphoid tissues the relative frequencies of Tc/s and Th/i cells are similar to those known for other mammalian species.

MATERIALS AND METHODS

Animals

Six-month to 1-year-old healthy pigs were used in this study. The animals were killed by exsanguination under anaesthesia.

Antibodies

The preparation of murine monoclonal antibodies with specificity for porcine lymphocytes has been described elsewhere (Jonjić & Koszinowski, 1984). MAb used in present study include: 295/33 (anti-T8; IgG2a, κ), 8/1 (IgG2b, κ) and PT-4 (anti-T4; IgG2b, κ). The PT-4 hybridoma line, produced by Pescovitz *et al.* (1985), was obtained through Litton Bionetics, Rockville, MD (Hyb 74-12-4, SP-353, VRL-501244). The reactivity of these mAb with porcine lymphoid cells is shown in Table 1. Biotin-conjugated horse anti-mouse IgG (H+L), goat anti-pig IgG (H+L), and avidin-conjugated horseradish peroxidase were obtained from Vector Laboratories (Burlingame, CA).

Immunoperoxidase analysis of tissue sections: avidin-biotin-peroxidase (ABP) method

Cryostat sections of porcine thymus, lymph nodes, tonsils, Peyer's patches, spleen and liver were stained with mAb 8/1, anti-T8 and anti-T4. We followed the method originally described by Hsu, Raine & Fanger (1981). Cryostat sections (5–8 μ m) on gelatin-coated slides were dried at 4° overnight. Before incubation with antibodies, the sections were dipped in acetone for 10 min and then repeatedly washed in phosphate-buffered saline (PBS), pH 7.4. After incubation for 30 min in normal horse serum (diluted 1:100), the sections were covered for 30–60 min with mAb ascites (diluted 1:100) or control ascites containing irrelevant antibody. The slides were thoroughly washed in PBS and incubated for 30 min with horse anti-mouse

IgG (H+L)-biotin. Endogenous peroxidase activity was blocked by 30 min incubation in H₂O₂ (0.3% in methanol). After washing in PBS, the slides were incubated for 30–60 min in avidin-horseradish peroxidase (1 μ g/ml in PBS). Antibody binding was visualized by 5 min incubation in substrate containing 10 mg diaminobenzidine (Sigma, St Louis, MO), 0.1 ml 8% NiCl₂, and 5 μ l of 3% H₂O₂ in 20 ml of PBS. To detect Ig⁺ cells, frozen sections were incubated with biotin-conjugated goat anti-pig IgG (H+L), avidin-conjugated horseradish peroxidase, and diaminobenzidine (two-step ABP method). The slides were mounted with glycerol gelatin and analysed by light microscopic inspection. In some experiments, acetone-fixed and paraffin-embedded tissue sections were also processed according to the method described by Hsu, Zang & Jaffe (1983).

Cytofluorographic analysis

Porcine thymocytes were incubated for 30 min at 4° with a saturating concentration of mAb (100 μ l of ascites diluted 1:100). Thereafter, the cells were washed three times in PBS supplemented with 4% FCS, 10 mM EDTA, 20 mM HEPES, and 0.1% NaN₃ (FACS buffer). Cells were then incubated for 30 min at 4° with FITC-conjugated goat anti-mouse IgG F(ab')₂ (Jackson Laboratories, Avondale, PA). After washing in FACS buffer, the cells were resuspended and kept on ice until used. Cytofluorographic analysis was performed on a fluorescence-activated cell sorter (FACS IV; Becton-Dickinson FACS Systems, Sunnyvale, CA) as described elsewhere (Jonjić & Koszinowski, 1984). Slight differences between individual experiments in the scaling of the relative number of cells per channel are due to the computerized calculation. The logarithmically amplified fluorescence signal is represented on a 255-channel scale covering about five decades. At least 1 \times 10⁴ viable cells were analysed in each experiment. Monoclonal antibodies with irrelevant specificity caused background levels of fluorescence.

RESULTS

All three mAb used in this study produced clear membrane staining when the avidin-biotin-peroxidase method was applied. Methanol-H₂O₂ successfully blocked the endogenous

Table 1. Monoclonal antibodies reactive with porcine T lymphocytes

T-lymphocyte subset	mAb	Antigens	MW $\times 10^{-3}$	Percentage of positive cells* in:				
				Bone marrow	Thymus	Peripheral blood lymphocytes	Spleen	Lymph node
Cytolytic and suppressor T cells	(295/33)† α T8	T8	33–35	5	70–80	40–50	15–24	23–40
Helper and inducer T cells	(PT4)‡ α T4	T4	55	4	59	40–50	21	44
All T lymphocytes§	8/1¶	8/1	u**	20	95	95	32–43	80

* Mean percentage of cells stained by supernatant-derived mAb in indirect immunofluorescence. Cells were subjected to lymphoprep separation, and at least 200 cells were counted. The percentage of cells stained by second antibody alone, about 3–5%, was not subtracted. Data are from three assays with different pigs used as cell donors. Numbers of 5% and smaller values are in the range of the arbitrary negative cut-off.

† Jonjić & Koszinowski (1984).

‡ Pescovitz, Lunney & Sachs (1984, 1985).

§ Sum of T8- and T4-positive cells.

¶ A. Saalmüller *et al.*, submitted; the antibody also reacts with monocytes and granulocytes.

** u = unknown: the antigen could not be immunoprecipitated.

peroxidase activity of most cells without interfering with the specific staining reaction. Replacement of specific mAb by irrelevant antibody yielded no membrane staining of cells. In all tissues tested, the staining was most bright with mAb 8/1, and the lowest intensity was seen with anti-T4. In addition to the weak but specific staining of cells in thymus and in thymus-dependent areas of the peripheral lymphoid organs, anti-T4 produced a faint diffuse background, which in some sections caused difficulties in the discrimination of positive from negative cells. This was not caused by antibody concentration or a particular Ig subclass since irrelevant mAb of the same Ig class and similar Ig concentration did not produce this background.

Thymus

All three mAb were found to stain the great majority of cortical thymocytes indicating the co-expression of the respective antigens (Fig. 1). Only mAb 8/1 also stained the majority of thymocytes in the medulla (Fig. 1a), whereas a large proportion of medullary cells was not stained with anti-T8 (Fig. 1b) or anti-T4 (Fig. 1c). Thus, based on T8 and T4 antigen expression, cortex and medulla could be clearly demarcated.

FACS analysis using the mAb 8/1, anti-T8, and anti-T4 was concordant with the immunohistological findings. Figure 1d-f shows fluorescence profiles obtained after incubation of thymocytes with mAb and FITC-labelled goat anti-mouse Ig. MAb 8/1

(Fig. 1d) reacted with practically all thymocytes and the high staining intensity found in immunohistology apparently correlates with a high antigen density. As expected, mAb anti-T8 (Fig. 1e) and anti-T4 (Fig. 1f) each stained approximately 60–70% of the cells. Differences in the staining intensities of anti-T8 and anti-T4 observed in tissue sections were not reflected by FACS analysis.

Lymph nodes

A great majority of cells residing in the perifollicular or interfollicular areas of the central cortex, i.e. the thymus-dependent domains in porcine lymph nodes, were brightly stained by mAb 8/1, whereas in the follicles only a few cells were stained. In the peripheral medulla only a small fraction of cells carried the antigen recognized by mAb 8/1. An example of this type of staining is shown at low power magnification in Fig. 2a. Both anti-T8 (Fig. 2c) and anti-T4 (Fig. 2d) probably stained 8/1⁺ cells (Fig. 2b) in the perifollicular region, and the numbers of T8⁺ and T4⁺ cells appeared to be similar. The majority of cells was found to be antigen-positive when neighbouring tissue sections from the same tissue specimen were incubated with either anti-T8 or anti-T4. This indicated that, in some areas, some cells probably carry both markers.

Scattered T8⁺ and T4⁺ cells were present also in the medullary area. It should be noted that we consistently observed

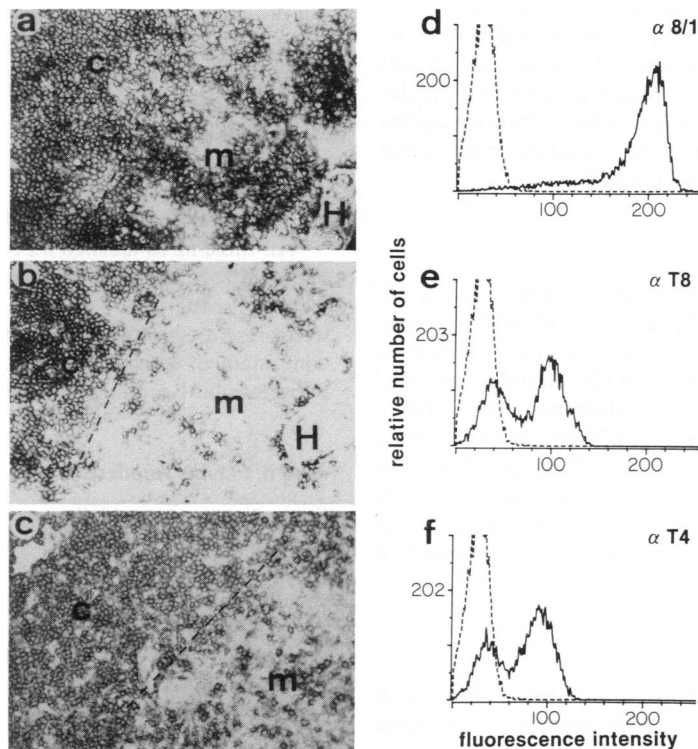


Figure 1. Frozen sections of porcine thymus stained with (a) mAb 8/1, (b) 295/33 (anti-T8), and (c) PT-4 (anti-T4). The majority of cells in the cortex show membrane staining with all three mAb. In the medulla, mAb 8/1 also stained the majority of cells, while anti-T8 and anti-T4 each stained about 70% of cells, albeit with different intensity. c = cortex, m = medulla, H = Hassall's corpuscle. The dashed line indicates the boundaries of cortex and medulla (magnification $\times 150$). FACS analysis (d–f): fluorescence histograms of porcine thymocytes labelled with (d) mAb 8/1, (e) 295/33 (anti-T8), and (f) PT-4 (anti-T4). Labelling with second antibody alone served as negative controls (dashed lines). Relative fluorescence intensities are expressed on a log scale with 10^4 cells analysed.

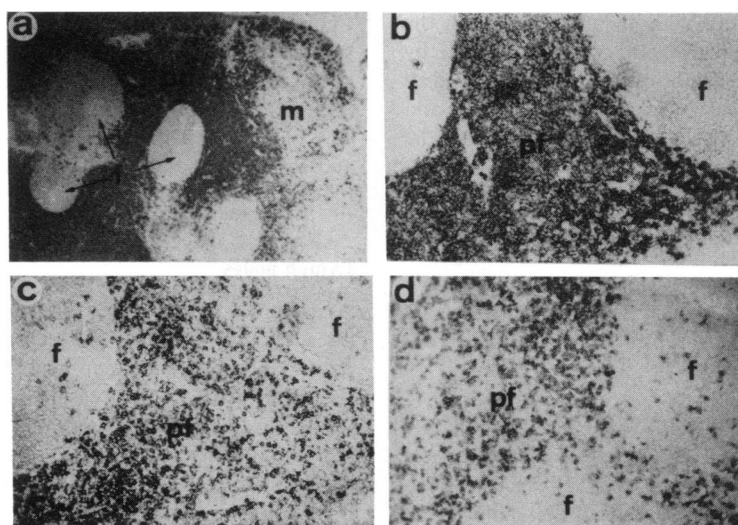


Figure 2. Staining of porcine lymph node cryostat sections with (a and b) mAb 8/1, (c) anti-T8, and (d) anti-T4. Note that mAb 8/1 stains the majority of cells in perifollicular areas, whereas anti-T8 and anti-T4 both stain only a proportion of cells in these domains. Scattered cells positive for all three mAb were seen in follicles. f = follicles, pf = perifollicular (interfollicular) area, m = medulla, pc = paracortex (magnification of (a) $\times 13$ and of (b), (c) and (d) $\times 96$).

that T8⁺ cells in the medulla and in the cortico-medullary junction exhibited a more intensive staining by anti-T8 than did cortical cells (not shown). The B cells in the lymphoid follicles of the lymph node clearly stained with biotin-labelled goat anti-pig IgG, while cells in the mantle zone of the secondary follicles exhibited only weak membrane staining. The majority of B cells in germinal centres showed both membrane and intracellular staining. In extrafollicular regions, i.e. in the thymus-dependent domains, only a few scattered Ig⁺ cells could be detected that exhibited bright membrane staining (not shown).

Tonsils

The staining pattern of tonsillar sections with mAb 8/1, anti-T8, and anti-T4 was congruent with that of lymph node sections. However, the tonsils contained more and smaller lymphoid follicles than the lymph nodes. Cells in the interfollicular areas were intensively stained by mAb 8/1, while the follicles usually contained only a few 8/1⁺ cells (Fig. 3a). These results are in line with the non-reactivity of mAb 8/1 with B lymphocytes. The accumulation of T8⁺ and T4⁺ cells in the perifollicular areas was comparable to the distribution pattern in lymph nodes. Again, both mAb also stained cells scattered at random in follicles (Fig. 3b and c).

Peyer's patches

Tissue sections were prepared from the distal part of the small intestine that contained aggregates of lymphocytes in the form of Peyer's patches and scattered lymphocytes in the lamina propria (Fig. 3d–f). MAb 8/1 labelled the cells in the interfollicular zone and only a few single cells in follicles (Fig. 3d). The T-cell subset markers T8 and T4 were expressed each by approximately half of the cells reactive with mAb 8/1 (Fig. 3e and f). T4⁺ and T8⁺ lymphocytes were also found to be sporadically distributed in the region of the lamina propria.

Spleen

Spleen tissue sections incubated with mAb 8/1, anti-T8 and anti-T4 showed the presence of antigen-positive cells in the typical T-cell domain, i.e. the so-called periarteriolar lymphoid sheath, which is represented by cells surrounding the branches of the central splenic arterioles (Fig. 3g–i). In this area, the number of 8/1⁺ cells represented the sum of T4⁺ and T8⁺ cells, or even exceeded this number. Different to the situation found in lymph nodes, tonsils and Peyer's patches, the T4⁺ cells residing in the periarteriolar lymphoid sheath of the spleen appeared to be more frequent than cells stained by anti-T8 (Fig. 3h and i).

All three mAb labelled a proportion of lymphocytes in the marginal zone but only a few cells in the follicular areas. In the red pulp, scattered 8/1⁺ and T8⁺ cells and almost no T4⁺ cells were present. Some 8/1⁺ cells in the red pulp and in the marginal zone stained with a higher intensity than did cells of the periarteriolar lymphoid sheath (not shown).

mAb 8/1 stains Kupffer cells

Since it was observed that mAb 8/1 stains peripheral blood monocytes as well as spleen macrophages (S. Jonjić, unpublished data), it was tested as to whether other cells of the reticulo-endothelial system also express this antigen. Frozen liver sections were stained with mAb 8/1, anti-T8 and anti-T4. mAb 8/1 stained stellate cells lining the trabecular liver cells (Fig. 4a), while anti-T8 and anti-T4 showed no staining (data not shown).

Reactivity of mAb with paraffin-embedded lymph node sections

The possibility of using mAb 8/1, anti-T8 and anti-T4 in acetone-fixed and paraffin-embedded tissue sections was tested. Only mAb 8/1 produced a staining pattern that was comparable to that in frozen sections of lymph nodes (Fig. 4b). Anti-T4 and

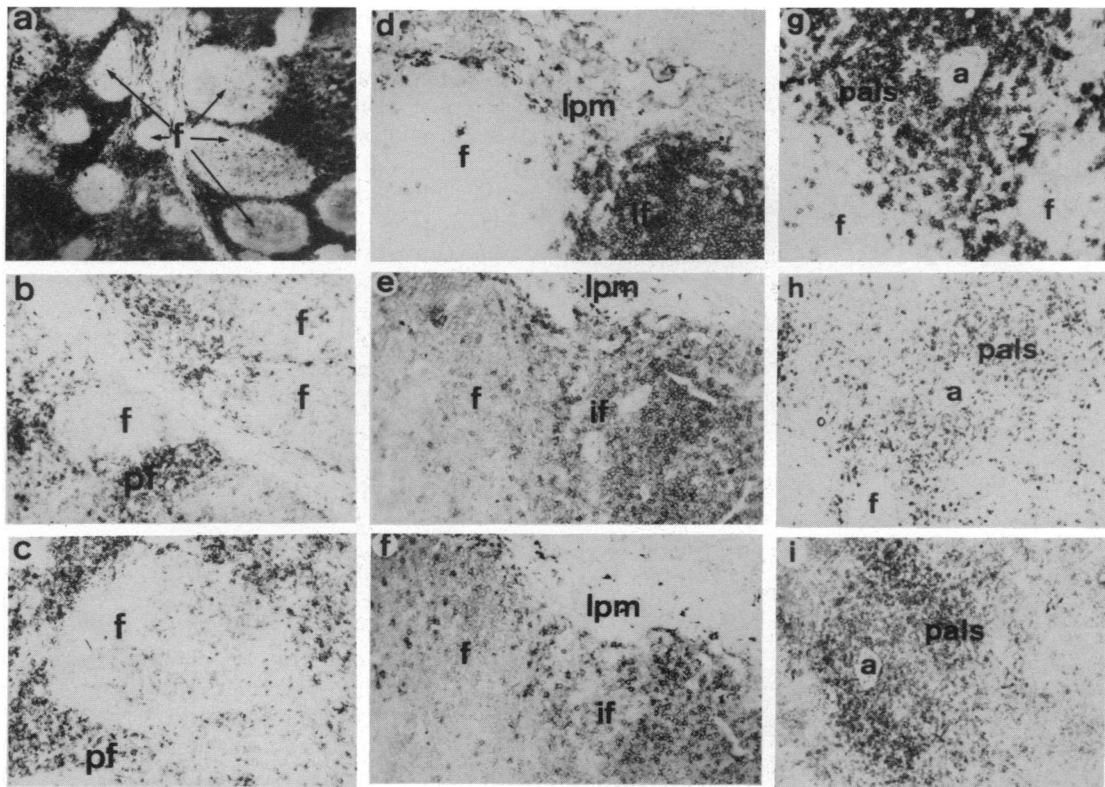


Figure 3. (a–c) Frozen sections of porcine tonsils stained with (a) mAb 8/1, (b) anti-T8, and (c) anti-T4. The majority of cells in the perifollicular areas are stained with mAb 8/1, while the cells in the follicles are not. Anti-T8 and anti-T4 stained only a proportion of cells in the interfollicular areas and a few scattered cells in the follicles. f = follicles, pf = perifollicular area (magnification (a) $\times 12$, (b and c) $\times 128$). (d–f) Staining of porcine Peyer's patches with (d) mAb 8/1, (e) anti-T8, and (f) anti-T4. All three mAb stained the cells in the interfollicular areas and a few cells in the follicles. f = follicles, if = interfollicular area, lpm = lamina propria mucosae (magnification $\times 128$). (g–i) Staining of porcine spleen sections with (g) mAb 8/1, (h) anti-T8, and (i) anti-T4. The majority of cells in the periarteriolar lymphoid sheath and cells scattered in the follicles were stained with mAb 8/1. Note that anti-T4 stained more cells in the periarteriolar lymphoid sheath than anti-T8. a = arteriole, f = follicles, pals = periarteriolar lymphoid sheath (magnification $\times 128$).

anti-T8 did not produce any membrane staining. This indicates that the fixation and embedding procedure resulted in the destruction or masking of the respective antigens (not shown).

DISCUSSION

Two T-lymphocyte subset-specific mAb and a mAb specific for a T-lymphocyte associated antigen were used to determine the tissue location of T-lymphocyte subpopulations in frozen sections of porcine lymphoid organs by means of the avidin–biotin–immunoperoxidase technique. One-parameter FACS analysis revealed that the difference in staining intensity was probably related to the density of surface antigens. Dual-parameter FACS analysis has revealed that T8⁺ and T4⁺ lymphocytes in the peripheral blood carry the 8/1 antigen (A. Saalmüller *et al.*, submitted). Thus, mAb 8/1 can serve as a porcine pan-T-cell marker. Staining of tissue sections demonstrated that mAb 8/1 reacts with almost all thymocytes and the majority of cells in thymus-dependent areas of lymph nodes, tonsils, spleen and Peyer's patches. Only few cells in the follicles were stained because mAb 8/1 does not react with B lymphocytes. These results are in agreement with our functional studies, which showed that the depletion of 8/1⁺ cells from lymphocyte populations selectively abrogates the proliferative response of T

cells to antigens and mitogen (A. Saalmüller *et al.*, submitted). In addition, mAb 8/1 also reacts with peripheral blood monocytes and spleen macrophages as well as with Kupffer cells in the liver. Therefore, 8/1 does not have an exquisite specificity for T cells. This fact has to be considered in the interpretation of the results. Given this additional reactivity of 8/1, the distribution of T cells was still remarkably similar to results obtained with a polyclonal anti-T-lymphocyte serum preabsorbed on granulocytes, monocytes and B cells (Denecke *et al.*, 1985). Since the antigen recognized by mAb 8/1 was not destroyed in acetone-fixed and paraffin-embedded lymph node sections, this antibody is suitable for routine immunohistological investigation of the distribution of T cells and monocytes under various pathological conditions. The 8/1 antigen is expressed at a high density on T cells, and hence demonstrated the inverted porcine lymph node architecture very clearly. Densely packed 8/1 antigen-positive T lymphocytes were located in the central area of the porcine lymph node, which functionally corresponds to the cortex of the conventionally oriented lymph node, and scattered 8/1 antigen-positive T lymphocytes were seen in the peripheral medullary domains (Binns, 1982).

In lymphoid tissues, the sum of cells of the Tc/s and the Th/i subset should roughly equal the total number of T cells stained with mAb 8/1. A high proportion of cortical thymocytes was

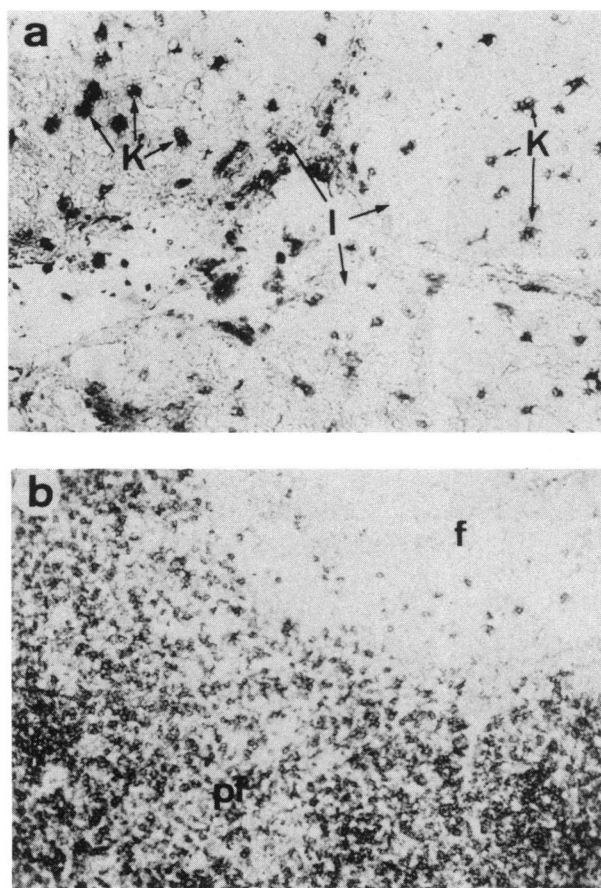


Figure 4. (a) Staining of Kupffer cells in porcine liver with mAb 8/1.1 = lobulus, K = Kupffer cells (magnification $\times 210$). (b) Binding of mAb 8/1 to cells in a section of an acetone-fixed, paraffin-embedded lymph node. The staining pattern was comparable to that of frozen sections. Fixation and embedding procedure did not affect the antigenic epitope recognized by this antibody. f = follicles, pf = perifollicular area (magnification $\times 112$).

also stained with both anti-T8 and anti-T4, thus indicating co-expression of all three antigens on cortical thymocytes. The immunoperoxidase method used in the present study did not allow the simultaneous investigation of the presence of more than one antigen. Therefore, we cannot conclude with certainty that a given T cell was reactive with both anti-T8 and anti-T4. Different to the situation in the cortex, only a fraction of medullary cells was immunoreactive with anti-T8 or anti-T4. The distribution pattern and staining intensity of T8⁺ and T4⁺ cells are concordant with those of cells bearing T8 (CD-8) and T4 (CD-4) markers in human thymus (Bhan *et al.*, 1980). The results suggest that in the swine the distribution of immature and more mature thymocytes as well as the expression of T-cell specific antigens are similar to those found in other species (Van Ewijk, Van Soest & Van Den Engh, 1981; Van Ewijk, 1984; Bhan *et al.*, 1980).

Unexpected was the relationship between T8⁺ and T4⁺ cells in peripheral lymph nodes. In man, mouse and rat, the T4⁺ Th/i cells represent the major proportion of T lymphocytes in the perifollicular areas, while only a smaller fraction of cells in these areas bear the T8 (Tc/s) marker (Poppema *et al.*, 1981; Mason *et*

al., 1983; Van Ewijk, 1984). In porcine lymph nodes and tonsils, we did not observe this predominance of T4⁺ over T8⁺ cells. This could indicate that, in this respect, the porcine immune system differs from that of other species. However, the apparent reactivity of the majority of 8/1⁺ cells in the perifollicular area with both T-cell subset-specific antibodies indicated T cells bearing both markers. Thus, co-expression of the T8 antigen by a number of T4⁺ Th/i cells would explain why more cells of the Tc/s phenotype were found in thymus-dependent areas of the porcine lymph node than to be expected from results obtained in other species. This conclusion is further supported by the results of Pescovitz, Lunney & Sachs (1985), who determined the number of cells expressing both T8 and T4 to be 6–15% of the peripheral blood lymphocytes. Furthermore, co-expression of T4 and T8 has also recently been demonstrated for human peripheral blood T cells by two-colour fluorescence (Blue *et al.*, 1985). The frequency of post-thymic porcine T cells with T4/T8 co-expression is currently under investigation by flow cytometry.

The deep diffuse cortex or paracortex, the peripheral medulla, and the paracortico-medullary junction contained a small number of very intensely stained T8⁺ cells. Because this compartment has been reported to contain more lymphoblasts (Binns, 1982), one could suggest that expression of the T8 antigen is increased after T-cell activation.

In conclusion, mAbs 8/1, 295/33 and PT-4 have proven to allow studies on the tissue distribution of porcine T cells and their functional subsets. This analysis was not hampered by the fact that mAb 8/1 also reacts with cells of the myeloid lineage. These three antibodies in combination will be useful in detailed studies on the porcine T-lymphocyte response to allografts and to infectious agents.

ACKNOWLEDGMENTS

We are indebted to H.-J. Bühring, Tübingen, for the FACS analysis. This work was supported by grant Ko 571/9 from the Deutsche Forschungsgemeinschaft, and by SIZ-V SR Croatia.

REFERENCES

- BARCLAY A.N. (1981) The localization of populations of lymphocytes defined by monoclonal antibodies in rat lymphoid tissues. *Immunology*, **42**, 593.
- BHAN A.K., NADLER L.M., STASHENKO P., MCCLUSKEY R.T. & SCHLOSSMAN S.F. (1981) Stages of B cell differentiation in human lymphoid tissue. *J. exp. Med.* **154**, 737.
- BHAN A.K., REINHERZ E.L., POPPEMA S., MCCLUSKEY R.T. & SCHLOSSMAN S.F. (1980) Location of T cell and major histocompatibility complex antigens in the human thymus. *J. exp. Med.* **152**, 771.
- BINNS R.M. (1982) Organisation of the lymphoreticular system and lymphocyte markers in the pig. *Vet. Immunol. Immunopath.* **3**, 95.
- BINNS R.M., PABST R. & LICENCE S.T. (1985) Lymphocyte emigration from lymph nodes by blood in the pig and efferent lymph in the sheep. *Immunology*, **54**, 105.
- BLUE M.-L., DALEY J.F., LEVINE H. & SCHLOSSMAN S.F. (1985) Coexpression of T4 and T8 on peripheral blood T cells demonstrated by two-color fluorescence flow cytometry. *J. Immunol.* **134**, 2281.
- DENECKE R., MANNUS B. & TRAUTWEIN G. (1985) Immunological and enzyme histochemical identification of lymphocyte subpopulations in pig lymphoreticular tissues. *Zbl. Vet. Med. B* **32**, 660.
- HSU S.M., COSSMAN J. & JAFFE E.S. (1983) Lymphocyte subsets in normal human lymphoid tissues. *Am. J. clin. Pathol.* **80**, 21.

- HSU S.M., RAINE L. & FANGER H. (1981) The use of avidin-biotin-peroxidase complex (ABC) in immunoperoxidase techniques. A comparison between ABC and unlabelled antibody PAP procedures. *J. Histochem. Cytochem.* **29**, 577.
- HSU S.M., ZANG H.Z. & JAFFE E.S. (1983) Utility of monoclonal antibodies directed against B and T lymphocytes and monocytes in paraffin-embedded sections. *Am. J. clin. Pathol.* **80**, 415.
- JONJIĆ S. & KOSZINOWSKI U.H. (1984) Monoclonal antibodies reactive with swine lymphocytes. I. Antibodies to membrane structures that define the cytolytic T lymphocyte subset in the swine. *J. Immunol.* **133**, 647.
- MASON D.W., ARTHUR P.R., DALLMAN M.J., GREEN J.R., SPICKETT G.P. & THOMAS M.L. (1983) Functions of rat T-lymphocyte subsets isolated by means of monoclonal antibodies. *Immunol. Rev.* **74**, 57.
- PABST R., BINNS R.M. & LICENCE S.T. (1985) Surface markers on lymphocytes leaving pig lymph nodes. *Immunology*, **56**, 301.
- PESCOVITZ M.D., LUNNEY J.K. & SACHS D.H. (1984) Preparation and characterization of monoclonal antibodies reactive with porcine PBL. *J. Immunol.* **133**, 368.
- PESCOVITZ M.D., LUNNEY J.K. & SACHS D.H. (1985) Murine anti-swine T4 and T8 monoclonal antibodies: distribution and effects on proliferative and cytotoxic T cells. *J. Immunol.* **134**, 37.
- POPPEMA S., BHAN A.K., REINHERZ E.L., MCCLUSKEY R.T. & SCHLOSSMAN S.F. (1981) Distribution of T cell subsets in human lymph nodes. *J. exp. Med.* **153**, 30.
- SALMON H. (1982) Characterization of pig lymphocyte receptors for allogeneic and non allogeneic erythrocytes. I. Apparent common identity of both receptors. *Clin. exp. Immunol.* **48**, 574.
- THISTLETHWAITE J.R., PENNINGTON L.R., LUNNEY J.K. & SACHS D.H. (1983) Immunological characterization of MHC recombinant swine. Definition of SLA class-specific antisera and detection of Ia antigens on both B and non B PBL. *Transplantation*, **35**, 394.
- VAN EWIK W. (1984) Immunohistology of lymphoid and non-lymphoid cells in the thymus in relation to lymphocyte differentiation. *Am. J. Anat.* **170**, 311.
- VAN EWIK W., VAN SOEST P.L. & VAN DEN ENGH G.J. (1981) Fluorescence analysis and anatomic distribution of mouse T lymphocyte subsets defined by monoclonal antibodies to the antigens Thy-1, Lyt-1, Lyt-2, and T-200. *J. Immunol.* **127**, 2594.