

REVIEW ARTICLE

Comparison of guidelines for the management of patients with high-risk and advanced cutaneous squamous cell carcinoma – a systematic review

M.V. Heppt,^{1,*}  T. Steeb,¹ C. Berking,¹ A. Nast²¹Department of Dermatology and Allergy, University Hospital, LMU Munich, Munich, Germany²Division of Evidence-Based Medicine (dEBM), Department of Dermatology, Venereology and Allergy, Charité – Universitätsmedizin Berlin, Corporate Member of Freie Universität Berlin, Humboldt-Universität zu Berlin and Berlin Institute of Health, Berlin, Germany

*Correspondence: M.V. Heppt. E-mail: Markus.Heppt@med.uni-muenchen.de

Abstract

The management of high-risk cutaneous squamous cell carcinoma (cSCC) can be a challenge as evidence from high quality clinical trials is rare. Guideline developers are challenged to provide practical and useful guidance for clinicians even in the absence of good evidence. In order to compare treatment recommendations for high-risk and advanced cSCC among national and international guidelines and to extract the most precise guidance provided, a systematic search was carried out in guideline databases Medline and Embase with a cutoff of 4 March 2019. Treatment recommendations for predefined clinical scenarios were extracted from selected guidelines and compared qualitatively. Five guidelines published from 2015 to 2018 were included. Excision of high-risk tumours with margin assessment was recommended in all guidelines. A safety margin of at least 6 mm was suggested in four guidelines. There was no clear recommendation to perform a sentinel lymph node biopsy in any guideline. Lymph node dissection was uniformly recommended in the presence of nodal disease. Treatment for metastatic cSCC was poorly characterized and restricted to the use of chemotherapy and epidermal growth factor receptor inhibitors. Recommendations for the management of high-risk and advanced cSCC were limited. We propose that guidelines should be updated to reflect recent advances in checkpoint blockade for metastatic cSCC.

Received: 12 June 2019; Accepted: 24 July 2019

Conflicts of interest

MVH participated in advisory boards of Sanofi. CB reports personal fees as consultant and/or speaker as well as institutional grants from Bristol-Myers Squibb, Merck Sharp and Dome, Novartis, and Roche. CB reports personal fees as consultant from InflaRx, Merck and Sanofi-Aventis as well as institutional grants from Regeneron. The remaining authors declare no conflicts of interests.

Funding source

None declared.

Introduction

Cutaneous squamous cell carcinoma (cSCC) is a common form of skin cancer. Accordingly, a considerable number of national and international guidelines exist for the treatment of cSCC. Lymphogenic or haematogenous metastasis occurs in a minority of patients. Thus, larger studies and treatment recommendations are limited, especially in advanced stages of the disease. Furthermore, the management of cSCC is subject to country-specific healthcare conditions, which must be taken into consideration. In this article, we compare the recommendations of guidelines which are based on a systematic literature search to set an

evidence-based framework for global decision-making in patients with high-risk or advanced cSCC.

Methods

Eligibility criteria

Published national and international guidelines that included recommendations for the treatment and management of patients with advanced or high-risk cSCC were eligible. The guidelines had to state that they were based on a systematic literature review and to express at least one recommendation for one of

the following clinical scenarios of interest: (i) surgical removal of the primary tumour, (ii) treatment of unresectable cSCC, (iii) the performance of sentinel lymph node biopsy (SLNB) in high-risk tumours, (iv) indications for radiation therapy, (v) management of lymph node metastases, as well as (vi) systemic interventions for metastatic disease (Table 1). In order to provide a synopsis of the most recent and up-to-date recommendations, we only included guidelines that had not yet expired or are not about to expire in the year 2019. We also excluded guidelines published before 2012 or which did not provide any information on their validity date. Guidelines had to be published in English or German.

Search strategy and guideline selection

A systematic search for guidelines was carried out in guideline databases, including multidisciplinary guideline providers and subject-specific guideline providers (Table S1). The key search terms included 'squamous cell carcinoma' and the German translation 'Plattenepithelkarzinom'. Additionally, Medline and Embase (both via Ovid) were searched until 4 March 2019. The detailed search strategy is presented in Table S2. Two authors (MVH, TS) independently screened the titles and abstracts of the records that were identified in the databases for eligibility. For records that were considered potentially relevant, the full-text guidelines were obtained, and the inclusion and exclusion criteria were applied. Whenever discrepancies arose, resolution was achieved by discussion with a third independent author (CB, AN).

Collection, synthesis and management of the recommendations

Information on each included guideline regarding country of origin, publication date, approach to classify the evidence for the recommendations, as well as the recommendations of interest and their corresponding levels of evidence were collected and summarized by two authors independently (TS, MVH) to an extraction spreadsheet using Microsoft Excel 2010. The recommendations on the clinical key questions were extracted to the spreadsheet and compared qualitatively.

Results

Guideline identification

Our search in the databases and additional references revealed 1571 records (Fig. 1). After title and abstract screening and removal of duplicates, 14 records underwent full-text review. Two records were excluded since they were still in development or unpublished at the time of the search^{1,2} and one more duplicate was identified.³ Three guidelines were excluded as they were outdated.^{4–6} One guideline was only available as a presentation of an update and identifying clear-cut recommendations was difficult as no accompanying narrative was provided. Furthermore,

it had a preliminary character at the time of assessment.⁷ Two more records were ineligible as they either summarized the results of different guidelines or did not provide any recommendations.^{8,9} Hence, five relevant guidelines were included in this comparison.^{10–14}

Information and methodology of the guidelines

The publication date of the guidelines ranged from 2015 to 2018. Guidelines were available from consortia of the United States of America (US),¹⁰ Canada,¹¹ the United Kingdom (UK),¹³ and Europe.^{12,14} The Italian Guideline from Peris *et al.*¹⁴ was adapted from and updated the European guideline. The guidelines used distinct approaches to grade the level of evidence and to express the strength of their recommendations, limiting the cross-guideline comparability. The Canadian guideline used the GRADE approach to rate the certainty of the evidence.¹¹ For the guideline from the US, available evidence was evaluated with a unified system called the 'Strength of Recommendation Taxonomy' on a 3-tier-scale based on the quality of study methodology, and the overall focus of the study.¹⁰ The UK guideline labelled their evidence-based recommendations without a grade attached indicated by '(R)', and those based on clinical experience as a good practice point '(G)'.^{13,15} Both the European and Italian guidelines stated that a literature review had been performed; however, they did not provide any explanation of whether they had assessed the level of evidence of their recommendations.^{12,14}

Definition of high-risk cSCC

The risk of metastasis formation from cSCC is usually low and only a minority of patients develops lymphogenic or haematogenic metastasis during the course of the disease. A definition of high-risk cSCC is, therefore, of paramount importance to identify patients at risk early and to provide them with more intensive therapy and closer follow-up. High-risk features were specified in all of the included guidelines and can be divided into histological and clinical factors. Histological prognostic factors consistently reported in the guidelines were a poor differentiation according to the Broders classification and desmoplasia of the tumour, high vertical invasion depth (>2–4 mm) or Clark level (IV, V), perineural spread and lymphovascular invasion. Clinical factors were a horizontal extension >20 mm, poorly defined borders of the tumour, status after local recurrence, rapid tumour growth, neurological symptoms, and immunosuppression. However, all guidelines admit that the definition of these risk factors was mainly based on retrospective studies such as observational studies and case series and that only a few prospective studies exist which investigate high-risk features in a prospective and controlled fashion. In the following, critical clinical scenarios for high-risk tumours are presented and the recommendations from the included guidelines are compared qualitatively.

Table 1 Comparison of recommendations for high-risk and advanced cSCC among international treatment guidelines (*n* = 5)






Clinical scenarios/Key questions	US 2018 	Canada 2015 	UK 2016 	Europe 2015 	Italy/Europe 2018 
Definition of high-risk SCC	Clinical <ul style="list-style-type: none"> trunk/extremities ≥ 20 mm cheeks, forehead, scalp, neck, pretrichial: ≥ 10 mm central face, eyelids, eyebrows, periorbital skin, nose, lips, chin, mandible, preauricular and postauricular skin/sulci, temple, ear, genitalia, hands, and feet poorly defined borders recurrent immunosuppression site of prior radiation therapy or chronic inflammatory process rapidly growing tumor neurologic symptoms Pathologic <ul style="list-style-type: none"> poorly differentiated high-risk histologic subtype ≥ 2 mm depth/ Clark level IV, V perineural, lymphatic, or vascular involvement 	<ul style="list-style-type: none"> external ears, lips, scalp Size, diameter: ≥ 2 cm depth: ≥ 0.2 cm or Clark level IV or V poorly differentiated; Broders grade 3 or 4 immunosuppression perineural involvement recurrence rapid growth originating from chronic wound or scar 	<ul style="list-style-type: none"> size > 2 cm failure of previous treatment immunosuppression depth or invasion > 2 mm thickness Clark level > 4 perineural invasion primary site ear or hair-bearing lip poorly differentiated or undifferentiated 	<ul style="list-style-type: none"> tumor diameter: more than 2 cm ear/lip, non-sun exposed sites SCC arising in radiation sites, scars, burns chronic inflammatory conditions recurrent SCCs more than 6 mm/invasion beyond subcutaneous fat moderately, or poorly differentiated grade acantholytic, spindle, desmoplastic subtype perineural invasion surgical margins: incomplete excision immunosuppressed (organ transplant recipients, chronic immunosuppressive disease or treatment 	Clinical <ul style="list-style-type: none"> trunk/extremities ≥ 20 mm cheeks, forehead, scalp, neck, pretrichial ≥ 10 mm central face, eyelids, eyebrows, periorbital skin, nose, lips, chin, mandible, preauricular and postauricular skin/sulci, temple, ear, genitalia, hands, and feet poorly defined clinical margins recurrence immunosuppression radiotherapy or chronic inflammation site fast-growing tumor neurological symptoms Histology <ul style="list-style-type: none"> poorly differentiated histological grade histologic subtype: acantholytic, desmoplastic, adeno-squamous tumor thickness ≥ 2 mm or Clark level IV, V perineural, lymphatic or vascular invasion
Management of the primary tumor site	Excision with subsequent conventional histological processing of the specimen in the bread loaf technique or with post-operative margin assessment	High (LoE: moderate, strength: strong)	Moderate ('should be excised')	High ('treatment of choice')	High ('is recommended for tumors of < 6 mm thickness and high-risk features (histologically undifferentiated, perineural invasion, recurrent tumors) and for tumors with histological vertical thickness of > 6 mm')

Table 1 Continued










Clinical scenarios/Key questions	US 2018 	Canada 2015 	UK 2016 	Europe 2015 	Italy/ Europe 2018 
Safety margin for surgical resection of high-risk tumors	–	6–13 mm	6 mm	≥10 mm	10 mm
Removal by Mohs micrographic surgery with a complete examination of the margins for high-risk tumors	High ('is recommended', II/III B)	High (LoE: high, strength: strong)	Weak ('has a role in some high-risk cSCC cases after discussion in a multidisciplinary setting')	High ('treatment of choice')	–
Use of curettage ± electrodesiccation	Recommendation for low-risk tumors	Recommendation for low-risk tumors	Curettage and cautery is not indicated in recurrent or high-risk non-melanoma skin cancer	–	–
Radiotherapy of the primary tumor or post-operatively	–	Radiation therapy (in selected patients with contraindications to surgery, when surgery would be disfiguring, or when radiation therapy is needed for palliation) (LoE: moderate, strength: strong) Adjuvant radiation therapy may be added to the surgical treatment of high-risk SCCs, such as those with perineural invasion. (moderate LoE, weak strength)	–	Adjuvant or post-operative radiation therapy should be considered in cSCC with substantial perineural involvement, or in incompletely excised tumors where further surgery is not possible or unlikely to completely eradicate the tumor	Adjuvant or postoperative radiotherapy should be taken into account in the case of (i) cSCCs with perineural involvement and (ii) not tumor-free tissue margins subsequent to surgical excision, and when further surgical procedures cannot be performed or is unlikely to lead to complete removal of the tumor
Performance and indication of sentinel lymph node biopsy					
When should an SLNB be performed?	–	SLNB may be offered as an optional procedure to a selected high-risk population after discussion with a multidisciplinary team	–	Unclear ('no conclusive data on the use of SLNB and its prognostic information or possible therapeutic value in the treatment of high risk cSCC')	Unclear ('no satisfactory data has been made available')

Table 1 Continued

Clinical scenarios/Key questions	US 2018	Canada 2015	UK 2016	Europe 2015	Italy/ Europe 2018
Management of nodal metastases					
Performance of regional dissection if lymph node metastasis were detected.	Surgical resection, with or without adjuvant radiation therapy and possible systemic therapy are recommended for regional lymph node metastases (IB)	—	—	—	—
Adjuvant radiotherapy following the dissection	—	—	<ul style="list-style-type: none"> • P+ N0 disease: Resection should include involved parotid tissue, combined with levels I–III neck dissection, to include the external jugular node • P+ N+ disease: Resection should include level V if that level is clinically or radiologically involved, adjuvant RT should include level V if not dissected • P0 N+ disease: Anterior neck disease should be managed with a levels I–IV neck dissection to include the external jugular node • P0 N+ Posterior echelon nodal disease (i.e. occipital or post-auricular) should undergo dissection of levels II–V, with sparing of level I • Consider treatment of the ipsilateral parotid, if the primary site is the anterior scalp, temple or forehead 	<p>In the case of lymph node involvement by cSCC, the preferred treatment is a regional lymph node dissection followed by adjuvant radiotherapy in cases where multiple nodes are affected or if extracapsular involvement is observed</p>	<p>In the case of lymph node involvement by cSCC, the recommended treatment is loco-regional lymph node dissection</p>
Management of advanced cSCC					
Inoperability of the primary tumor	Combination chemoradiation therapy should be considered for inoperable disease (IB)	—	—	—	—
					Radiotherapy is a valid alternative to surgery in the non-surgical treatment of small cSCCs in low-risk areas and in general, it should be considered as both a primary treatment option for inoperable cSCCs and the first adjuvant treatment option

Table 1 Continued

Clinical scenarios/Key questions	Recommendation	US 2018	Canada 2015	UK 2016	Europe 2015	Italy/Europe 2018
Systemic interventions in metastatic disease	Epidermal growth factor inhibitors and cisplatin, as a single agent or in combination therapy, may be considered, as they have demonstrated efficacy for metastatic disease, albeit on the basis of limited data (B I, II)					
					Mono- or poly-chemotherapy can be used in metastatic cSCC; however, there is no established standard regimen and responses are usually short-lived. Targeted therapies, such as EGFR inhibitors, either in combination with chemotherapy or in the neoadjuvant setting, have shown encouraging results in locally advanced or metastatic cSCC and their use is encouraged in the setting of clinical trials	

cSCC, cutaneous squamous cell carcinoma; LoE, level of evidence; P+, involvement of the parotid gland; N+, lymph node disease.

Management of the primary tumour site

An important question on the management of the primary tumour site is how high-risk tumours should be treated surgically in contrast to low-risk ones. One possibility is excision with subsequent conventional histological processing of the specimen in the bread loaf technique or with postoperative margin assessment. These methods were mentioned for high-risk cSCC in all five guidelines, but evaluated differently, as the strength of the recommendation varied from high ('treatment of choice')¹² to low ('may be considered').¹⁰ In four of five of the analyzed guidelines, safety margins for excision were specified. For high-risk tumours, they were recommended to be at least 6 mm throughout all guidelines (>6 mm¹³; 6–13 mm¹¹; >10 mm¹²; 10 mm¹⁴). Removal by Moh's micrographic surgery with a complete examination of the margins was recommended and classified as a method of choice for high-risk tumours in three guidelines.^{10–12} In contrast, the UK guideline made only a weak recommendation for Moh's ('has a role in some high-risk cSCC'), and only after discussion in a multidisciplinary setting.¹³ The use of curettage with or without electrodesiccation was explicitly discouraged in one guideline and not considered indicated in recurrent or high-risk cSCC.¹³ Similarly, two other guidelines recommended this procedure for low-risk tumours only.^{10,11} Postoperative radiotherapy was unanimously recommended in three guidelines if the resection status is incomplete and complete removal of the tumour cannot be achieved with surgery for functional or anatomic reasons. Furthermore, three guidelines made an explicit recommendation for postoperative radiotherapy in case of perineural invasion.^{11,12,14}

Performance and indication of sentinel lymph node biopsy

As the next relevant clinical question, we analyzed the recommendations for performing SLNB. In two of five guidelines, the topic was discussed but no specific recommendations were given. The authors stated that the significance of performing SLNB was either unknown or that the procedure was only used within studies and had no role in routine clinical care.^{10,13} Two studies included recommendations that did not represent a concrete mandate for action and should therefore be regarded as statements. They concluded that there was either no or only inconclusive data regarding the indication for SLNB.^{12,14} One guideline recommended SLNB as an optional procedure that may be offered to a selected high-risk population after discussion in a multidisciplinary team.¹¹ However, the strength of this recommendation was weak ('may be considered') and the level of evidence low.¹¹ Overall, the indication for SLNB even in the high-risk situation was poorly characterized and no specific criteria were proposed for the decision to perform (or not) SLNB. This uncertainty may be due to the lack of evidence regarding this scenario and contrasts sharply with other skin cancer entities such as melanoma and Merkel cell carcinoma where the role of SLNB is by far better established.

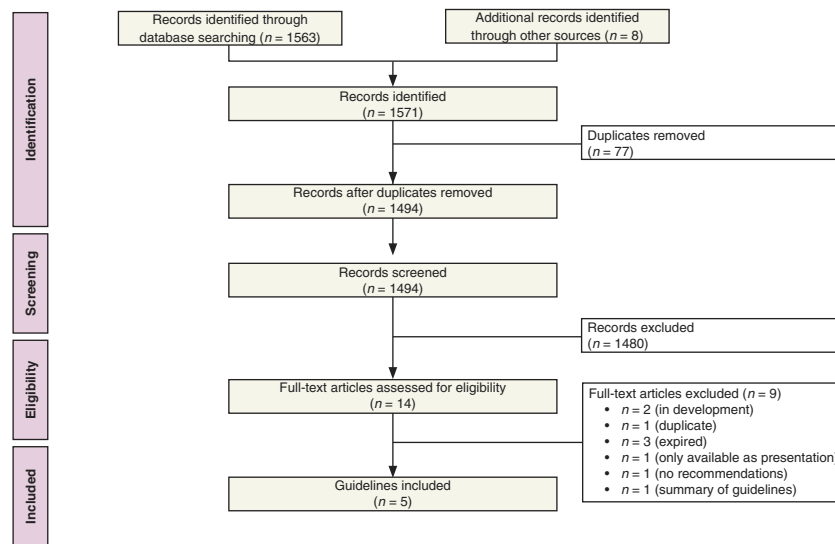


Figure 1 PRISMA flowchart of the study. Selection process for study inclusion in the systematic review according to the Preferred Reporting Items for Systematic Reviews and Meta-Analysis (PRISMA).

Management of nodal metastases

In the presence of loco-regional metastases of cSCC, unequivocal recommendations were identified in most guidelines. Four of five studies strongly recommended a complete dissection of regional lymph nodes in case of detection of metastasis.^{10,12–14} Moreover, two guidelines recommended adjuvant radiotherapy following complete dissection,^{10,12} if multiple lymph nodes were affected or extracapsular tumour growth was detected.¹³ If the parotid gland was affected by metastasis, a parotidectomy was explicitly recommended in two guidelines.^{13,14} The strength of the recommendation was consistently high ('recommended treatment'^{10,12,14}; 'should be performed'¹³).

Management of advanced cSCC

Advanced cSCC was defined as locally unresectable disease or as metastatic spread to distant organs. If the primary tumour cannot be removed surgically due to its extent or in case of contraindications to surgery, two guidelines mentioned primary radiotherapy as an alternative with a medium strength of recommendation ('should be considered').^{10,11} The US guideline suggested a combination of chemotherapy as 'chemoradiation' for inoperable disease.¹⁰ For metastatic (stage IV) disease, three of five guidelines did not make a specific recommendation.^{11,13,14} One study emphasized the role of cisplatin and inhibitors of the epidermal growth factor receptor (EGFR), either as a single agent or as combination therapy.¹⁰ However, the strength of recommendation was low ('may be considered') and only limited data were available to support this statement.¹⁰ Similarly, the European guideline stated that mono- or poly-chemotherapy can be used in metastatic cSCC,

although responses are usually short-lived and no standard regimen exists. The use of EGFR inhibitors was encouraged in clinical trials in this guideline.¹²

Discussion and concluding remarks

In this comparative analysis, we systematically searched for published guidelines on cSCC and evaluated the treatment recommendations for high-risk and advanced disease for defined clinical scenarios. A major limitation was the fact that the guidelines used different approaches to rate the level of evidence and to make treatment recommendations, limiting the cross-guideline comparability. Nevertheless, all studies uniformly recommended excision of high-risk primary tumours with a safety margin of at least 6 mm or with Moh's micrographic surgery. However, it remains unclear from our analysis whether and when SLNB should be performed. Thus, in patients with high-risk features, the decision to perform an SLNB remains to be discussed individually and the lack of evidence should be explicitly addressed. Interestingly, recommendations for advanced cSCC were found in only two of the included guidelines.^{10,12} The strength of the recommendation was low, underlining that the treatment options are limited in this situation. None of the guidelines mentioned the use of immune checkpoint blockade in metastatic disease, which has most recently shown encouraging results in various studies.^{16–18} Inhibitors of PD-1 such as pembrolizumab or nivolumab may be applied off-label, while cemiplimab was approved for metastatic cSCC in the US and in Europe based on a phase II trial.^{19–22} In this context, NICE has published their recommendation to reimburse cemiplimab for this indication.² We hypothesize that these agents will

significantly improve the prognosis and change the standard of care for advanced cSCC. We conclude that national and international treatment guidelines should be updated and make specific recommendations for the use of checkpoint blockade in advanced cSCC.

References

- 1 Arbeitsgemeinschaft der Wissenschaftlichen Medizinischen Fachgesellschaften (AWMF). Aktinische Keratose und Plattenepithelkarzinom der Haut: Registernummer 032 – 022OL. 2019. URL <https://www.awmf.org/leitlinien/detail/Anmeldung/1/II/032-022OL.html> (last accessed: 14 April 2019).
- 2 National Institute for Health and Care Excellence. Cemiplimab for treating cutaneous squamous cell carcinoma [ID1367]. 2019. URL <https://www.nice.org.uk/guidance/indevelopment/gid-ta10304> (last accessed: 14 April 2019).
- 3 European Dermatology Forum. Guideline on the diagnosis and treatment of invasive squamous cell carcinoma of the skin. 2015. URL http://www.turkderm.org.tr/turkdermData/Uploads/files/GuidelineonSquamousCellCarcinoma_S2%20.pdf (last accessed: 14 April 2019).
- 4 Breuninger H, Eigentler T, Bootz F et al. Brief S2k guidelines – cutaneous squamous cell carcinoma. *J Dtsch Dermatol Ges* 2013; **11**: 37–45.
- 5 Bonerandi JJ, Beauvillain C, Caquant L et al. Guidelines for the diagnosis and treatment of cutaneous squamous cell carcinoma and precursor lesions. *J Eur Acad Dermatol Venereol* 2011; **25**(Suppl 5): 1–51.
- 6 Cancer Council Australia and Australian Cancer Network. Basal Cell Carcinoma, Squamous Cell Carcinoma (and Related Lesions): A Guide to Clinical Management in Australia. Cancer Council Australia and Australian Cancer Network, Sydney, NSW, 2008. https://www.cancer.org.au/content/pdf/HealthProfessionals/ClinicalGuidelines/Basal_cell_carcinoma_Squamous_cell_carcinoma_Guide_Nov_2008-Final_with_Corrigenda.pdf (last accessed 14 April 2019).
- 7 National Comprehensive Cancer Network. NCCN Clinical Practice Guidelines in Oncology (NCCN Guidelines): Squamous Cell Cancer. 2016. URL https://www.nccn.org/store/login/login.aspx?ReturnURL=https://www.nccn.org/professionals/physician_gls/pdf/squamous_blocks.pdf (last accessed: 22 March 2016).
- 8 Wang HR, McLellan B, Ciocon D, Amin B, Goldenberg D, Schmalbach CE. AHNS series – do you know your guidelines? Diagnosis and management of cutaneous squamous cell carcinoma. *Head Neck* 2016; **38**: 1589–1595.
- 9 Kauvar AN, Arpey CJ, Hruza G, Olbricht SM, Bennett R, Mahmoud BH. Consensus for nonmelanoma skin cancer treatment, part II: squamous cell carcinoma, including a cost analysis of treatment methods. *Dermatol Surg* 2015; **41**: 1214–1240.
- 10 Alam M, Armstrong A, Baum C et al. Guidelines of care for the management of cutaneous squamous cell carcinoma. *J Am Acad Dermatol* 2018; **78**: 560–578.
- 11 Sapijaszko M, Zloty D, Bourcier M, Poulin Y, Janiszewski P, Ashkenas J. Non-melanoma skin cancer in Canada chapter 5: management of squamous cell carcinoma. *J Cutan Med Surg* 2015; **19**: 249–259.
- 12 Stratigos A, Garbe C, Lebbe C et al. Diagnosis and treatment of invasive squamous cell carcinoma of the skin: European consensus-based interdisciplinary guideline. *Eur J Cancer* 2015; **51**: 1989–2007.
- 13 Newlands C, Currie R, Memon A, Whitaker S, Woolford T. Non-melanoma skin cancer: United Kingdom National Multidisciplinary Guidelines. *J Laryngol Otol* 2016; **130**: S125–S132.
- 14 Peris K, Alaibac M, Argenziano G et al. Cutaneous squamous cell carcinoma. Italian guidelines by SIDeMaST adapted to and updating EADO/EDF/EORTC guidelines. *G Ital Dermatol Venereol* 2018; **153**: 747–762.
- 15 Paleri V, Roland N. Introduction to the United Kingdom National Multidisciplinary Guidelines for head and neck cancer. *J Laryngol Otol* 2016; **130**: S3–S4.
- 16 Soura E, Chasapi V, Stratigos AJ. Programmed cell death protein-1 inhibitors for immunotherapy of advanced nonmelanoma skin cancer: showing early promise. *Br J Dermatol* 2016; **175**: 1150–1151.
- 17 Blum V, Muller B, Hofer S et al. Nivolumab for recurrent cutaneous squamous cell carcinoma: three cases. *Eur J Dermatol* 2018; **28**: 78–81.
- 18 Oliveira LJC, Gongora ABL, Barbosa FG et al. Atypical response with bone pseudoprogression in a patient receiving nivolumab for advanced cutaneous squamous cell carcinoma. *J Immunother Cancer* 2018; **6**: 130.
- 19 Migden MR, Rischin D, Schmults CD et al. PD-1 blockade with cemiplimab in advanced cutaneous squamous-cell carcinoma. *N Engl J Med* 2018; **379**: 341–351.
- 20 Miller DM, Faulkner-Jones BE, Stone JR et al. Complete pathologic response of metastatic cutaneous squamous cell carcinoma and allograft rejection after treatment with combination immune checkpoint blockade. *JAAD Case Rep* 2017; **3**: 412–415.
- 21 Stevenson ML, Wang CQ, Abikhair M et al. Expression of programmed cell death ligand in cutaneous squamous cell carcinoma and treatment of locally advanced disease with pembrolizumab. *JAMA Dermatol* 2017; **153**: 299–303.
- 22 Degache E, Crochet J, Simon N et al. Major response to pembrolizumab in two patients with locally advanced cutaneous squamous cell carcinoma. *J Eur Acad Dermatol Venereol* 2018; **32**: e257–e258.

Supporting information

Additional Supporting Information may be found in the online version of this article:

Table S1. Overview of the guideline databases searched for ‘squamous cell carcinoma’ and ‘Plattenepithelkarzinom’.

Table S2. Overview of the search strategy in Medline and Embase via Ovid.