

HIV-1 Infection of the Central Nervous System

Clinical, Pathological, and Molecular Aspects

edited by

Serge Weis and Hanns Hippius (Eds.)



Hogrefe & Huber Publishers
Seattle · Toronto · Göttingen · Bern

TABLE OF CONTENTS

Preface	V
Table of contents	VII
Contributors	IX
HIV-1 related central nervous system manifestations	
<i>K.M. Einhüpl, E. Schielke, in cooperation with H.W. Pfister</i>	1
Magnetic resonance evaluation of the brain in HIV-1 infection: present status and perspectives	
<i>A. Villringer, E. Schielke, C. Trenkwalder, K.M. Einhüpl</i>	17
Cerebral blood flow and metabolism in HIV-1 infection	
<i>E. Schielke, K.M. Einhüpl</i>	39
Neuroendocrine changes in HIV-1 Infection	
<i>A.A. Möller, M. Oechsner, C. Nerl</i>	51
Neuropsychological deficits and other psychiatric symptoms in HIV-1 infected patients	
<i>D. Naber, C. Perro, E. Schielke, F.D. Goebel, H. Hippus</i>	67
Predictors of neurocognitive decline with progression to symptomatic HIV-1 infection	
<i>O.A. Selnes</i>	87
Immune activation, impaired tryptophan metabolism, and neurologic/psychiatric symptoms in HIV infection	
<i>D. Fuchs, A.A. Möller, G. Weiss, M.P. Dierich, H. Wachter</i>	103
Ocular involvement in HIV-1 infection: neuroophthalmological aspects	
<i>V. Klauf, S.A. Geier, A. Mueller, A. Mutsch</i>	121
Involvement of endothelins, peptides with potent vasoactive properties, in HIV-1 encephalopathy	
<i>F.D. Goebel, B. Rolinski, P. Rieckmann, F. Sinowatz, S. Geier, K.A. Clouse, U. Kronawitter, J.R. Bogner, V. Klauf, H. Ehrenreich</i>	147
Neuropathological features of the brain in HIV-1 infection	
<i>S. Weis, K. Bise, I.C. Llenos, P. Mehraein</i>	159
Stereotactic biopsy of focal intracerebral lesions in AIDS patients: results and diagnostic yield	
<i>W. Feiden, P. Mehraein, K. Bise, U. Steude, H.W. Pfister, A.A. Möller</i>	191

Morphometric aspects of the brain in HIV-1 infection <i>S. Weis</i>	199
The reactive microglial cell: involvement in diseases of the nervous system with special reference to the acquired immune deficiency syndrome (AIDS) <i>J. Gehrman, R.B. Banati, G.W. Kreutzberg</i>	225
Amelioration of HIV-1 related neuronal injury by Ca ²⁺ channel antagonists and N-methyl-D-aspartate (NMDA) antagonists <i>S.A. Lipton</i>	251
Biological and molecular characterization of HIV-1 isolates from blood and Cerebrospinal fluid. <i>F. Chiodi</i>	261
Infection of the central nervous system by HIV-1: target cells and mechanism of viral replication <i>V. Erfle, B. Kohleisen, K. Gaedigk-Nitschko, A. Kleinschmidt, T. Werner, M. Neumann, A. Ludvigsen, R. Herrmann, T. Görblich, R. Brack-Werner</i>	281
DNA sequence analysis identifies regions likely responsible for neurotropism of HIV-1 <i>A. Rolfs, I. Weber, B. Heidrich</i>	307
Index	329

INVOLVEMENT OF ENDOTHELINS, PEPTIDES WITH POTENT VASOACTIVE PROPERTIES, IN HIV-1 ENCEPHALOPATHY

F.D. GOEBEL¹, B. ROLINSKI¹, P. RIECKMANN², F. SINOWATZ³, S. GEIER⁴,
K.A. CLOUSE⁵, U. KRONAWITTER¹, J.R. BOGNER¹, V. KLAUß⁴, H. EHRENREICH⁵

1 Medizinische Poliklinik, University of Munich, Munich, Germany

2 Departments of Neurology and Psychiatry, University of Göttingen, Göttingen, Germany

3 Institute of Veterinary Anatomy II, University of Munich, Munich, Germany

4 Department of Ophthalmology, University of Munich, Munich, Germany

5 Center for Biologics Evaluation and Research, FDA, Bethesda, MD, USA

Introduction

Endothelins are a family of potent vasoconstrictor peptides originally isolated from porcine aortic endothelial cells (26). They have subsequently been found to be produced by a number of other cell types including epithelial cells, certain populations of neurons, and glial cells (1,4,12,18). Since their identification in monocytes/macrophages and mast cells, they have been considered to be cytokines (3,6). The regulation of endothelin secretion differs considerably among cell types. This different regulation seems to represent important aspects of endothelin biology. Thus, auto-/paracrine mechanisms apparently play a major role in the activity of these peptides (5,13). Monocytes and mast cells respond to environmental stimuli like bacterial lipopolysaccharide or antigen-triggered IgE with an increase in endothelin secretion (3,6). Other cell types, e.g. smooth muscle cells or glial cells, can be induced in an autostimulatory fashion to potentiate their endothelin production (5,13). This autoregulatory amplification can lead to high local levels of these peptides, as has been shown for instance in lung tissue of patients suffering from allergic asthma (22). These findings are of particular relevance with respect to the extremely potent and long lasting smooth muscle constricting properties of these peptides as well as to their mitogenic actions in various cell types (23,24).

Invasion of the brain by monocytes/macrophages and subsequent formation of multinu-

cleated giant cells as well as astrocytic gliosis are prominent features of HIV-1 encephalopathy (14,15,16,20). Clinical and pathological observations pointing to an involvement of cerebral blood vessels in this condition (8,17,19) are for example: fluctuating neuropsychiatric symptoms, abnormal findings in single photon emission computed tomography (SPECT) and positron emission tomography (PET) analyses even in asymptomatic HIV-seropositive individuals, thickening of medium sized and small vessels, vascular calcifications, particularly in children with AIDS, a relatively high incidence of unexplained transient ischemic attacks and cerebral infarctions, reversibility of neurological symptoms upon AZT-treatment in some patients, and, finally, cerebral atrophy similar to the one observed in multiinfarct dementia (14, 15,20). We hypothesize that macrophage-derived endothelins, by virtue of their potent vasoconstricting activities that can affect cerebral blood vessels of all sizes and types (27), might cause these primarily functional vascular disturbances.

In an attempt to elucidate the role of endothelins in HIV-1 encephalopathy, different experimental approaches were chosen. Using immunohistochemistry, we investigated brain sections of HIV-1 infected individuals for the presence and distribution of endothelin immunoreactivity. In order to extend this study to a larger number of patients and to assess whether histological findings with endothelins might be reflected by cerebrospinal fluid levels of these peptides, we measured the endothelin-1 concentrations together with other indicators of macrophage activation in the cerebrospinal fluid of HIV-1 infected patients at different disease stages. As vascular involvement in general seems to be a frequent phenomenon in HIV-1 infection, we further determined endothelin-1 concentrations in the plasma of HIV-1 infected patients with and without clinical evidence of microcirculatory dysfunction.

Immunohistochemistry of Brain Sections

Brain tissue was obtained upon autopsy from three HIV-1 infected patients. Autopsy was performed within 24 hours. All patients had clinical evidence of HIV-1 encephalopathy. Other reasons for neurological dysfunction were widely excluded; especially, indication of opportunistic infections or malignancies of the central nervous system was not present.

Paraffin sections of the frontal lobe were incubated with an antiserum against endothelin-1 (Peninsula Laboratories, Belmont, California, USA) and processed for second antibody-immunoperoxidase staining. Cell nuclei were counterstained with hematoxylin. A representative brain section is shown in Fig. 1. A large number of cells stained distinctly positive for endothelin-1. These cells were identified as macrophages by staining consecutive sections for CD68, a macrophage-specific marker (not shown). Macrophages were not present in the cerebral tissue of healthy controls. Moreover, in HIV-1 infected individuals there was a much higher percentage of cerebral microvessel endothelial cells displaying endothelin immunoreactivity as compared to normal brain.

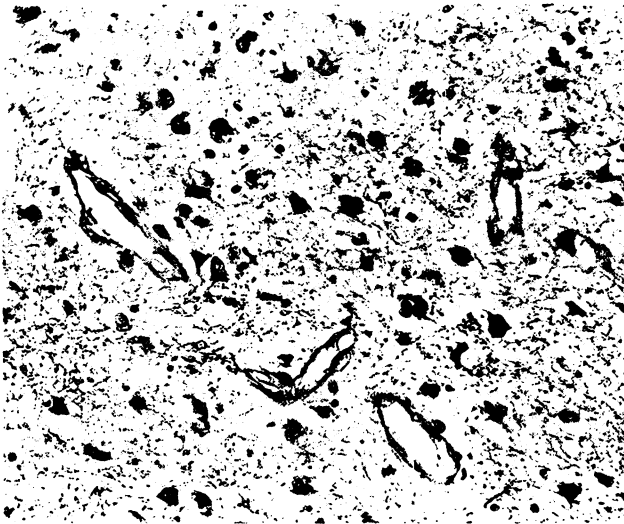


Figure 1: Macrophages and microvascular endothelial cells in the brain of patients with HIV-1 encephalopathy stain positively for endothelins. Frontal lobe tissue was obtained upon autopsy from a patient with HIV-1 encephalopathy without indications of opportunistic infections of the central nervous system. Paraffin sections were processed for immunoperoxidase staining using an antiserum specific for endothelin-1. Cell nuclei were counterstained with hematoxylin. Consecutive sections, stained for CD68, a macrophage-specific marker, identified endothelin positive cells as macrophages (not shown).

Macrophage-Activation Markers and Endothelin in Cerebrospinal Fluid of HIV-1 Infected Patients

In order to assess whether the histological findings of endothelin immunoreactive macrophages in the brain of HIV-1 infected patients might be reflected by altered levels of these peptides in an accessible compartment of the brain, we measured immunoreactive endothelin-1 in the cerebrospinal fluid of HIV-1 infected patients at different disease stages as well as in healthy controls. In addition, the assays of neopterin and $\beta 2$ -microglobulin, established markers of macrophage activation, were determined to correlate endothelin levels with macrophage activation.

The normal range of the three parameters under our assay conditions was established using cerebrospinal fluid obtained from 10 neurologically healthy patients undergoing spinal anaesthesia for a variety of reasons. A total of 114 HIV-1 infected patients were investigated. Staging was performed according to the Walter Reed (WR) classification system. Nine patients were in WR1, 15 in WR2, 10 in WR3, 12 in WR4, 22 in WR5, and 46 in WR6. Cerebrospinal fluid was obtained from the patients undergoing lumbar puncture for diagnostic purposes after informed consent. Neopterin was measured by a radioimmunoassay (Henning, Berlin, Germany) and $\beta 2$ -microglobulin by an enzyme-linked-immuno-sorbent-assay (Behring, Marburg, Germany). The assay for endothelin consisted of a simultaneous sample clean-up and concentration step on C18-extraction cartridges according to (7), followed by a radioimmunoassay (Amersham, Braunschweig, Germany). For endothelin determination, as much as 2.0 ml of CSF is usually needed to give reproducible results. Therefore, endothelin levels could not be analysed in all patients.

The macrophage activation markers neopterin and $\beta 2$ -microglobulin were significantly elevated in HIV-1-infected patients as compared to controls (2). This was true for all disease stages. Interestingly, we noted a biphasic curve with a smaller peak in WR2 and a large increase in WR6 (Fig.2). A similar biphasic pattern with disease progression was observed for endothelin-1. The endothelin-1 elevation in the early WR stages was not significant as compared to controls. In WR 5 and 6, however, endothelin-1 levels exceeded the normal

range significantly. The kinetics of cerebrospinal fluid endothelin levels during disease progression, which parallel those obtained for neopterin and $\beta 2$ -microglobulin, suggest a close correlation between the degree of activation of cerebral macrophages and endothelin concentrations in cerebrospinal fluid of HIV-1 patients.

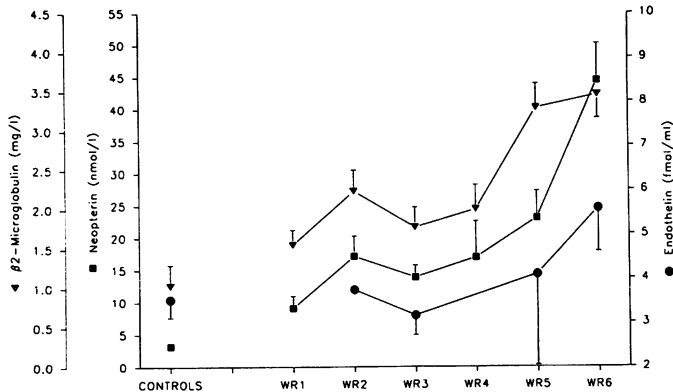


Figure 2: Endothelin, neopterin and $\beta 2$ -microglobulin increase in a biphasic pattern with disease progression in cerebrospinal fluid of HIV-1 infected patients. Values represent mean \pm standard deviation of a total of 114 patients. Distribution in Walter Reed (WR) stages is mentioned in the text. The respective scales as well as the respective normal values are indicated on the left and right side.

Plasma Endothelin Concentration and Vascular Disease in HIV-1 Infection

Microangiopathy of the retina comparable to that seen in diabetes mellitus or other vascular disorders is a phenomenon also encountered in HIV-1 infection. These ocular circulatory deficiencies are often accompanied by an impairment of cerebral perfusion as assessed by HMPAO-SPECT (technetium-99m-hexamethyl-propyleneamine oxime single photon emission computed tomography of the brain) (11). To elucidate a possible role of endothelins in these functional vascular disturbances, we measured endothelin-1 concentrations in the plasma of HIV-1 infected patients. A total of 63 subjects was investigated, 13 in WR 1 and 2, 13 in WR 3 and 4, and 37 in WR 5 and 6. Eight out of the 63 patients had Kaposi sarcoma and 11 had HIV-1 related neurological dysfunction (AIDS dementia complex), but no evidence

of opportunistic infections of the central nervous system. Thirty-seven out of the 63 patients could be investigated by funduscopy. Fourteen of these 37 subjects had evidence of microangiopathy.

Normal values were established from 13 healthy volunteers. For endothelin determination in the plasma, the extraction method was modified (Rolinski, in preparation). The radioimmunoassay used for plasma determinations was obtained from New England Nuclear/Dupont (Dreieich, Germany). The average endothelin-1 concentration in the 63 HIV-1 infected patients was significantly elevated as compared to controls (3.14 ± 1.27 vs 2.72 ± 0.67 fmol/ml, $p < 0.05$). In contrast to the biphasic pattern of endothelin levels observed in the cerebrospinal fluid, plasma concentrations displayed a steady increase with disease stage - from 2.49 ± 0.68 fmol/ml in WR 1/2 to 3.07 ± 1.38 and 3.61 ± 1.2 fmol/ml in WR 3/4 and WR 5/6, respectively (Fig. 3). The difference between WR 1/2 and 5/6 was statistically significant ($p < 0,01$).

Interestingly, HIV-1 infected patients with funduscopically confirmed microangiopathy had significantly higher plasma levels of endothelin-1 as compared to HIV-1 infected patients without microangiopathy (4.02 ± 1.05 vs 2.98 ± 0.96 fmol/ml, $p < 0.003$) or to controls ($p < 0.001$)(Fig.4). Similarly, patients with HIV-1 related neurological dysfunction had significantly increased plasma concentrations as compared to all other HIV-1 infected patients (3.69 ± 1.00 vs 2.99 ± 1.13 fmol/ml, $p < 0.05$). In the groups of patients with microangiopathy or neurological AIDS there was a higher incidence of advanced disease (WR 5 and 6). This fact, however, is unlikely to fully account for the differences found since patients with Kaposi sarcoma, all in WR 5 and 6, did not have significantly increased endothelin levels as compared to all other HIV-1 infected patients (3.59 ± 0.74 vs 3.15 ± 1.29 fmol/ml, n.s.).

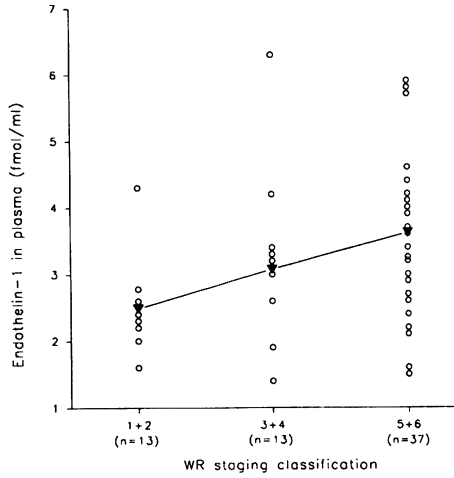


Figure 3: Endothelin concentration in the plasma increases with disease progression. Scattergrams and mean value of plasma levels of a total of 63 patients are shown. Values in Walter Reed stages 5 and 6 are significantly higher than those in WR 1 and 2 ($p < 0.01$).

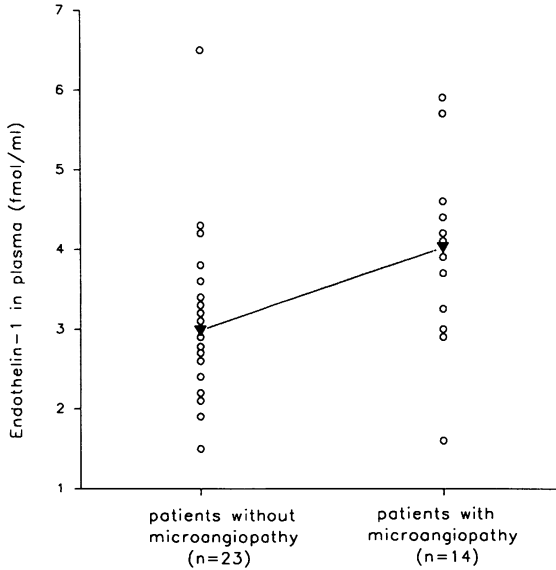


Figure 4: Endothelin concentration in plasma is elevated in HIV-1 infected patients with ocular microangiopathy. Scattergrams and mean values of plasma levels of a total of 37 patients are shown. The difference is statistically significant ($p < 0.003$).

Conclusions

Taken together, our data suggest that cerebral and ocular vascular disease in HIV-1 infection might be related to high levels of endothelins. It is unclear at present whether the enhanced levels in cerebrospinal fluid and plasma are caused by an increased production or a reduced elimination of endothelins or by both mechanisms. Nevertheless, the varying pattern of endothelin elevation in the plasma and cerebrospinal fluid with disease progression raises the questions whether a regular connection between the two compartments, cerebrospinal fluid and plasma, exists with respect to endothelins in HIV-1 infection.

Interestingly, recent data from our laboratories show that there is a distinct expression of the endothelin-1 gene in monocytes isolated from the peripheral blood of HIV-1 seropositive individuals which cannot be observed in healthy controls or in patients with multiple sclerosis, systemic lupus erythematosus or with common cold. It should be emphasized, however, that enhanced transcription of the endothelin-1 gene in these cells most likely reflects a general state of monocyte activation which is not specific for HIV-1 infection. Nevertheless, monocytic endothelins in HIV-1 infection may contribute to the observed increased plasma levels. In addition, monocytes recruited to the brain may release high amounts of endothelins. In concert with other cytokines such as $\text{TNF}\alpha$ and IL-6, which are apparently involved in HIV-1 encephalopathy (9,10,21,25), these potent vasoconstrictors are likely to amplify functional impairment and tissue damage in this condition.

Acknowledgements

We thank B.Röttger and A.Vielhauer for the expert technical assistance, I.Lochner and Dr.I. Sadri for statistical analysis, and E.Kolbe for preparing the manuscript. The financial support for this investigation provided by the "Bundesministerium für Forschung und Technologie" (Grant FKZ BGA III-002-89/FVP) is gratefully acknowledged.

References

1. Black PN, Ghatei MA, Takahashi K et al.: Formation of endothelin by cultured airway epithelial cells.
FEBS Lett. 1989, 255, 129-132
2. Bogner JR, Junge-Hülsing B, Kronawitter U et al.: Expansion of neopterin and beta2-microglobulin in cerebrospinal fluid reaches maximum levels early and late in the course of HIV-infection.
Clin.Invest., 1992, in press
3. Ehrenreich H, Anderson RW, Fox CH et al.: Endothelins, peptides with potent vasoactive properties, are produced by human macrophages.
J.Exp.Med., 1990, 172, 1741-1748
4. Ehrenreich H, Kehl JH, Anderson RW et al.: A vasoactive peptide, endothelin-3, is produced by and specifically binds to primary astrocytes.
Brain Res., 1991a, 538, 54-58
5. Ehrenreich H, Anderson RW, Ogino Y et al.: Selective autoregulation of endothelins in primary astrocyte cultures: Endothelin receptor-mediated potentiation of endothelin-1 secretion.
New Biol., 1991b, 3, 135-141
6. Ehrenreich H, Burd PR, Rottem M et al.: Endothelins belong to the assortment of mast cell-derived and mast cell-bound cytokines.
New Biol., 1992a, 4, 147-156
7. Ehrenreich H, Lange M, Near KA et al.: Longterm monitoring of immunoreactive endothelin-1 and endothelin-3 in ventricular cerebrospinal fluid, plasma, and 24 h-urine of patients with subarachnoid hemorrhage.
Acta Neurochir., 1992b, in press
8. Engstrom JW, Lowenstein DH, Bredesen DD: Cerebral infarctions and transient neurologic deficits associated with acquired immunodeficiency syndrome.
Am.J.Med., 1989, 86, 528-532
9. Farrar WL, Korner M, Clouse KA: Cytokine regulation of human immunodeficiency virus expression.
Cytokine 1991, 3, 531-542
10. Gallo P, Frei K, Rordorf C et al.: Human immunodeficiency virus type I (HIV-1) infection of the central nervous system: an evaluation of cytokines in cerebrospinal fluid.
J.Neuroimmunol., 1989, 23, 109-116

11. Geier SA, Schielke E, Klauss V: Retinal microvasculopathy and reduced cerebral blood flow in patients with Acquired Immunodeficiency Syndrome, *Am.J.Ophthalmol.*, 1992, 113, 100-101
12. Giaid A, Gibson SJ, Ibrahim NBN et al.: Endothelin-1, an endothelium-derived peptide, is expressed in neurons of the human spinal cord and dorsal root ganglia. *Proc.Natl.Acad.Sci. USA*, 1989, 86, 7634-7638
13. Hahn AWA, Resink TJ, Scott-Burden T et al.: Stimulation of endothelin mRNA and secretion in rat vascular smooth muscle cells: a novel autocrine function. *Cell regul.*, 1990, 1, 649-659
14. Ho DD, Bredesen DE, Vinters HV et al.: The acquired immunodeficiency syndrome (AIDS) dementia complex (clinical conference). *Ann.Intern.Med.*, 1989, 111, 400-410
15. Johnson RT, McArthur JC, Narayan O: The neurobiology of human immunodeficiency virus infection. *FASEB J*, 1988, 2, 2970-2981
16. Koenig S, Gendelmann HE, Orenstein JM et al.: Detection of AIDS virus in macrophages in brain tissue from AIDS patients with encephalopathy. *Science*, 1986, 233, 1089-1093
17. LaFrance ND, Pearson G, Schaerf F et al.: SPECT imaging with I-123 isopropyl amphetamine in asymptomatic HIV seropositive persons. *Clin.Nuc.Med.*, 1988, 13, 393
18. MacCumber MW, Ross CA, Snyder SH: Endothelin in brain: Receptors, mitogenesis and biosynthesis in glial cells. *Proc.Natl.Acad.Sci. USA*, 1990, 87, 2359-2363
19. Pohl P, Vogl G, Fill H et al.: Single photon emission computed tomography in AIDS dementia complex. *J.Nucl.Med.*, 1988, 29, 1382-1386
20. Price RW, Brew B, Sidtis J et al.: The brain in AIDS: central nervous system HIV-1 infection and AIDS dementia complex. *Science*, 1988, 239, 586-592
21. Pulliam L, Herndier BG, Tang NM et al.: Human immunodeficiency virus-infected macrophages produce soluble factors that cause histological and neurochemical alterations in cultured human brains. *J.Clin.Invest.*, 1991, 87, 503-512
22. Springall DR, Howarth PH, Counihan H et al.: Endothelin immunoreactivity of airway

- epithelium in asthmatic patients.
Lancet, 1991, 337, 697-701
23. Supattapone S, Simpson AWM, Ashley CC: Free calcium rise and mitogenesis in glial cells caused by endothelin.
Biochem.Biophys.Res.Commun., 1989, 165, 1115-1122
 24. Takuwa N, Takuwa Y, Yanagisawa M et al.: A novel vasoactive peptide endothelin stimulates mitogenesis through inositol lipid turnover in swiss 3T3 fibroblasts.
J.Biol.Chem., 1989, 264, 7856-7861
 25. Wahl SM, Allen JB, McCartney-Francis N et al.: Macrophage- and astrocyte-derived transforming growth factor beta as a mediator of central nervous system dysfunction in acquired immunodeficiency syndrome.
J.Exp.Med., 1991, 173, 981-991
 26. Yanagisawa M, Kurihara H, Kimura S et al.: A novel potent vasoconstrictor peptide produced by vascular endothelial cells.
Nature, 1988, 332, 411-415
 27. Yanagisawa M, Masaki T: Molecular biology and biochemistry of the endothelins.
Trends Pharmacol.Sci., 1989, 10, 374