

Role of immune cells in the ocular manifestations of pemphigoid diseases

Tanima Bose 

Ther Adv Ophthalmol

2019, Vol. 11: 1–9

DOI: 10.1177/
2515841419868128

© The Author(s), 2019.
Article reuse guidelines:
sagepub.com/journals-
permissions

Abstract: Pemphigoid disease is classified according to the phenotypical location of the disease and the presence of different types of antibodies. The ocular distribution of pemphigoid mainly occurs in patients with bullous pemphigoid and mucous membrane pemphigoid. Several immune cells, including the cells of the innate immune system (neutrophils and $\gamma\delta$ T cells) and the adaptive immune system (T and B cells), are involved in pemphigoid disease. The treatment of pemphigoid is still wide-ranging, and the most utilized treatment is the use of immunosuppressants and corticosteroids. In this scenario, it is absolutely important to screen the immune cells that are involved in this group of diseases and to determine if a targeted treatment approach is plausible. In conclusion, this review will identify some newer treatment possibilities for the whole spectrum of pemphigoid diseases.

Keywords: ocular immunology, ocular pemphigoid disease, pemphigoid diseases, T cells

Received: 10 April 2019; revised manuscript accepted: 15 July 2019.

Introduction

Ocular cicatricial pemphigoid (OCP), which is also known as ocular mucous membrane pemphigoid (MMP), is a rare, chronic auto-immune disorder that mainly affects the conjunctiva, the extraocular mucous membranes, and, occasionally, the skin. Ocular involvement is the hallmark indication of OCP, and this ocular involvement is also associated with a poor prognosis. Although the exact cause of this disease is not clearly understood, due to the presence of auto-antibodies, it is presumed that this disease has an auto-immune cause.¹ OCP is a progressive disease, and it can result in blindness in the absence of proper timely treatments. Moreover, because OCP may be associated with extraocular manifestations, it is generally considered to be of medical importance.² The annual incidence of OCP has been estimated to range from 1 in 15,000 to 1 in 46,000 ophthalmic patients. OCP affects far more women than men, with an approximate ratio of 2:1, respectively. Both environmental and genetic factors seem to be important in determining OCP susceptibility; additionally, there is no evidence regarding racial or geographic predilections.^{3,4} Ocular involvement is frequently observed in OCP patients, with this involvement affecting

60–77% of the cases.^{5–7} Prognostically and therapeutically, the involvement of the eyes immediately classifies these patients as being a ‘high-risk’ group of MMP patients because of the vision-threatening consequences.² There are some events of extraocular involvement in OCP patients, with incidence rates reported as either 46–50% or as high as 82%.^{4,5,7} Red eyes and itchiness are two of the most common symptoms of OCP, which may be diagnosed as cicatricial conjunctivitis and ocular allergic disease in the initial stages. There are four stages in the modified Mondino–Foster staging system for the diagnosis of OCP, which consist of subconjunctival scarring and fibrosis, fornix foreshortening of any degree, the presence of symblepharon of any degree, ankyloblepharon, and frozen globe.⁸ Histological analyses of these patients have demonstrated an infiltration of different immune cells during the acute disease, including macrophages, dendritic cells and neutrophils (which are cells representing innate immunity), and auto-reactive T cells and increased levels of fibrogenic growth factors in the subepithelial stroma of the conjunctiva in OCP (which are cells and factors that represent adaptive immunity).^{9,10} For the systemic treatment of OCP, immunosuppressive drugs,

Correspondence to:
Tanima Bose
Institute for Clinical
Neuroimmunology,
Biomedicine Zentrum,
Ludwig Maximilian
University of Munich,
Grosshaderner Strasse
9, 82152 Planegg-
Martinsried, Munich,
Germany.
tanimabose@gmail.com
tanima.bose@med.uni-muenchen.de

such as methotrexate and azathioprine, are effective. In contrast, there is no specific therapy for OCP that only targets the ocular surface.^{1,11}

Definition and classification of pemphigoid diseases

Definition

According to the World Health Organization (WHO), bullous dermatosis diseases are characterized by the formation of multiple blisters in the epidermis and mucous membranes. Pemphigus, bullous pemphigoid, and dermatitis herpetiformis are three of the most prevalent auto-immune blistering diseases. Pemphigus is a group of auto-immune diseases that presents as blisters on the skin and mucous membranes. There are two well-known auto-antibodies against desmogleins 1 and 3, which cause acantholysis. The classification of pemphigoid diseases (PDs) also varies. Some PDs are classified based on the location of the disease, and some PDs are classified based on the antibodies that they produce. Regardless of the pemphigus subtype, auto-antibodies against the self-antigens can cause blisters (except for pemphigus foliaceus) and scabs in the epidermis.¹²⁻¹⁵

The most utilized treatment for this group of diseases is immunosuppressive drugs (such as mycophenolate mofetil and azathioprine) and corticosteroids (such as prednisone). In addition, steroids are prescribed in topical forms or are administered by injections (systemic steroids). The only first-line therapy for pemphigus is the use of rituximab, and it has been recently approved by the Food and Drug Administration (FDA) for the treatment of these conditions, in order to prevent new auto-antibodies from forming. Rituximab primarily targets CD20, and it is still recommended for the treatment of different auto-immune diseases and cancer.^{12,16-19} Thus, a targeted, specific therapy is still needed for the group of PDs.

Classification of PDs

The most traditional classification of PDs by the rare disease database is characterized as follows: (1) drug-induced pemphigus, (2) endemic pemphigus (fogo selvagem), (3) pemphigus erythematosus (Senear–Usher syndrome), (4) pemphigus foliaceus, (5) pemphigus vegetans, and (6) pemphigus vulgaris.²⁰⁻²² Figure 1 illustrates the

different types of PDs and their interplay with different immune cells.

Among these PD types, pemphigus vulgaris is the most common form of PD in the United States and involves the formation of lesions that are associated with the mucus membrane. Pemphigus vegetans is primarily associated with the skin fold areas (flexures), whereas the lesions are primarily associated with lupus and oil-producing glands (sebaceous glands), such as the cheeks, scalp, upper chest, and back. Pemphigus foliaceus is primarily associated with the upper layer of the epidermis, and little or nearly no involvement has been observed to be associated with the mucus membrane. However, the endemic form of pemphigus is observed in some rural pockets of the world, with incidences primarily observed in Central America and South America. Drug-induced pemphigus is associated with drugs used to treat blood pressure or heart failure conditions, such as the angiotensin-converting enzyme inhibitor captopril. In addition to this classification, there are pemphigoid-associated disorders, such as paraneoplastic pemphigus, IgA pemphigus, bullous pemphigoid (BP), MMP, pemphigoid gestationis (PG), linear IgA dermatosis (LAD), lichen planus pemphigoides (LPP), and anti-p200 pemphigoid. Among these disorders, the types that are associated with anti-BP180 autoreactivity are BP, PG, LAD, LPP, and a subgroup of MMP, and these types may form a continuous spectrum of subepidermal auto-immune blistering dermatoses.²³

Men and women are affected by pemphigus in equal numbers. Pemphigus is a rare disease, and the annual incidence is estimated to be 0.7–5 people per 10,000,000 people in the general population. The mean age of pemphigus onset is the fifth and sixth decades of life in most patients, and it is rarely reported in children. In contrast, the annual incidence of BP was reported to be between 4.5% and 14% in central Europe. Interestingly, there are some data describing an increased number of patients with BP in Germany and Great Britain during the last two decades. This increase is plausibly due to either the increasing age of the general population or to an increased awareness, or both, which may lead to further diagnostic steps. When regarding MMP and PG, these PD types are considered to be the second most frequent PDs in central Europe, with the yearly diagnosis rate estimated as two new patients/million patients.²⁴⁻²⁹

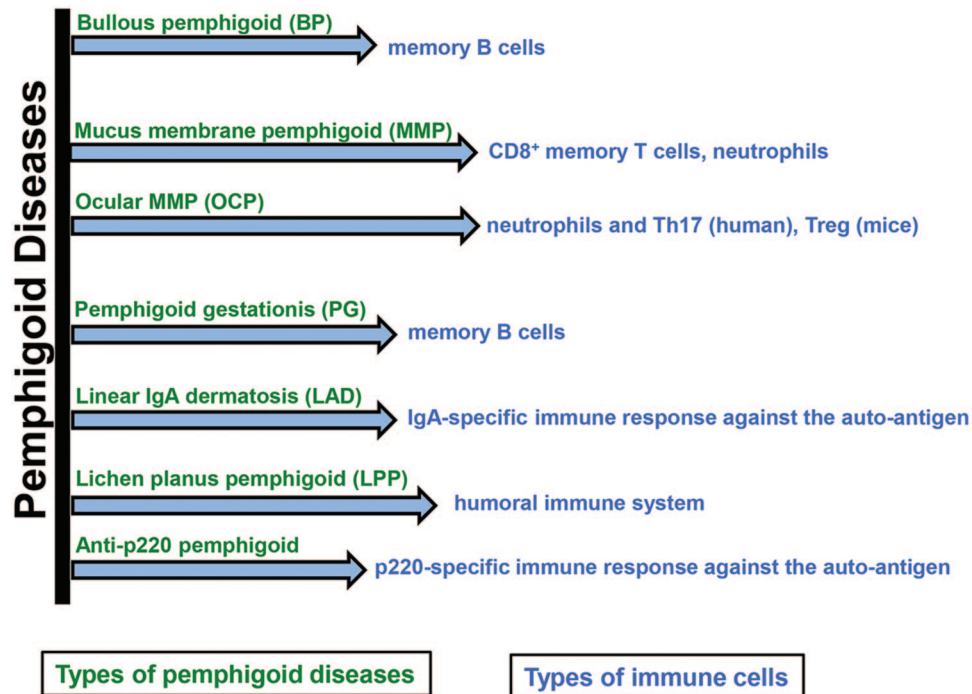


Figure 1. A description of the different immune cells in different types of pemphigoid disease. A combination of innate and adaptive immune systems plays an immense role in this type of disease. The cells that are primarily involved in the pathogenesis of PD include memory B cells and specialized T-helper cell subsets in the adaptive immune system, as well as neutrophils in the innate immune system. PD, pemphigoid disease.

Ocular manifestations

One of the major ocular manifestations for pemphigoid diseases is OCP, which is a subtype of MMP. Because of the presence of auto-antibodies, this subtype is considered to be auto-immune conjunctivitis, and it can lead to cicatrization scarring of the conjunctiva.³⁰ The annual incidence rate may be 1 in 12,000–60,000 people, according to the American Academy of Ophthalmology. It has been demonstrated that OCP represents 61% of cicatricial conjunctivitis cases, with an annual incidence rate of 1 person in 1 million people. OCP affects far more women than men, with an approximate ratio of 2:1, respectively.^{31,32} During the early stage of OCP is characterised by the clinical symptoms of the tearing, irritation, burning or mucus drainage. As it is a progressive disease, severe conjunctiva scarring and even vision loss are expected in the absence of proper treatment. OCP is not limited to ocular manifestations, and such patients could exhibit the involvement of other mucosal sites and, occasionally, the skin. There are different available treatments for OCP, including the use of corticosteroids and other immunosuppressants

as adjuvants. Such treatments aim to control disease activity but are not used to actually cure the disease.

The exact pathogenesis of OCP has remained largely unknown. However, there are some data that suggest a type II hypersensitivity response, which is caused by an auto-antibody to a cell surface antigen in the basement membranes of the conjunctiva epithelium and other similar squamous epithelia, may be responsible. Two auto-antibodies (anti-BP230 and anti-BP180) have been largely studied in BP patients, and these antibodies have also been detected in OCP patients. However, further investigations have revealed that the more likely auto-antigen is actually the $\beta 4$ subunit of the $\alpha 6\beta 4$ integrin of the hemidesmosomes. When regarding the genetic susceptibility of OCP, HLA-DR4 and HLA-DQB1*0301 alleles have been observed to be strongly associated with pemphigoid disease variants, particularly for OCP. HLA-DQB1*0301 is thought to bind to the $\beta 4$ subunit of the $\alpha 6\beta 4$ integrin (the suspected auto-antigen in OCP).^{33–38}

The involvement of inflammatory molecules in pemphigoid disease is also quite diverse. The prevalence of the cells of the innate immune system is more in comparison with the adaptive immune system. The associated cellular inflammatory infiltrates of the epithelium and the substantia propria manifest as chronic conjunctivitis, which is frequently observed in OCP patients. Eosinophils and neutrophils are the two key cells in OCP, and they cause inflammation in the early and acute phases of the disease. The chronic phase of the disease has a largely lymphocytic infiltration, and fibroblast activation leads to subepithelial fibrosis, which, in the early phase of the disease, appears as fine white striae. Other symptoms of the disease are conjunctival shrinkage, symblepharon formation, and forniceal shortening. Patients with severe conjunctival fibrosis are likely to develop entropion, trichiasis, and symblepharon, and the development of these conditions is usually followed by the development of keratopathy and corneal vascularization, scarring, ulceration, and epidermalization. OCP has a wide range of presentations, and there are varying degrees of disease severity. Recurrent inflammation causes a loss of Goblet cells and the obstruction of the lacrimal gland ductules, which then leads to deficiencies in aqueous and mucous tears. The resulting xerosis is severe, and an associated progressive subepithelial fibrosis and destruction of limbal stem cells lead to a limbal stem cell deficiency and ocular keratinization. Interleukin 1 (IL-1), tumor necrosis factor α (TNF α), migration inhibition factor (MIF), macrophage colony-stimulating factor (MCSF), and IL-13 have been demonstrated to be elevated in the conjunctival tissues of OCP patients. Among these cytokines, IL-13 not only has a pro-fibrotic effect but also has pro-inflammatory effects on conjunctival fibroblasts. These effects seem to indicate the development of progressive conjunctival fibrosis, which occurs despite clinical quiescence. Furthermore, tear samples of OCP patients have revealed elevated levels of IL-8, matrix metalloproteinase (MMP)-8, MMP-9, and myeloperoxidase (MPO), and this abundance of inflammatory molecules is associated with neutrophilic infiltration in these patients.^{30,31,39-44}

The propensity of immune cells in different OCP conditions

The spectrum of involvement of different immune cells is described in Figure 1.^{23,42,45-49} The two prominent cell populations that are modulated in

the pemphigoid diseases with ocular manifestations are neutrophils and T-helper (T_H) 17 cells in humans, and a coordinated, balanced mechanism between neutrophils and Tregs has been observed in mice. Ocular MMP is a rare disorder, with a minimum incidence rate estimated at approximately 0.8–1.6/million/year and a mean age of onset of 65 years. In contrast, this disorder may occur with a more aggressive phenotype in younger patients, with up to 30% of these patients not responding to immunomodulatory therapy and 40% of the patients demonstrating progressive conjunctival fibrosis in the absence of clinically detectable ocular surface inflammation, which invariably leads to a delayed diagnosis.⁵⁰⁻⁵² In the acute stage of the disease, the inflammatory process in ocular MMP is manifested as conjunctival inflammation that is characterized by redness, edema, limbitis, and pain to varying degrees. In this situation, clinicians rely on subjective clinical quantifications of disease activity and evaluate the signs of inflammation, such as redness and edema, and grade the signs of inflammation into none, mild, moderate, or severe scores, to monitor inflammation and to suggest the initiation of immunosuppressive therapy. In addition to this confusion, conjunctival scarring may progress even when the eye is not visibly inflamed. This phenomenon suggests that either there is a self-perpetuating fibrotic process in the absence of inflammation or, alternatively, there is a persistent inflammation that results in a progressive conjunctival fibrosis.⁵¹⁻⁵⁴

In the OCP condition, auto-antibodies against the hemidesmosome subunits [including epiligrin (subunit of laminin 5), BP230, and BP180] at the basement membrane zone (BMZ) cause the development of blisters. Consequently, these auto-antibodies lead to complement activation and the accumulation of inflammatory cells in the stroma.^{2,55,56} However, the family of CD4⁺ T cells that are involved in the process could be different subtypes of T_H lymphocytes, which produce some specific cytokines in large amounts when they become activated. One of the well-known T_H subtypes is the T_H1 cell, which is a source for interferon γ (IFN γ) and IL-2. T_H2 cells mainly produce IL-4, IL-5, and IL-13, which have also been described years ago. T_H17 cells, which are a relatively new subtype, are the main source for IL-17. This type of cell significantly contributes to tissue inflammation in different auto-immune diseases, such as inflammatory bowel disease, psoriasis, multiple sclerosis, systemic lupus erythematosus,

rheumatoid arthritis (RA), and Behçet's disease. Indeed, T_H17 cells are not only able to activate a wide range of inflammatory mediators and angiogenesis but also able to activate other immune cells, particularly neutrophils.^{57–64} The $CD4^+$ infiltrate is thought to be cells of the T_H2 cell phenotype, which are associated with the activation of transforming growth factor β (TGF β) and IL-13.^{40,65} In another paper, T_H17 cells have been demonstrated to help in the migration of immune cells to mucosal layers and to help in the production of different pro-inflammatory cytokines, which consequently regulates the mucosal immune response to tissue damage.⁴²

The mechanism in animal models seems to be slightly different, wherein there is a plausible connection between the adaptive and innate immune systems. The reason for this connection is due to the numbers of Tregs being higher in mice (60–80%), compared with humans (5–20%).^{66,67} PDs are caused by auto-antibodies, which target auto-antigens that are located in the skin layers. After the binding of the auto-antibody to the self-antigens, some immune cells and myeloid cells become active through the activation of Fc γ receptors. These cells bind to the skin-bound immune complexes (ICs), after which there is a release of reactive oxygen species (ROS) and proteases that results in skin inflammation and the development of subepidermal blisters.^{68–71} *Ex vivo* studies have demonstrated the critical roles of macrophages/monocytes⁷²; however, there are not enough data from *in vivo* studies. Another cell type is the mast cell, which seems to be required for BP development.⁷³ In addition to these cells, natural killer T (NKT) and $\gamma\delta$ T cells have been observed to be involved in the pathogenesis of this disease. Each of these cells is a source for TNF α , which can induce CD18 expression and CD62L shedding in the neutrophils.⁷⁴ Among the BP patients, a lack of Tregs and an increased number of T_H17 cells have been reported, compared with the healthy controls.^{75,76} Animal models for BP can allow researchers to distinguish the effects of regulatory and pro-inflammatory cells in each of the stages, with effects including tolerance loss, auto-antibody development and skin inflammation. For this reason, it is important to have antibody transfer-induced disease models for the investigation of the role of Tregs during IC-induced inflammation. Analyses of the skin and serum of regulatory T cell-depleted (DEREG) mice suggest that there are two different mechanisms that Tregs could utilize in influencing

IC-induced inflammation in the skin. The gene expressions of anti-inflammatory cytokines, including IL-10, IL-13, IL-4, and IL-10, as well as IFN γ (which is a pro-inflammatory cytokine) and T cell chemoattractant CXCL9, are increased in the skin. These data support the critical roles of IL-6-, IL-10-, and IL-4-positive $CD4^+$ T cells, which have been previously observed in an animal model study. These cells have also been suggested as being important contributors during allergic reactions and atopic dermatitis. The inhibition of Tregs is followed by the increase in the amount of the T cell chemoattractant CXCL9 in the skin, which suggests an increase in the number of neutrophils in the blood. In addition, cells that infiltrate into the inflamed skin may be associated with the impaired functions of Tregs. In the mouse model, the depletion of Tregs leads to an upregulation of anti-inflammatory gene expressions in the skin, such as the upregulation of IL-10 and other T_H2 -specific cytokines, including IL-13 and IL-4. In addition, this depletion also causes the upregulation of IFN γ , which is a T_H1 -related pro-inflammatory cytokine, and chemoattractant CXCL9 in the skin, as well as an increase in the serum level of IFN γ . All of these phenomena contribute to increasing the infiltration of neutrophils in the blood. Moreover, neutrophils can infiltrate the skin, probably through increases in CD18 cells. Tregs can directly interact with neutrophils and block CD18 expression in such cells, which explains the underlying mechanism of neutrophil infiltration that results from the depletion of Tregs. However, a higher concentration of T_H2 -related cytokines, which is a result of the depletion of Tregs, may be a rather ineffective counter mechanism. Figure 2 illustrates a probable mechanism of the actions of pro-inflammatory and anti-inflammatory cytokines, in relation to the regulation of neutrophils during the PDs, in the absence of Tregs.⁴⁹

Future perspective for treatment of OCP

An understanding of the mechanism of OCP not only delineates information about the mechanism and pathogenesis of PDs but also provides insights into ocular allergies or allergic conjunctivitis. Allergic conjunctivitis affecting the eye is very common; in general, this disorder consists of approximately 30% of the many allergic diseases in total. Allergies affect 15% of the world population, and approximately 30% of the US population and 40% of the EU population have some

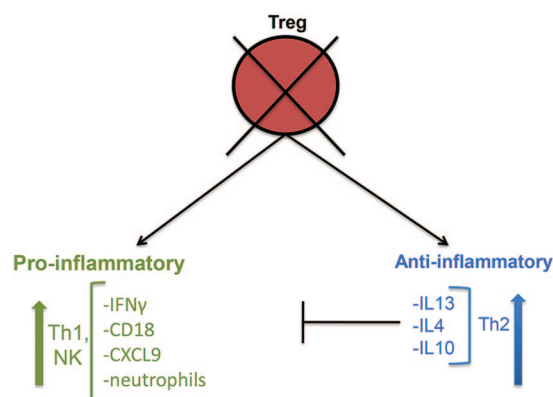


Figure 2. A schematic description of the role of Treg cells in a mouse model of OCP. The reduction of Tregs leads to a higher expression of pro-inflammatory molecules, which also leads to an increase in CD18 cells, followed by the infiltration of neutrophils. This infiltrated neutrophil population then leads to the pathogenesis of pemphigoid disease. OCP, ocular cicatricial pemphigoid.

type of allergy.⁷⁷ Until now, patients with an ocular allergy still suffer from a variety of diseases, as there is no targeted therapy for this condition. This review is an overview of the plausible understanding of the mechanism of OCP development and the immune cells that are associated with OCP. As a result of the publication of this article, it is hoped that several immune-mediated drugs that are able to target only the ocular surface can be generated. In addition, these drugs will be the perfect solution for other ocular surface inflammatory diseases.

Acknowledgements

T.B. acknowledges MOMENTE and SyNergy program LMU for their support.

Conflict of interest statement

The author declared no potential conflicts of interest with respect to the research, authorship, and/or publication of this article.

Ethical statement

An ethical statement is not required for the study, since there are neither any patient materials involved nor any studies relating to wet lab experiments being performed.

Funding

The author received no financial support for the research, authorship, and/or publication of this article.

ORCID iD

Tanima Bose  <https://orcid.org/0000-0003-1151-1140>

References

1. Chang JH and McCluskey PJ. Ocular cicatricial pemphigoid: manifestations and management. *Curr Allergy Asthma Rep* 2005; 5: 333–338.
2. Chan LS, Ahmed AR, Anhalt GJ, *et al.* The first international consensus on mucous membrane pemphigoid: definition, diagnostic criteria, pathogenic factors, medical treatment, and prognostic indicators. *Arch Dermatol* 2002; 138: 370–379.
3. Mondino BJ and Brown SI. Ocular cicatricial pemphigoid. *Ophthalmology* 1981; 88: 95–100.
4. Tauber J, Sainz de la, Maza M and Foster CS. Systemic chemotherapy for ocular cicatricial pemphigoid. *Cornea* 1991; 10: 185–195.
5. Foster CS. Cicatricial pemphigoid. *Trans Am Ophthalmol Soc* 1986; 84: 527–663.
6. Hardy KM, Perry HO, Pingree GC, *et al.* Benign mucous membrane pemphigoid. *Arch Dermatol* 1971; 104: 467–475.
7. Thorne JE, Anhalt GJ and Jabs DA. Mucous membrane pemphigoid and pseudopemphigoid. *Ophthalmology* 2004; 111: 45–52.
8. Tauber J, Jabbur N and Foster CS. Improved detection of disease progression in ocular cicatricial pemphigoid. *Cornea* 1992; 11: 446–451.
9. Elder MJ and Lightman S. The immunological features and pathophysiology of ocular cicatricial pemphigoid. *Eye (Lond)* 1994; 8: 196–199.
10. Bose T, Lee R, Hou A, *et al.* Tissue resident memory T cells in the human conjunctiva and immune signatures in human dry eye disease. *Sci Rep* 2017; 7: 45312.
11. Ahmed M, Zein G, Khawaja F, *et al.* Ocular cicatricial pemphigoid: pathogenesis, diagnosis and treatment. *Prog Retin Eye Res* 2004; 23: 579–592.
12. Martin LK, Werth VP, Villaneuva EV, *et al.* A systematic review of randomized controlled trials for pemphigus vulgaris and pemphigus foliaceus. *J Am Acad Dermatol* 2011; 64: 903–908.
13. Shimizu T, Takebayashi T, Sato Y, *et al.* Grading criteria for disease severity by pemphigus disease area index. *J Dermatol* 2014; 41: 969–973.
14. Murrell DF, Pena S, Joly P, *et al.* Diagnosis and management of pemphigus: recommendations

- by an International Panel of Experts. *J Am Acad Dermatol*. Epub ahead of print 10 February 2018. DOI: 10.1016/j.jaad.2018.02.021.
15. Groves RW. Pemphigus: a brief review. *Clin Med (Lond)* 2009; 9: 371–375.
 16. Beissert S, Mimouni D, Kanwar AJ, *et al*. Treating pemphigus vulgaris with prednisone and mycophenolate mofetil: a multicenter, randomized, placebo-controlled trial. *J Invest Dermatol* 2010; 130: 2041–2048.
 17. Joly P, Mouquet H, Roujeau JC, *et al*. A single cycle of rituximab for the treatment of severe pemphigus. *N Engl J Med* 2007; 357: 545–552.
 18. Joly P, Roujeau JC, Benichou J, *et al*. A comparison of two regimens of topical corticosteroids in the treatment of patients with bullous pemphigoid: a multicenter randomized study. *J Invest Dermatol* 2009; 129: 1681–1687.
 19. Martin LK, Werth V, Villanueva E, *et al*. Interventions for pemphigus vulgaris and pemphigus foliaceus. *Cochrane Database Syst Rev* 2009; 1: CD006263.
 20. Amagai M, Ikeda S, Shimizu H, *et al*. A randomized double-blind trial of intravenous immunoglobulin for pemphigus. *J Am Acad Dermatol* 2009; 60: 595–603.
 21. Hertl M, Jedlickova H, Karpati S, *et al*. Pemphigus. S2 guideline for diagnosis and treatment—guided by the European Dermatology Forum (EDF) in cooperation with the European Academy of Dermatology and Venereology (EADV). *J Eur Acad Dermatol Venereol* 2015; 29: 405–414.
 22. Schultz HY, Diaz LA, Sirois DA, *et al*. Generating consensus research goals and treatment strategies for pemphigus and pemphigoid: the 2010 JC Bystryn Pemphigus and Pemphigoid Meeting. *J Invest Dermatol* 2011; 131: 1395–1399.
 23. Kasperkiewicz M, Zillikens D and Schmidt E. Pemphigoid diseases: pathogenesis, diagnosis, and treatment. *Autoimmunity* 2012; 45: 55–70.
 24. Bertram F, Brocker EB, Zillikens D, *et al*. Prospective analysis of the incidence of autoimmune bullous disorders in Lower Franconia, Germany. *J Dtsch Dermatol Ges* 2009; 7: 434–440.
 25. Marazza G, Pham HC, Scharer L, *et al*. Incidence of bullous pemphigoid and pemphigus in Switzerland: a 2-year prospective study. *Br J Dermatol* 2009; 161: 861–868.
 26. Cozzani E, Parodi A, Rebora A, *et al*. Bullous pemphigoid in Liguria: a 2-year survey. *J Eur Acad Dermatol Venereol* 2001; 15: 317–319.
 27. Gudi VS, White MI, Cruickshank N, *et al*. Annual incidence and mortality of bullous pemphigoid in the Grampian Region of North-east Scotland. *Br J Dermatol* 2005; 153: 424–427.
 28. Serwin AB, Bokinić E, Piascik M, *et al*. Epidemiological and clinical analysis of pemphigoid patients in Northeastern Poland in 2000–2005. *Med Sci Monit* 2007; 13: CR360–CR364.
 29. Langan SM, Smeeth L, Hubbard R, *et al*. Bullous pemphigoid and pemphigus vulgaris—incidence and mortality in the UK: population based cohort study. *BMJ* 2008; 337: a180.
 30. Arafat SN, Suelves AM, Spurr-Michaud S, *et al*. Neutrophil collagenase, gelatinase, and myeloperoxidase in tears of patients with Stevens-Johnson syndrome and ocular cicatricial pemphigoid. *Ophthalmology* 2014; 121: 79–87.
 31. Dacosta J. Ocular cicatricial pemphigoid masquerading as chronic conjunctivitis: a case report. *Clin Ophthalmol* 2012; 6: 2093–2095.
 32. Xu HH, Werth VP, Parisi E, *et al*. Mucous membrane pemphigoid. *Dent Clin North Am* 2013; 57: 611–630.
 33. Ahmed AR, Foster S, Zaltas M, *et al*. Association of DQw7 (DQB1*0301) with ocular cicatricial pemphigoid. *Proc Natl Acad Sci U S A* 1991; 88: 11579–11582.
 34. Bhol KC, Dans MJ, Simmons RK, *et al*. The autoantibodies to alpha 6 beta 4 integrin of patients affected by ocular cicatricial pemphigoid recognize predominantly epitopes within the large cytoplasmic domain of human beta 4. *J Immunol* 2000; 165: 2824–2829.
 35. Kumari S, Bhol KC, Simmons RK, *et al*. Identification of ocular cicatricial pemphigoid antibody binding site(s) in human beta4 integrin. *Invest Ophthalmol Vis Sci* 2001; 42: 379–385.
 36. Tyagi S, Bhol K, Natarajan K, *et al*. Ocular cicatricial pemphigoid antigen: partial sequence and biochemical characterization. *Proc Natl Acad Sci U S A* 1996; 93: 14714–14719.
 37. Yunis JJ, Mobini N, Yunis EJ, *et al*. Common major histocompatibility complex class II markers in clinical variants of cicatricial pemphigoid. *Proc Natl Acad Sci U S A* 1994; 91: 7747–7751.
 38. Zakka LR, Reche P and Ahmed AR. Role of MHC Class II genes in the pathogenesis of pemphigoid. *Autoimmun Rev* 2011; 11: 40–47.
 39. Heiligenhaus A, Schaller J, Mauss S, *et al*. Eosinophil granule proteins expressed in ocular cicatricial pemphigoid. *Br J Ophthalmol* 1998; 82: 312–317.

40. Saw VP, Offiah I, Dart RJ, *et al.* Conjunctival interleukin-13 expression in mucous membrane pemphigoid and functional effects of interleukin-13 on conjunctival fibroblasts in vitro. *Am J Pathol* 2009; 175: 2406–2415.
41. Saw VP, Schmidt E, Offiah I, *et al.* Profibrotic phenotype of conjunctival fibroblasts from mucous membrane pemphigoid. *Am J Pathol* 2011; 178: 187–197.
42. Lambiase A, Micera A, Mantelli F, *et al.* T-helper 17 lymphocytes in ocular cicatricial pemphigoid. *Mol Vis* 2009; 15: 1449–1455.
43. Chan MF, Sack R, Quigley DA, *et al.* Membrane array analysis of tear proteins in ocular cicatricial pemphigoid. *Optom Vis Sci* 2011; 88: 1005–1009.
44. Creuzot-Garcher C, Xuan TH, Bron AM, *et al.* Blood group related antigens in ocular cicatricial pemphigoid. *Br J Ophthalmol* 2004; 88: 1247–1251.
45. Leyendeckers H, Voth E, Schicha H, *et al.* Frequent detection of thyroid peroxidase-specific IgG+ memory B cells in blood of patients with autoimmune thyroid disease. *Eur J Immunol* 2002; 32: 3126–3132.
46. Lin MS, Gharia MA, Swartz SJ, *et al.* Identification and characterization of epitopes recognized by T lymphocytes and autoantibodies from patients with herpes gestationis. *J Immunol* 1999; 162: 4991–4997.
47. Liu Z, Dang E, Li B, *et al.* Dysfunction of CD19(+)CD24(hi)CD27(+) B regulatory cells in patients with bullous pemphigoid. *Sci Rep* 2018; 8: 703.
48. Gerlicz-Kowalczyk ZA, Torzecka JD, Kot M, *et al.* Atypical clinical presentation of lichen planus bullous in a systemic sclerosis patient. *Postepy Dermatol Alergol* 2016; 33: 389–391.
49. Bieber K, Sun S, Witte M, *et al.* Regulatory T cells suppress inflammation and blistering in pemphigoid diseases. *Front Immunol* 2017; 8: 1628.
50. Rauz S, Maddison PG and Dart JK. Evaluation of mucous membrane pemphigoid with ocular involvement in young patients. *Ophthalmology* 2005; 112: 1268–1274.
51. Saw VP, Dart JK, Rauz S, *et al.* Immunosuppressive therapy for ocular mucous membrane pemphigoid strategies and outcomes. *Ophthalmology* 2008; 115: 253.e1–261.e1.
52. Williams GP, Radford C, Nightingale P, *et al.* Evaluation of early and late presentation of patients with ocular mucous membrane pemphigoid to two major tertiary referral hospitals in the United Kingdom. *Eye (Lond)* 2011; 25: 1207–1218.
53. Mondino BJ, Brown SI, Lempert S, *et al.* The acute manifestations of ocular cicatricial pemphigoid: diagnosis and treatment. *Ophthalmology* 1979; 86: 543–555.
54. Elder MJ, Bernauer W, Leonard J, *et al.* Progression of disease in ocular cicatricial pemphigoid. *Br J Ophthalmol* 1996; 80: 292–296.
55. Rice BA and Foster CS. Immunopathology of cicatricial pemphigoid affecting the conjunctiva. *Ophthalmology* 1990; 97: 1476–1483.
56. Bernauer W, Wright P, Dart JK, *et al.* The conjunctiva in acute and chronic mucous membrane pemphigoid. An immunohistochemical analysis. *Ophthalmology* 1993; 100: 339–346.
57. Afzali B, Lombardi G, Lechler RI, *et al.* The role of T helper 17 (Th17) and regulatory T cells (Treg) in human organ transplantation and autoimmune disease. *Clin Exp Immunol* 2007; 148: 32–46.
58. Blauvelt A. T-helper 17 cells in psoriatic plaques and additional genetic links between IL-23 and psoriasis. *J Invest Dermatol* 2008; 128: 1064–1067.
59. Chi W, Zhu X, Yang P, *et al.* Upregulated IL-23 and IL-17 in Behcet patients with active uveitis. *Invest Ophthalmol Vis Sci* 2008; 49: 3058–3064.
60. Furuzawa-Carballeda J, Vargas-Rojas MI and Cabral AR. Autoimmune inflammation from the Th17 perspective. *Autoimmun Rev* 2007; 6: 169–175.
61. Garrett-Sinha LA, John S and Gaffen SL. IL-17 and the Th17 lineage in systemic lupus erythematosus. *Curr Opin Rheumatol* 2008; 20: 519–525.
62. Korn T, Bettelli E, Oukka M, *et al.* IL-17 and Th17 Cells. *Annu Rev Immunol* 2009; 27: 485–517.
63. Mosmann TR and Sad S. The expanding universe of T-cell subsets: Th1, Th2 and more. *Immunol Today* 1996; 17: 138–146.
64. Ouyang W, Kolls JK and Zheng Y. The biological functions of T helper 17 cell effector cytokines in inflammation. *Immunity* 2008; 28: 454–467.
65. Elder MJ. The role of cytokines in chronic progressive conjunctival cicatrization. *Dev Ophthalmol* 1997; 28: 159–175.
66. Matsushima H and Takashima A. Bidirectional homing of Tregs between the skin and lymph nodes. *J Clin Invest* 2010; 120: 653–656.

67. Gratz IK and Campbell DJ. Organ-specific and memory treg cells: specificity, development, function, and maintenance. *Front Immunol* 2014; 5: 333.
68. Ludwig RJ, Vanhoorelbeke K, Leypoldt F, *et al.* Mechanisms of autoantibody-induced pathology. *Front Immunol* 2017; 8: 603.
69. Ludwig RJ. Clinical presentation, pathogenesis, diagnosis, and treatment of epidermolysis bullosa acquisita. *ISRN Dermatol* 2013; 2013: 812029.
70. Schmidt E and Zillikens D. Pemphigoid diseases. *Lancet* 2013; 381: 320–332.
71. Witte M, Koga H, Hashimoto T, *et al.* Discovering potential drug—targets for personalized treatment of autoimmune disorders—what we learn from epidermolysis bullosa acquisita. *Expert Opin Ther Targets* 2016; 20: 985–998.
72. Hirose M, Kasprick A, Beltsiou F, *et al.* Reduced skin blistering in experimental epidermolysis bullosa acquisita after anti-TNF treatment. *Mol Med* 2017; 22: 918–926.
73. Kasprick A, Yu X, Scholten J, *et al.* Conditional depletion of mast cells has no impact on the severity of experimental epidermolysis bullosa acquisita. *Eur J Immunol* 2015; 45: 1462–1470.
74. Bieber K, Witte M, Sun S, *et al.* T cells mediate autoantibody-induced cutaneous inflammation and blistering in epidermolysis bullosa acquisita. *Sci Rep* 2016; 6: 38357.
75. Antiga E, Quaglino P, Volpi W, *et al.* Regulatory T cells in skin lesions and blood of patients with bullous pemphigoid. *J Eur Acad Dermatol Venereol* 2014; 28: 222–230.
76. Arakawa M, Dainichi T, Ishii N, *et al.* Lesional Th17 cells and regulatory T cells in bullous pemphigoid. *Exp Dermatol* 2011; 20: 1022–1024.
77. Bielory L. Allergic and immunologic disorders of the eye. Part II: ocular allergy. *J Allergy Clin Immunol* 2000; 106: 1019–1032.

Visit SAGE journals online
[journals.sagepub.com/
home/oed](http://journals.sagepub.com/home/oed)

 SAGE journals