

ERECTILE DYSFUNCTION DUE TO ECTOPIC PENILE VEIN

CHRISTIAN G. STIEF, M.D.
HELMUT GALL, M.D.
WOLFGANG SCHERB, M.D.
WOLFGANG BÄHREN, M.D.

From the Departments of Urology, Dermatology, Neurology,
and Radiology, Bundeswehrkrankenhaus, Academic Hospital
of the University of Ulm, F.R. Germany

ABSTRACT—A total of 86/260 patients with erectile dysfunction had venous leakage as (joint) etiology. In 5 of 86 patients cavernosography showed pathologic cavernosal drainage only via an ectopic penile vein into the femoral vein. After ligation of this pathologic draining vessel, 4 of 5 patients regained spontaneous erectability. One patient with pathologic bulbocavernosus reflex latencies needed intracavernosal injection of vasoactive drugs for full rigidity.

An erection is hemodynamically based on dilatation of the arteries, relaxation of cavernosal sinusoids, and reduction of venous outflow.¹ In about 30 per cent of the patients with organic erectile dysfunction, venous leakage is the (joint) etiology.^{2,3} This pathologic drainage of the cavernous bodies is due to either a cavernous incompetence, i.e., a noncompression of small venules by insufficient relaxation of the cavernosal sinusoids,⁴ or to insufficient squeezing of the perforating veins within the tunica albuginea,⁵ or a combination of both.

We report on 5 patients with organic erectile dysfunction due to pathologic cavernosal drainage via a single ectopic penile vein into the femoral vein.⁶

Material and Methods

From February, 1985, to December, 1986, 260 consecutive patients with organic erectile dysfunction lasting at least one year were studied using multidisciplinary methods. The following examinations were performed: case history questionnaire, physical examination, testosterone and prolactin values, nocturnal penile tumescence (NPT) with a Jonas erec-

tiometer, sexual case history and psychometry, bulbocavernosus reflex (BCR), Doppler sonogram,^{7,8} and diagnostic intracavernous injection of a standardized vasoactive drug mixture.⁹ In 86 patients, dynamic cavernosography⁶ showed a venous leakage; in 5 patients the leakage was via a single ectopic penile vein to the femoral vein (Fig. 1). Control cavernosography of 10 patients with congenital penile deviation did not show such drainage.

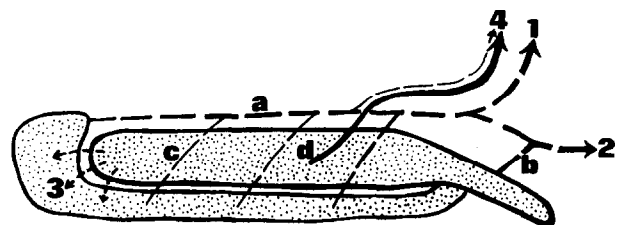


FIGURE 1. Schematic showing venous drainage of cavernous bodies: (a) v. dors. penis prof. plus vv. dors. penis sup., (b) vv. cavernosae, (c) vv. perforantes, (d) ectopic penile vein; (1) plex. vesiculoprostaticus, (2) vv. pudendae int., (3) shunts between c. cavernosum and glans/c. spongiosum, and (4) v. femoralis.

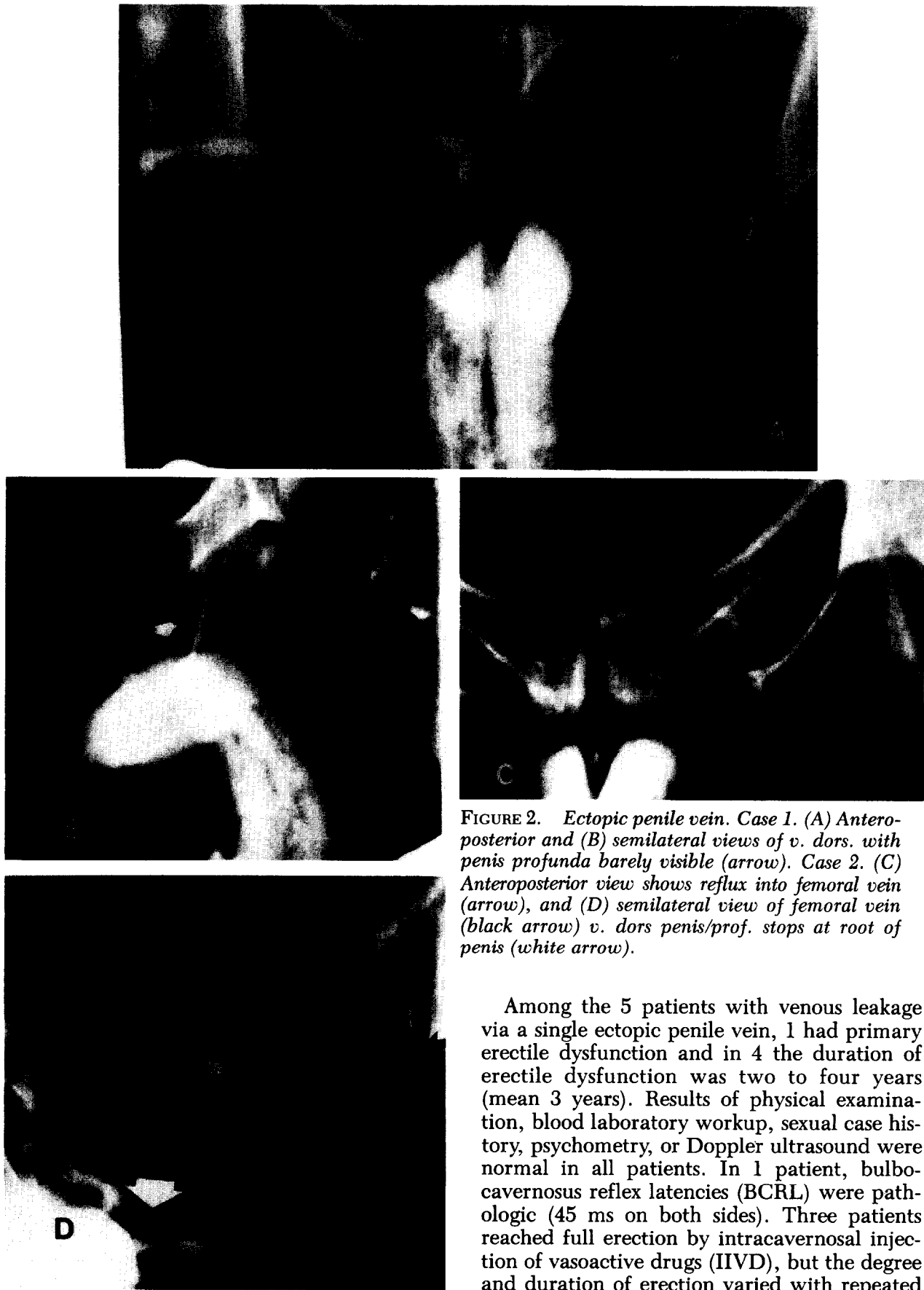
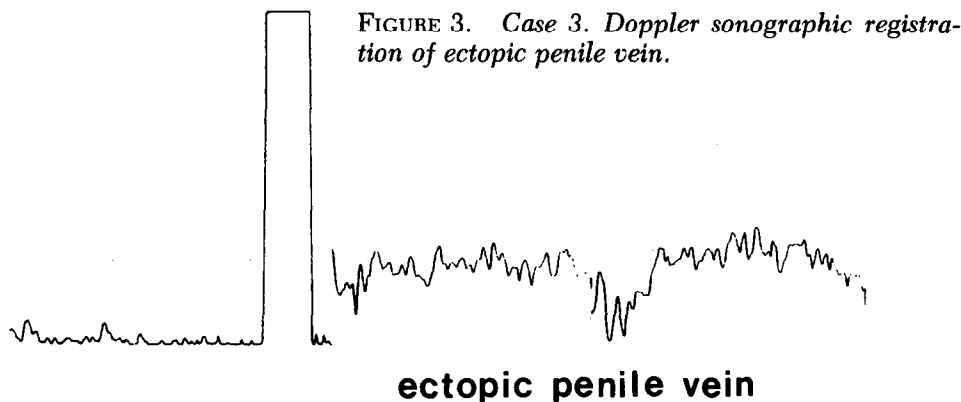


FIGURE 2. Ectopic penile vein. Case 1. (A) Anteroposterior and (B) semilateral views of v. dors. with penis profunda barely visible (arrow). Case 2. (C) Anteroposterior view shows reflux into femoral vein (arrow), and (D) semilateral view of femoral vein (black arrow) v. dors penis/prof. stops at root of penis (white arrow).

Among the 5 patients with venous leakage via a single ectopic penile vein, 1 had primary erectile dysfunction and in 4 the duration of erectile dysfunction was two to four years (mean 3 years). Results of physical examination, blood laboratory workup, sexual case history, psychometry, or Doppler ultrasound were normal in all patients. In 1 patient, bulbocavernosus reflex latencies (BCRL) were pathologic (45 ms on both sides). Three patients reached full erection by intracavernosal injection of vasoactive drugs (IIVD), but the degree and duration of erection varied with repeated

TABLE I. Findings of multidisciplinary approach

Case No.	Age (Yrs.)	Duration (Yrs.) of Erectile Dysfunction	Joint Etiology	Maintenance Flow
1	50	4	..	85
2	33	2	..	64
3	41	3	..	104
4	52	3	Neurogenic	60
5	21	Primary	..	50



injection of IIVD despite identical technique and doses. Two patients did not reach full erection with a maximal dose of 45 mg papaverine and 1.5 mg phentolamine, although tumescence over one hundred twenty minutes could be observed.

In a control group of 15 normal potent young men, all reached full erection of at least thirty minutes with 7.5 mg papaverine and 0.25 mg phentolamine injected intracavernously.⁸ As mentioned, cavernosography showed a pathologic drainage of the cavernous bodies via an ectopic vein in all patients (Fig. 2). The maintenance flow was in the upper tolerance with 50–104 mL/min (mean 69 mL/min).¹⁰ After intracavernosal injection of 7.5 mg papaverine and 0.25 mg phentolamine and ten minutes' delay, the maintenance flow was significantly pathologic with a mean of 51 mL/min (Table I).¹¹

To regain erectile potency, ligation of the ectopic vein was proposed. The patient with the pathologic BCRL was informed that return of erection could not be expected postoperatively.

Results

In 3 of 5 patients, Doppler sonographic location of the pathologic draining ectopic vein was possible after intracavernosal injection of 7.5 mg papaverine and 0.25 mg phentolamine (Fig.

3). After marking the course of the vein, local anesthesia was done at the root of the penis. Incision was made just above the marked course, and the vein was dissected, double ligated, and transected. In 2 of 5 patients, Doppler sonographic location was not possible, and conventional ligation of all dorsal penile veins was performed.

Six to eight months postoperatively, 4 of 5 patients and their sexual partners reported full return of erection. No venous outflow on the dorsum of the penis was detectable by Doppler sonography after IIVD. In spite of postoperative success and the aforementioned Doppler findings, 1 patient wanted another cavernosogram to ascertain that improvement in erectile function was not psychologic. Recavernosography showed no pathologic drainage of the cavernous bodies (Fig. 4).

The patient with pathologic bulbocavernosus reflex latencies reported a significant improvement of erectability, but he did not reach full rigidity. This patient was offered cavernosal auto-injection therapy. He now reaches full erections of eighty minutes with constant doses (3.75 mg papaverine plus 0.125 mg phentolamine).

Comment

Various authors have reported successful operations for impotence from increased

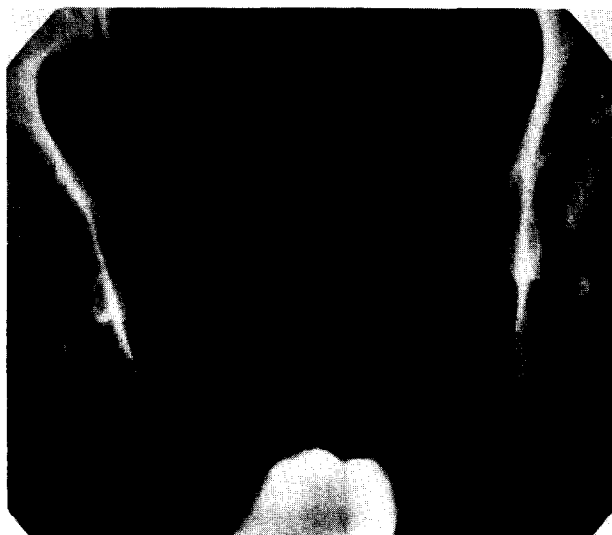

FIGURE 4. Case 1. Postoperative cavernosogram (AP) shows no pathologic cavernosal drainage; maintenance flow = 28 mL/min, after intracavernous injection of papaverine and phentolamine = 4 mL/min.

cavernosal outflow.^{2,10-12} Our patients represent a minority of the cases with venous leakage. This pathologic cavernosal outflow runs only via a single superficial vein. This relatively small vein can play a decisive role in preventing full rigidity as Wagner realized: "Any hydraulic equipment is highly sensitive to leakage."¹⁴ Because of the absence of complications and good postoperative results of this procedure, we recommend performing a cavernosogram not only in patients with negative response to IIVD, but also in those with irregular response. In case of pathologic cavernosal drainage via an ectopic penile vein, Doppler sonographic location and ligation under local anesthesia should be tried.

Department of Urology
U-518, Box 0738
University of California
San Francisco, California 94143
(DR. STIEF)

References

1. Lue TF, *et al*: Hemodynamics of canine corpora cavernosa during erection, *Urology* 24: 347 (1984).
2. Virag R, Spencer PR, and Fryman D: Artificial erection in diagnosis and treatment of impotence, *Urology* 24: 157 (1984).
3. Lewis RW, Puyan FA, and Bell DP: Another surgical approach for vasculogenic impotence, *J Urol* 136: 1210 (1986).
4. Juenemann KP, Lue TF, Fournier GR, and Tanagho EA: Hemodynamics of papaverine- and phentolamine-induced penile erection, *J Urol* 136: 158 (1986).
5. Lierse W: *Gefäß- und Nerven-anatomie des Penis*, Springer, Berlin, 1982.
6. Porst H, Altwein JE, Bach D, and Thon W: Dynamic cavernosography: venous outflow studies of cavernous bodies, *J Urol* 134: 276 (1985).
7. Jevtich MJ: Noninvasive vascular and neurogenic tests in use for evaluation of angiogenic impotence, *Inter Angio* 3: 225 (1984).
8. Gall H, Bähren W, and Stief CG: Diagnosis of vasculogenic impotence: comparing investigations by Doppler sonography and angiography, presented at Second World Meeting on Impotence, Prague, 1986.
9. Stief CG, *et al*: The meaningfulness of vasoactive drugs in the diagnosis of erectile dysfunction, presented at Second World Meeting on Impotence, Prague, 1986.
10. Delcour C, Wespes E, Schulman CC, and Struyven J: Investigation of the venous system in impotence of vascular origin, *Urol Radiol* 6: 190 (1984).
11. Wespes E, Delcour C, Struyven J, and Schulman CC: Pharmacocavernometry—cavernography in impotence, *Br J Urol* 58: 429 (1986).
12. Wooten JS: Ligation of the dorsal vein of the penis as a cure for atonic impotence, *Texas Med J* 18: 325 (1902).
13. Wespes E, and Schulman CC: Venous leakage: surgical treatment of a curable cause of impotence, *J Urol* 133: 796 (1985).
14. Ebbelhøg J, and Wagner G: Insufficient penile erection due to abnormal drainage of cavernous bodies, *Urology* 13: 507 (1979).