

ORIGINAL ARTICLE

Occurrence of tympanic bone spicules and bone crests in domestic cats

Tobias Beck  | Andreas Brüschwein | Andrea Meyer-Lindenberg

Clinic for Small Animal Surgery and Reproduction, Ludwig Maximilians University Munich, München, Germany

Correspondence

Andrea Meyer-Lindenberg, Clinic for Small Animal Surgery and Reproduction, Ludwig Maximilians University Munich, Veterinärstraße 13, 80539 München, Germany.
Email: ameylin@lmu.de

Present address

Tobias Beck, Wasenweg 3, Wolfratshausen, 82515, Germany

Abstract

Small and hyperostotic tympanic bone spicules (STBS and HTBS) extending from the tympanic wall or from the septum bullae into the tympanic cavity have been described in large feline species such as Siberian tigers or African lions and in canids such as dogs, red foxes and wolves. Detailed descriptions of prevalence, location and orientation were performed for dogs and African lions by means of necropsy and conventional computed tomography (cCT). Aims of the current study were to describe same characteristics for domestic cats by means of microcomputed tomography (μ CT) and cCT. A total of 15 cats or rather 30 ears were examined. Furthermore, new bone formations extending into the tympanic cavity shaped like small lamellae were found and named “tympanic bone crests” (TBCs). The registered phenomenon of a thickened tympanic wall in some cats was named “tympanic wall thickening” (TWT). STBS appeared in 43% of the ears being bilateral in 44% of the cases, whereas HTBS appeared in one ear. TBC was present in 33% of the ears with a bilateral prevalence of 67%, and TWT could be detected in 13% of the ears. The mentioned structures are just barely or not at all detectable with cCT; therefore, μ CT is necessary for an identification and detailed description. The origin and the factors inducing the development of examined phenomena are unknown, and it is hypothesized that the occurrence can be assessed as anatomical norm variations.

KEYWORDS

cat ear, microcomputed tomography-images, tympanic bone crest, tympanic bone spicule, tympanic wall thickening

1 | INTRODUCTION

Small tympanic bone spicules (STBS) and hyperostotic tympanic bone spicules (HTBS) are new bone formations extending from the mucoperiosteum into the cavity of the tympanic bulla (Parzefall et al., 2015). They have been mistakenly referred to as “otoliths” or “otolithiasis” in dogs (Drees, 2011; Farrow, 1992; Ziemer, Schwarz, & Sullivan, 2003), which are stone-like calcium carbonate concretions of necrotic material. STBS and the stalks of the HTBS whereas consist of osseous bone covered by a vascularized connective tissue

and a squamous or ciliated epithelium. STBS are maximal 1-mm-long needle-like structures with a pointed or clubbed tip with a diameter of <1 mm. If the extent increases, they are called HTBS or mucoperiosteal exostoses (MpEs), characterized as generally stalked, drumstick-like, smooth and globular bony structures (Novales et al., 2015; Parzefall et al., 2015). The “heads” had a diameter over 1 mm and consisted of normal lamellar bone tissue, sometimes with a medullary central channel, covered by the normal middle ear mucoperiosteum and a mostly flat, partially ciliated epithelium (Heitmann et al., 2016; Novales et al., 2015; Parzefall et al., 2015; Sula, Njaa, &

This is an open access article under the terms of the Creative Commons Attribution License, which permits use, distribution and reproduction in any medium, provided the original work is properly cited.

© 2019 The Authors. *Anatomia, Histologia, Embryologia* published by Blackwell Verlag GmbH

TABLE 1 Characteristics of all 15 cats that were used in the present study

| Age (years) | Sex | Breed | Body weight (kg) | Cause of euthanasia |
|-------------|-----|--------------------------|------------------|-------------------------------|
| 14 | ♀ | European Shorthair (ESH) | 4.2 | Liver tumour |
| 8 | ♂ | Bengal | 6.2 | Aortic thrombosis |
| 12 | ♂ | ESH | 3.8 | Kidney failure |
| 1,5 | ♂ | ESH | 3.7 | Clamped in bottom hung window |
| 11 | ♂ | ESH | 3.7 | Hypertrophic cardiomyopathy |
| 20 | ♂ | ESH | 2.0 | Kidney failure |
| 4 | ♂ | ESH | 4.0 | Car accident |
| 13 | ♂ | ESH | 3.4 | Hyperthyreosis |
| 14 | ♀ | ESH | 4.2 | Body weight loss |
| 18 | ♀ | ESH | 3.0 | Chronic renal insufficiency |
| 18 | ♂ | ESH | 3.3 | Hyperthyreosis |
| 14 | ♂ | ESH | 3.4 | Chronic renal insufficiency |
| 8 | ♂ | ESH | 4.1 | Intestinal tumour |
| 3 | ♂ | Maine Coon | 5.0 | Thorax effusion |
| 13 | ♀ | Maine Coon | 7.5 | Fibrosarcoma |

Payton, 2014). Just a few studies were performed evaluating the prevalence and the occurrence of these “otolith-like” bone structures. They could be detected in canids (e.g., dogs, wolves, foxes) and in large feline species (e.g., lion, tiger, leopard, cheetah). They could not be detected in primates, small carnivorous species (e.g., domestic cat, white breasted marten) and domestic or farm animals (e.g., horse, alpaca, goat, sheep, cattle, pig, rabbit, mouse, rat; Heitmann et al., 2016). A detailed description of HTBS is only present for dogs and African lions. Parzefall et al. (2015) examined 50 dogs within the scope of routine necropsy and another 144 skulls from a skull collection, and Novales et al. (2015) examined eight African lions.

The only difference between canids and large felids was the location of STBS and HTBS. In canids, they were mainly located at the free margin of the incomplete septum bullae and only a few at the ventrocaudal wall or the roof of the hypotympanic cavity (Parzefall et al., 2015), whereas in large felids they appeared mostly on the ventromedial aspect of the tympanic bulla wall and only a few in the epitympanic cavity (Novales et al., 2015). The (patho-) genesis of tympanic bone spicules (TBS) is still unknown, and different theories exist but they are just speculations. In African lions, the most probable cause was a response to a chronic injury as an otitis media (Novales et al., 2015), while in canids on the one hand mostly no

connection between an inflammatory process in the external ear canal or in the middle ear with the appearance of TBS could be detected whereby on the other hand an inflammation cannot be ruled out (Parzefall et al., 2015). Other hypotheses are “own independent functions, such as increasing the surface of the tympanic cavity or mediating the perception of low-frequency sounds via bone conduction into the inner ear” (Parzefall et al., 2015).

The mentioned studies detected and described TBS by means of radiographs, conventional computed tomography (CT), visual inspection and histology. In the present study, we use besides of CT additionally μ CT to describe the occurrence and the location of TBS in domestic cats for the first time in research. A comparison of CT and μ CT will show the differences between the two imaging methods in detecting and identifying inter-alia TBS. Additionally, special anatomical structures were analysed and described in detail such as new bony structures similar to lamellae extending into the hypotympanic cavity which are named tympanic bone crests (TBCs). Another part of the present study is the evaluation of the consistency of the thickness of the tympanic wall. Thicker wall parts were found, and this phenomenon was described as tympanic wall thickening (TWT).

2 | MATERIALS AND METHODS

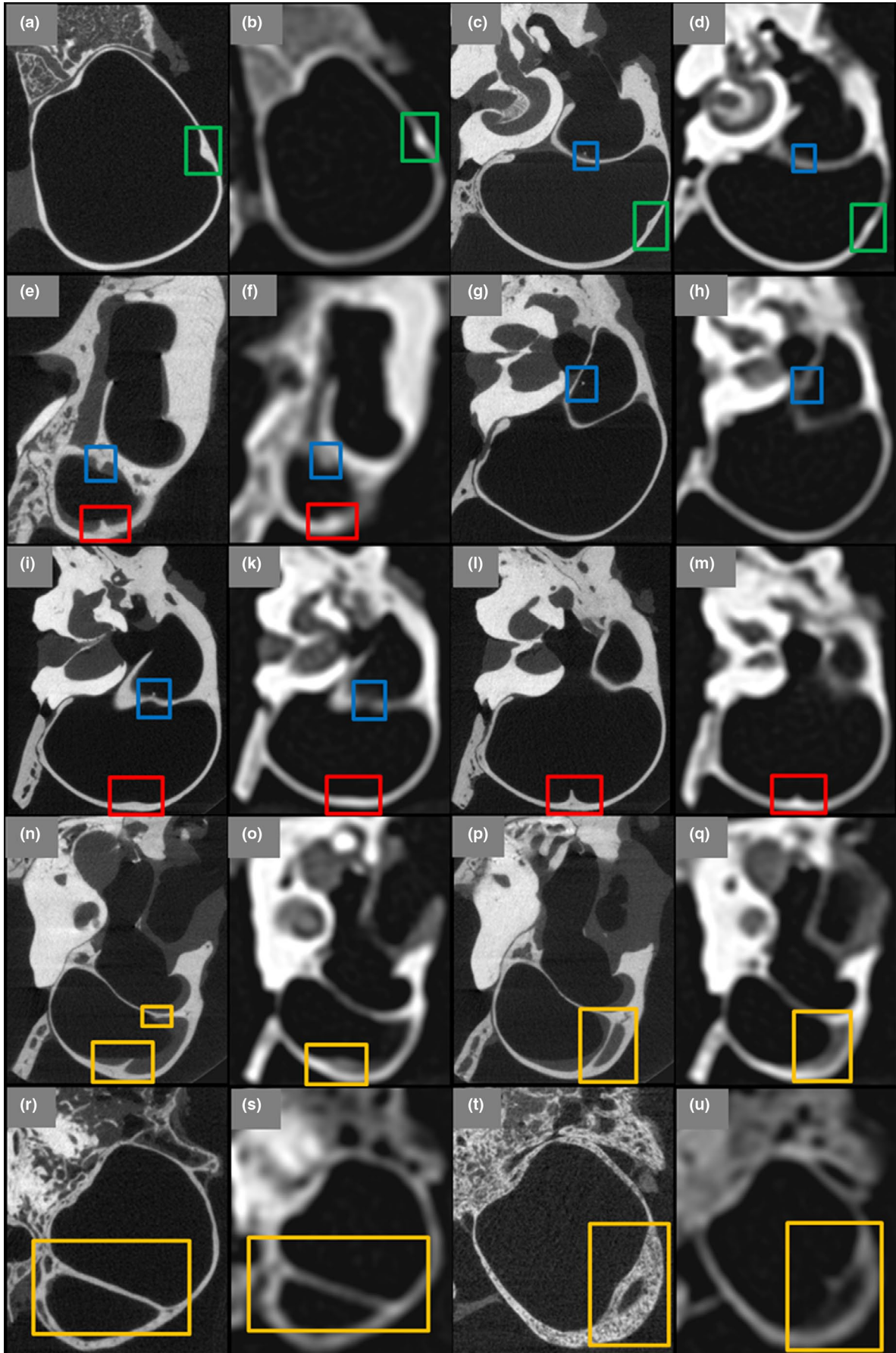
2.1 | Cat ears and preparation steps

Thirty fresh ears of 15 euthanized cats were used in the present study, and the characteristics of the cats are shown in Table 1. All cats were free from diseases of the head as could be confirmed with radiographs and conventional CT. Ears with fluid fillings were excluded from the study. The results of the present study are incidental findings of the unrelated study of Beck, Kilchling, and Meyer-Lindenberg (2019). The authors analysed differences between μ CT imaging and cCT for the diagnosis of possible diseases of the middle and inner ear of the cat. Consequently, the ear samples and the preparation steps of the present study are equal to the procedures performed by Beck et al. (2019).

2.2 | cCT investigations, μ CT investigations and positioning technique for the cCT and μ CT scans

Both investigation methods and the positioning technique comply with the procedures in the study of Beck et al. (2019). The utilized scan parameters in this study were the same as in the study of Beck et al. (2019) and as follows for conventional CT: spatial resolution of 330 μ m with special inner ear window, very sharp convolution kernel, 140 kV tube voltage, 275 effective mAs tube current and 600 μ m slice thickness. The variable scan parameters of the μ CT were chosen as follows: 30.3 μ m slice thickness, 1,250 projections per 180° and 300-ms integration time. Overall 30 cCT and μ CT scans were produced and evaluated.

FIGURE 1 Detected STBS extending from the tympanic wall (red squares) or from the septum bullae (blue squares). TWT is shown within the green and TBC within the yellow squares. The first and third row present μ CT images, and second and fourth row present equivalent cCT images



2.3 | Evaluation of cCT and μ CT scans

The evaluation of the cCT and μ CT scans occurred with the program RadiAnt DICOM Viewer 4.2.1 (64 bit version; Medixant). The images were taken with a screenshot tool (Greenshot). Multiplanar reconstructions (transversal, sagittal and coronal planes) were used for a better understanding of the course and the spatial extent of the analysed structures. The base of the images was always the transversal plane with the tympanic membrane orientated to the right and dorsal to the top independent of the ear side. In the sagittal plane, cranial was located to the left and dorsal to the top, and in the coronal plane, lateral was located to the right and cranial to the top.

The observers reviewed all μ CT scans searching for STBS or HTBS, TBC or TWT. If certain structures were found, the equivalent cCT scan was seen through as well and pictures of both imaging methods were taken and compared. Additionally, based on the μ CT scans, extent and location of mentioned formations were recorded.

3 | RESULTS

3.1 | Occurrence of STBS, HTBS, TBC and TWT

Figure 1 shows μ CT and cCT images of detected STBS, TBC and TWT. The detected HTBS is presented in Figure 2. cCT and μ CT images of the HTBS are compared with histological findings in Figure 3. A summary of the characteristics (inter-alia appearance, location and place of origin) of detected STBS, HTBS, TBC and TWT is presented in Table 2. Figure 2 The detected HTBS presented in a series of μ CT images (a–c) and cCT image (d). Presentation of the head (red arrow), the stalk (green arrow) and the base (yellow arrow)

TWTs were apparent in 13% of the ears (Figure 1a–d) being located mostly in the caudal third, and none was found in the cranial third. A thickness from 0.74 to 1.1 mm was measured. The TWTs could be detected in cCT images as well but they were less discrete and mainly evident due to focally increased density and not due to thickening of the wall (Figure 1d). The part of the tympanic wall that was dorsal in the image in relation to the location of the TWT appeared less dense in cCT images, whereas it was only

less thick in reality as could be shown by means of μ CT images (Figure 1c,d).

STBS were found in 13 ears of nine cats, four of them bilaterally. The number of STBS per affected ear was one to four or 1.7 in average (Figure 1c–m). Seventeen STBS extended from the tympanic wall into the hypotympanum (Figure 1e,f,l,m), and only five extended from the septum bullae into the dorsolateral compartment of the tympanic cavity (Figure 1c,d,g–k). The point of their origin was mainly ventromedial (17/22) independently of the bulla compartment that they were extending into. Nine STBS were located in the cranial as well as in the medial third, and only four appeared in the caudal third of the tympanic cavity. The length was measured from 0.5 to 2.8 mm with a stalk thickness from 0.1 to 0.4 mm. STBS were inconsistently detected with cCT, and only the larger STBS were identified (Figure 1c,d,g–k). Its identification as STBS was, nevertheless, hard to justify as their appearance in the cCT scans was very similar to the occurrence of TWT (Figure 1f,m). By means of μ CT scans, an identification of these hyperattenuating structures could be made without any concerns (Figure 1e,l); it was even possible to identify the smallest ones (Figure 1c,g,i).

TBC was found by means of μ CT in 10 ears of six cats, four of them bilaterally. In nine ears, only one TBC was present, whereas one ear had 3 TBCs (average number of 1.2 TBC per affected ear; Figure 1n–u). TBC was only apparent in the posterior two-thirds of the hypotympanic cavity. The length varied very much from 1.7 to 9.7 mm with a thickness of 0.2–0.6 mm. The height (longest distance extending into the tympanic cavity) ranged from 1.3 mm to 2.7 mm. By means of cCT, TBCs were best identifiable when having a high height (Figure 1s). Otherwise or when being surrounded by soft tissue, the TBCs could not be identified anymore as the cCT scans represented only the average density values of bone and soft tissue (Figure 1o,q). The TBC in Figure 1u was identifiable thanks to the comparison with the μ CT image. Without this comparison, the TBC itself was hard to identify as a bony structure because its density seems to be less than the comparable density of the tympanic wall. In a few cases, the TBCs were represented as TWT or as STBS in cCT images due to a low height and length.

A HTBS were present in only one ear (Figure 2). It was located in the middle third part of the hypotympanic cavity being ventromedial.

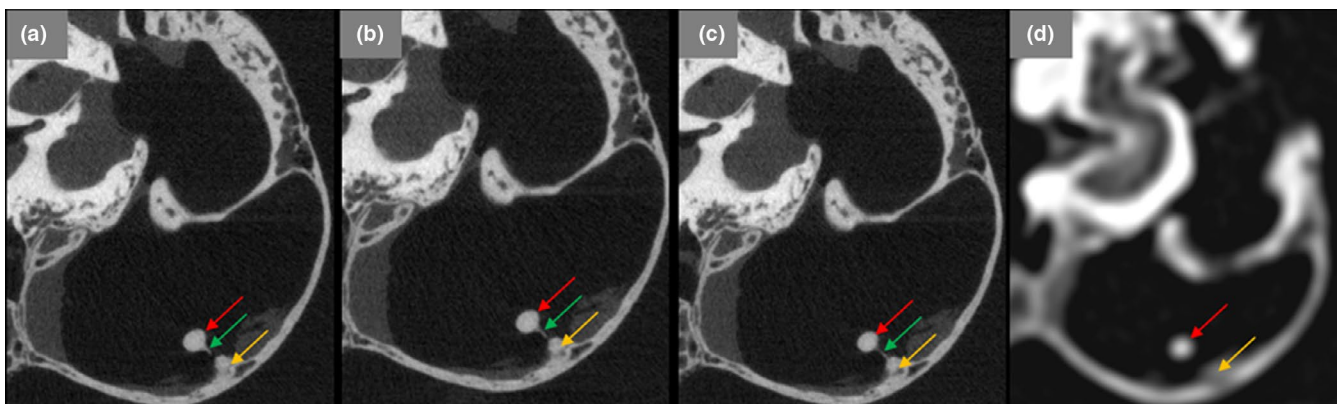


FIGURE 2 The detected HTBS presented in a series of μ CT images (a–c) and cCT image (d). Presentation of the head (red arrow), the stalk (green arrow) and the base (yellow arrow)

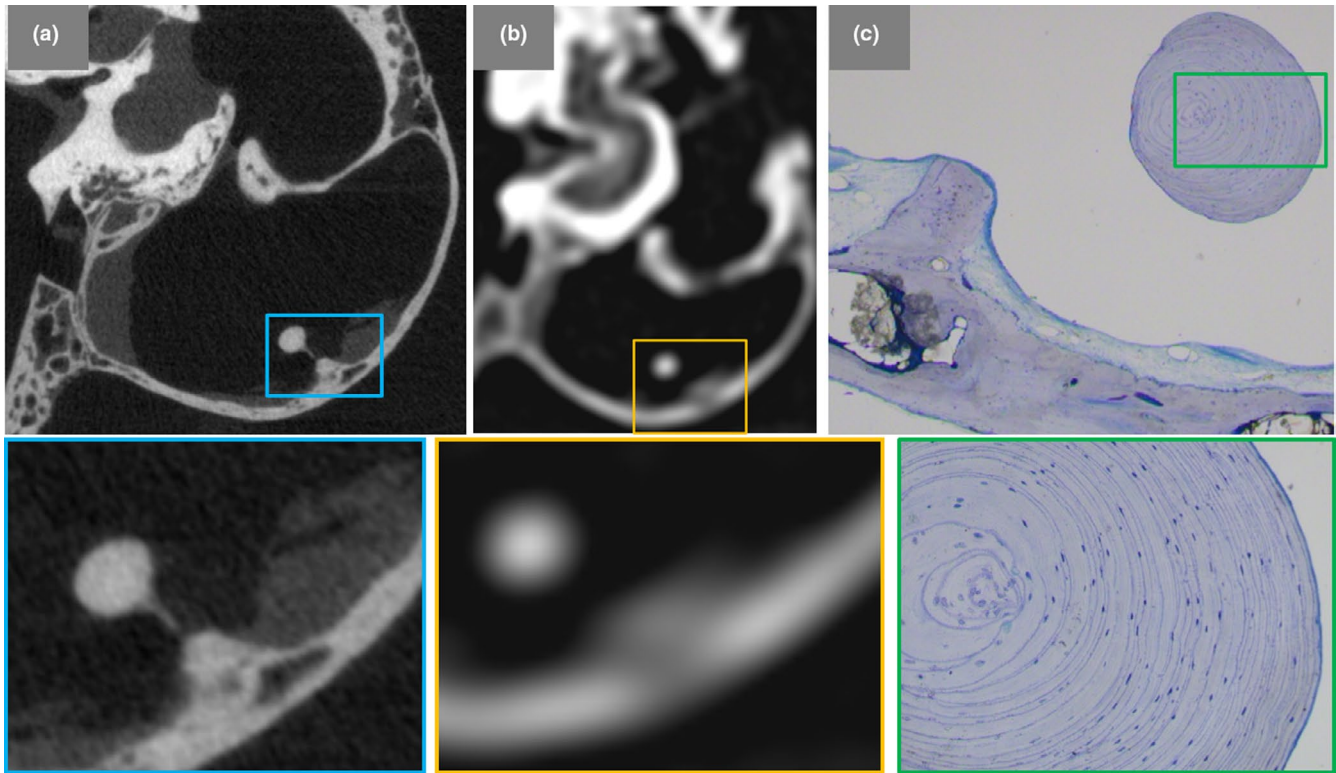


FIGURE 3 Comparison of μ CT image (a), cCT image (b) and histological slice (c) of the detected HTBS

Its stalk is 0.6 mm long and 60 μ m width extending from a 1 mm width and 0.6 mm thick base. The smooth globular swelling (“head”) at the top of the stalk had a diameter of 1.1 mm. Its identification was fairly difficult with cCT as the stalk is not represented, and the head seemed to float in the tympanic cavity (Figure 2d), whereas by means of μ CT the entire pathway and the total extent were clearly recognizable and measurable (Figure 2a–c).

4 | DISCUSSION

4.1 | Occurrence of STBS, HTBS, TBC and TWT

HTBS had been found in previous studies only in large felids (e.g., Siberian tigers or African lions) and canids (e.g., dogs, wolves or foxes; Heitmann et al., 2016; Novales et al., 2015; Parzefall et al.,

2015). The present study showed that STBS as well as HTBS occur in domestic cats even if the occurrence was less frequent compared with the other species. Furthermore, TWT and TBC could be detected in the middle ear of the cat. The formation process of all mentioned structures is unknown, and histological examination and the evaluation of cCT and μ CT did not show any signs of inflammatory alterations of the middle ear. The same could be said about STBS and HTBS; the origin and the developmental process remain unknown, corresponding to the results of Parzefall et al. (2015). In the present study, this is shown for the detected HTBS (Figure 3).

TWT as well as TBC mostly appeared in the caudal parts of the tympanic cavity/wall, and a correct identification was only given using μ CT. STBS and HTBS were mostly present on the ventromedial aspect of the tympanic wall, the same location as described for African lions by Novales et al. (2015). The same could be said for the

| | | STBS | HTBS | TBC | TWT |
|---------------------------|---------------|------------|-----------|------------|------------|
| Affected ears | | 43%, 13/30 | 13%, 1/30 | 33%, 10/30 | 13%, 4/30 |
| Totally found structures | | 22 | 1 | 12 | 4 |
| Bilaterally affected cats | | 4 out of 9 | — | 4 out of 6 | 1 out of 3 |
| Location | Cranial | 9 | 0 | 0 | 0 |
| | Centred | 9 | 1 | 4 | 1 |
| | Caudal | 4 | 0 | 8 | 3 |
| Place of origin | Septum bullae | 5 | 0 | — | — |
| | Tympanic wall | 17 | 1 | — | — |

TABLE 2 Summary of the results obtained for STBS, HTBS, TBC and TWT

Abbreviations: HTBS, hyperostotic tympanic bone spicules; STBS, small tympanic bone spicules; TBC, tympanic bone crest; TWT, tympanic wall thickening.

probability of bilateral TBS, which is similar for domestic cats (44%) and African lions (50%; Novales et al., 2015).

To measure the extent and to describe location and orientation of the structures, a fixed multiplanar reconstruction tool was used in the present study. The measured values were taken at the points with the highest and most realistic extensions, and consequently, the results can only be used as orientation values. More precise results could be obtained using a free MPR tool. By means of cCT, it was not possible to safely detect the found phenomena as its spatial resolution was too low to detect, for example the entire pathway of the stalks of S/HTBS. This might lead to misdiagnosis of otoliths with cCT. Therefore, the use of an in vivo μ CT with the advantage of a higher spatial resolution (Holdsworth & Thornton, 2002; Kalender, 2006) is necessary to detect mentioned structures. As all cats in the present study were free from diseases, it is not sure whether found anatomical norm variations are also visible in cats with present ear diseases such as otitis media or inflammatory polyps.

5 | CONCLUSIONS AND OUTLOOK

HTBS and STBS also exist in domestic cats but its occurrence is difficult to detect with the usually used in vivo imaging methods like cCT; the same can be said about TBC and TWT. All mentioned structures and phenomena are only safely detectable using μ CTs, which are not yet used for in vivo examinations of the cat although it would be possible. TBC, TWT, STBS and HTBS appear in middle ears without any signs for inflammatory alterations, and the development remains unknown. Consequently, it can be hypothesized that they constitute anatomical norm variations. Studies with sick cats should be performed to evaluate differences in healthy cats with regard to the detectability of mentioned anatomical norm variations.

ACKNOWLEDGEMENTS

Thanks go to the team in the laboratory in the area of research of the veterinary faculty of the Ludwig Maximilians University of Munich who supported and guided the author on how to operate with the in vivo μ CT and the machines to prepare the histological slices.

CONFLICT OF INTEREST

The authors declare that they have no conflict of interest. The authors alone are responsible for the content and writing of the manuscript.

AUTHOR CONTRIBUTIONS

T. Beck: involved in protocol and project development, data collection and management, data analysis, manuscript writing and editing. A. Brühshwein: collected and analysed the data and management. A. Meyer-Lindenberg: developed the project and wrote and edited the manuscript.

ETHICAL APPROVAL

With this statement, we declare that we did not obtain prior approval for the animal experiments from any animal experimentation ethics committee. All cats used in this study were already dead due to other reasons, and the responsible veterinarians had the permit from the previous owner to provide the dead cats for research. All applicable international, national and/or institutional guidelines for the care and use of animals were followed.

ORCID

Tobias Beck  <https://orcid.org/0000-0002-1214-5093>

REFERENCES

- Beck, T., Kilchling, T. P., & Meyer-Lindenberg, A. (2019). Differences between μ CT-imaging and conventional CT for the diagnosis of possible diseases of the middle and inner cat ear. *Anatomia, Histologia, Embryologia*, 48(3), 268–276.
- Drees, R. (2011). External, middle and inner ear. In T. Schwarz, J. Saunders (Eds.), *Veterinary computed tomography* (pp. 153–160). Hoboken, NJ: Wiley-Blackwell.
- Farrow, C. (1992). Known case conference. *Veterinary Radiology & Ultrasound*, 33, 262–263.
- Heitmann, A., Parzefall, B., Zollner, M., Bruhschwein, A., Hermanns, W., & Blutke, A. (2016). Hyperostotic tympanic bone spicules in domestic and wild animal species. *Veterinärni Medicina*, 61, 187–194. <https://doi.org/10.17221/8819-VETMED>
- Holdsworth, D. W., & Thornton, M. M. (2002). Micro-CT in small animal and specimen imaging. *Trends in Biotechnology*, 20, 34–39. [https://doi.org/10.1016/S0167-7799\(02\)02004-8](https://doi.org/10.1016/S0167-7799(02)02004-8)
- Kalender, W. (2006). Präklinische Bildgebung mit CT (Mikro-CT). In W. Kalender (Ed.), *Computertomographie* (pp. 237–245). Erlangen, Germany: Publicis Corporate Publishing.
- Novales, M., Ginel, P. J., Diz, A., Blanco, B., Zafra, R., Guerra, R., & Mozos, E. (2015). Mucoperiosteal exostoses in the tympanic bulla of African lions (*Panthera leo*). *Veterinary Pathology*, 52, 377–383.
- Parzefall, B., Rieger, A., Volk, H. A., Maierl, J., Brühshwein, A., & Blutke, A. (2015). Prevalence and characterization of small tympanic bone spicules and drumstick-like hyperostotic tympanic bone spicules in the middle ear cavity of dogs. *Veterinary Radiology & Ultrasound*, 56, 25–32. <https://doi.org/10.1111/vru.12197>
- Sula, M. M., Njaa, B. L., & Payton, M. E. (2014). Histologic characterization of the cat middle ear: In sickness and in health. *Veterinary Pathology*, 51, 951–967. <https://doi.org/10.1177/0300985813511125>
- Ziemer, L. S., Schwarz, T., & Sullivan, M. (2003). Otolithiasis in three dogs. *Veterinary Radiology & Ultrasound*, 44, 28–31. <https://doi.org/10.1111/j.1740-8261.2003.tb01444.x>

How to cite this article: Beck T, Brühshwein A, Meyer-Lindenberg A. Occurrence of tympanic bone spicules and bone crests in domestic cats. *Anat Histol Embryol*. 2020;49:216–221. <https://doi.org/10.1111/ah.12515>